Diplomarbeit

Diagnostics and possibilities of clinical management of residual placenta in cases with suspected arteriovenous malformation of the uterus or severe haemorrhage in the puerperium

eingereicht von

Sabine Enengl

geb. 06.10.1987

zur Erlangung des akademischen Grades

Doktorin der gesamten Heilkunde

(Dr. med. univ.)

an der

Medizinischen Universität Graz

ausgeführt an der

Universitätsklinik für Frauenheilkunde und Geburtshilfe

unter der Anleitung von

OA Dr. med. univ. Bence Csapo

Ao. Univ.- Prof. Dr. med. univ. Martin Häusler

Ort, Datum (Unterschrift)

Eidesstattliche Erklärung

Ich erkläre ehrenwörtlich, dass ich die vorliegende Arbeit selbstständig und ohne fremde Hilfe verfasst habe, andere als die angegebenen Quellen nicht verwendet habe und die den benutzten Quellen wörtlich oder inhaltlich entnommenen Stellen als solche kenntlich gemacht habe.

Graz, am …….. *Unterschrift ……*

Acknowledgement

First of all I would like to thank my supervisors OA Dr. med. univ. Bence Csapo and Ao. Univ.- Prof. Dr. med. univ. Martin Häusler from the Division of Obstetrics and Maternal Fetal Medicine at the Medical University of Graz for giving me the opportunity to write this thesis.
I would like to show my special gratitude to Dr. Csapo, who always had some useful advice and took his precious time to answer all of my questions. It really was a pleasure working at this department.

Thank you to all my friends and colleagues, who made the time of my studies a special chapter of my life that I will always like to think back to.
Thank you to my friend and colleague Dr. Herbert Stockinger, who awoke my interest for the subject of gynecology and obstetrics and always supported me to expand my knowledge.

Above all I would like to express my gratitude to my beloved parents Inge and Klaus, thank you for giving me the chance to study and find my own way! It makes me proud to have parents like you, who always stand right behind me and support me!

Table of contents

Abbreviations and their explanation

List of figures

List of tables

Summary

Abstract

1 Introduction 1

2 Theoretical examination 2

2.1 General information 2

2.1.1 Anatomy of the uterus 2

2.1.2 Vascular supply 4

2.1.3 The pregnant uterus 5

2.1.4 The placenta 6

2.1.4.1 Placentation 6

2.1.4.2 Fetal circulation 7

2.1.4.3 The placental stage 8

2.2 Special approach 9

2.2.1 Anomaly of placental separation 9

2.2.1.1 Management of residual placenta 11

2.2.1.1.1 Ultrasonography 11

2.2.1.1.2 Magnetic resonance imaging 13

2.2.1.1.3 Therapy of residual placenta 14

2.2.2 Arteriovenous malformation of the uterus 17

2.2.2.1 Definition 17

2.2.2.2 Subtypes 17

2.2.2.2.1 Congenital uterine AVMs 17

2.2.2.2.2 Acquired uterine AVMs 18
2.2.2.3 Epidemiology 18
2.2.2.4 Previous events 19
2.2.2.5 Symptoms 19
2.2.2.6 Diagnosis 20
2.2.2.6.1 Clinical examination 20
2.2.2.6.2 Ultrasonography 20
2.2.2.6.3 Hysteroscopy 23
2.2.2.6.4 Computed tomography angiogram 23
2.2.2.6.5 Magnetic resonance imaging 23
2.2.2.6.6 Pelvic angiography 24
2.2.2.7 Therapy 25
2.2.2.7.1 Acute measures 25
2.2.2.7.2 Hysterectomy 25
2.2.2.7.3 Transcatheter arterial embolisation 26
2.2.2.7.3.1 Complications 27
2.2.2.7.3.2 Post-procedure pregnancy 28
2.2.2.7.4 Ligation of feeding arteries 28
2.2.2.7.5 Medical treatment 29
2.2.3 Postpartum haemorrhage 30
3 Methods and Material 31
3.1 Patient population 31
3.2 Data acquisition 32
3.3 Analysis and statistical evaluation 34
4 Results 35
4.1 Maternal facts 35
4.2 Pregnancy and delivery 37

4.3 Placenta 40
4.4 Treatment 42
4.5 Haemorrhage 44
4.6 Postpartum anaemia 47
5 Discussion 52
6 References of the text 56

Abbreviations and their explanation

AVM	arteriovenous malformation
B-mode	brightness-mode
cm	centimetre/s
CT	computed tomography
DES	diethylstilboestrol
D&C	dilatation and curettage
g	gram/s
g/dl	gram/s per decilitre
GTD	gestational trophoblastic disease
Hb	haemoglobin
HSC	hysteroscopy
IUCD	intrauterine conceptive devices
i.v.	intravenous
LSC	laparoscopy
min	minute/s
ml	millilitre/s
mm	millimetre/s
MR-imaging	magnetic resonance imaging
m/s	metre/s per second
μm	micrometre/s
PI	pulsatility index
PPH	postpartum haemorrhage
PSV	peak systolic velocity
PVA	polyvinyl alcohol particles
RI	resistance index
RPOC	retained products of conception
TOP	termination of pregnancy
US	ultrasonography
USA	United States of America
WHO	World Health Organization
3D	3 dimensional

List of figures

Figure 1: General anatomy 3
Figure 2: Arteries of the female pelvis 4
Figure 3: Fetal Circulation 7
Figure 4: Echogenic mass in the uterine cavity 12
Figure 5: Heterogenous mass (arrow) in uterine cavity 13
Figure 6: Areas of enhancement (arrow) within mass, fluid (asterisk) matching PPH in upper vagina 14
Figure 7: Approach of residual placenta 15
Figure 8: Manual removal of residual placenta 16
Figure 9: Gray-scale image of the arteriovenous malformation with prominent cystic spaces within the myometrium 21
Figure 10: Longitudinal transvaginal ultrasound scan with colour Doppler demonstrating mixed arterial and venous flow in the body of the uterus posteriorly 22
Figure 11: Early phase angiogram showing filling of the uterine artery and the arteriovenous malformation 24
Figure 12: Gray-scale image of the arteriovenous malformation following selective embolisation 26
Figure 13: Detailed distribution of maternal age 35
Figure 14: Distribution of maternal age 36
Figure 15: Previous events 36
Figure 16: Distribution of gestational age 37
Figure 17: Distribution of deliveries before and after the completed 24th week 38
Figure 18: Distribution of mode of delivery in cases after the 24th week 38
Figure 19: Distribution of number of pregnancy 39
Figure 20: Distribution of parity 40
Figure 21: Type of placental anomaly 41
Figure 22: Further diagnosis documented in MEDOCS 41
Figure 23: Treatment of retained placenta 42
Figure 24: Distribution of dates of treatment 43
Figure 25: Weeks between delivery and treatment 44

Figure 26: Grade of postpartum haemorrhage 45
Figure 27: Management of severe haemorrhage 45
Figure 28: Treatment of severe haemorrhage 46
Figure 29: Distribution of postpartum haemoglobin 47
Figure 30: Postpartum Hb 48
Figure 31: Management of postpartum anaemia with Hb <10 g/dl 48
Figure 32: Management of postpartum anaemia with Hb <8 g/dl 49
Figure 33: Correlation of severe haemorrhage and anaemia <10 g/dl 50
Figure 34: Correlation of severe haemorrhage and anaemia <8 g/dl 50
Figure 35: Course of haemoglobin 51

List of tables

Table 1: Considered diagnosis and procedures 32
Table 2: Parameters of detailed analysis 33

Zusammenfassung

Hintergrund: In der Postpartal-Periode sind Blutungen ein großer Risikofaktor für Mutter und Kind. Die Kombination von Plazentaresten, operativen Eingriffen und arteriovenösen Fehlbildungen des Uterus (AVMs) könnte eine der Ursachen für starke postpartale Blutungen sein. Es gibt in der aktuellen Literatur wenige Berichte über uterine AVMs, die möglicherweise häufiger sind als angenommen.

Zielsetzung: Ziel dieser Studie war, mehr über die Prävalenz von AVMs in Fällen mit Plazentaresten und schweren postpartalen Blutungen oder Blutungen im Wochenbett herauszufinden. Den Patientinnen muss eine adäquate Behandlung geboten werden, um das Risiko für Komplikationen zu minimieren.

Methode: Anhand einer retrospektiven Studie wurden alle Fälle mit Plazentaresten an der Universitätsklinik für Frauenheilkunde und Geburtshilfe der Medizinischen Universität Graz von 2003-2011 analysiert. Besondere Aufmerksamkeit schenkte man Fällen mit schweren Blutungskomplikationen nach operativen Eingriffen wie Cürretage.

Ergebnisse: Die Ergebnisse zeigen, dass AVMs als Ursache für postpartale Blutungen eine spekulative Diagnose darstellen, da keine abnormalen Gefäßverbindungen in den analysierten Fällen nachgewiesen wurden. Jedoch präsentieren sich einige der Fälle mit einer Klinik, die zweifelsohne kompatibel mit AVMs ist, weshalb das Krankheitsbild ein möglicher Risikofaktor für postpartale Blutungskomplikationen bleibt. Vorhergehende Ereignisse, mütterliche Risikofaktoren und Möglichkeiten des Managements von Blutverlust konnten aufgezeigt werden und decken sich mit Ergebnissen der aktuellen Literatur.

Schlussfolgerung: Obwohl uterine AVMs eine Seltenheit zu sein scheinen und oft nicht primär diagnostiziert werden, muss man an die Komplikationen denken, die nach Plazentaresten und operativen Eingriffen auftreten können.

Schlagworte: Plazentareste, AVM, postpartale Blutung

Abstract

Background: In the postpartum period haemorrhage is one of the greatest risk factors for mother and child. The combination of residual placenta, which might require surgical intervention, and arteriovenous malformations (AVMs) of the uterus could be a main cause for severe haemorrhage postpartum. There are not many cases of uterine AVMs reported in literature, but it is possible, that this entity is more frequent than thought.

Objective: The aim of this study was to find out more about the prevalence of uterine AVMs in cases with residual placenta and severe haemorrhage postpartum or in the puerperium. It is important to offer an adequate treatment to the patients to minimise the risk of maternal or fetal complications.

Methods: A retrospective study has been carried out, investigating all cases of residual placenta at the Division of Obstetrics and Maternal Fetal Medicine at the Medical University of Graz from 2003-2011, with special attention for cases with severe bleeding complications after surgical interventions like dilatation & curettage (D&C).

Results: The results show that uterine AVMs as cause for postpartum haemorrhage seem to be a speculative diagnosis, as no abnormal vascular connections were proved in the analysed cases. Some of the cases however did show symptoms which are without doubt compatible with AVM, so it stays a possible risk factor for bleeding complications in the postpartum period. Previous events, maternal risk factors and options for the management of blood loss could be explored and seem to correspond with current literature.

Conclusion: Even though AVMs seem to be a rarity and often stay unobserved, it is important to be aware of the problem and the complications that might occur after residual placenta and surgical intervention.

Key words: residual placenta, AVM, postpartum haemorrhage

1 Introduction

A common complication during the postpartum period is residual placenta resulting in postpartum haemorrhage (PPH). Even in developed countries, PPH is one of the greatest risk factors for maternal morbidity and mortality during birth. A close examination during pregnancy and early diagnosis are essential for the individual management of our patients. The combination of residual placenta and an arteriovenous malformation (AVM) of the uterus could be a main cause for PPH.

AVM of the uterus seems to be a rarity. However it is necessary to take a closer look at this problem as there are not many cases reported and the consequences of AVMs can be very severe. Diagnostic methods have to be explored to learn more about its prevalence, development and different occurrences. It is really important to understand the risk of this entity in pregnant women as it could lead to severe bleeding or even to maternal mortality if undiagnosed. As AVM of the uterus could be a more frequent problem than thought, adequate clinical management is imperative for a possible prevention or optimal management of postpartum complications found in these cases.

This retrospective study aims to analyse cases of residual placenta with postpartum haemorrhage and their clinical management at the Division of Obstetrics and Maternal Fetal Medicine at the Medical University of Graz. The clinical question was, how often AVMs could have been the cause of PPH. It was also assessed what the management was and discussed what measures would be necessary to reduce severe complications and maternal death.

2 Theoretical examination

2.1 General information

2.1.1 Anatomy of the uterus

The uterus is situated between the bladder and the rectum mostly in the antero-posterior midline of the female pelvis, held in this position by the round and broad ligaments on each side (*ligamentum teres uteri and ligamentum latum*). The broad ligaments connect the uterus with the tubes and ovaries (1).

The shape of the uterus represents a pear turned upside down within which four different parts are distinguished. The upper extremity called *fundus* is located above the area where the two fallopian tubes commence into the uterine cavity linking it to the ovary. The *corpus*, somewhat flattened in the sagittal plane, forms the main part of the organ connecting the lower part (*isthmus*) and the *fundus*. It is leaning forwards and upwards, narrowing from top to bottom. The anterior surface of the uterus faces the bladder (*facies vesicalis*) and its posterior surface faces the intestines (*facies intestinalis*). The *isthmus* of the uterus forms the connection between *corpus* and *cervix*. It is not longer than 1 cm but during pregnancy it unfolds and is called the lower uterine segment. The *cervix's* shape reminds of a cylinder measuring about 3 cm. Its lower extremity is attached to the *vagina*, consisting of an anterior and a posterior lip shaping an aperture called uterine orifice (*ostium uteri*). The uterine cavity is triangular flattened in an anterior-posterior direction with the orifice of the tubes on top and it narrowing into the *isthmus* below called canal of the isthmus followed by the canal of the cervix (1; 2; 3).

The longitudinal axis of the uterus is normally bending forwards in the area of the *isthmus*, which leads to a flexure towards the bladder (*anteflexio uteri*) forming an angle of 100-170 degrees. Similar to the axis of the uterus, the axis of the cervix

also shows a bend towards the anterior abdominal wall, which results in the effect that the uterus seems to be laid over the bladder (*anteversio uteri*). Of course the position of the uterus varies with the filling of the bladder and of the rectum (1; 2).

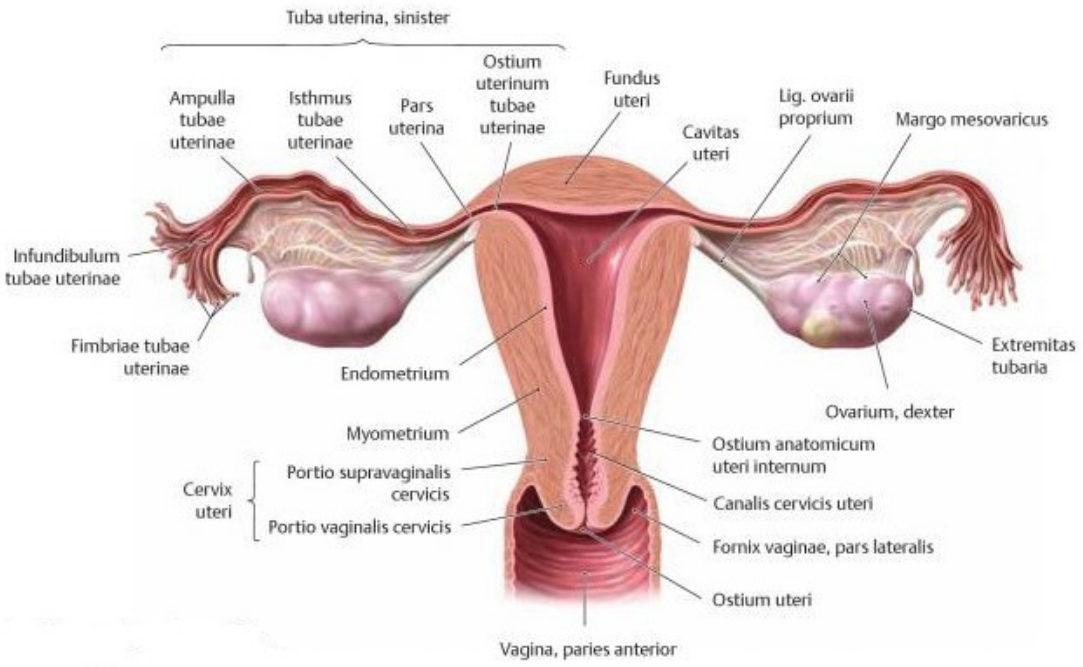

Figure 1: General anatomy

Data from Gilroy AM, MacPherson BR, Ross LM. Atlas of Anatomy. New York: Thieme Medical Publishers, Inc; 2008. p. 189.

Concerning the structure of the uterine wall we differentiate three layers. It normally shows an average thickness of about 1-2 cm and consists of a mucous layer towards the cavum called *endometrium*, a muscular layer in the middle called *myometrium* and the external serous layer called *perimetrium*. The *endometrium* plays a dominant role in the process of placentation. The *myometrium* also undergoes several changes during pregnancy. The *perimetrium* is derived from the peritoneum forming the external coat of the organ (1; 2; 3).

2.1.2 Vascular supply

The main artery of the uterus is the uterine artery running on each side from the *cervix-corpus* margin both towards the *fundus* and the *vagina*. The uterine artery runs downwards from the internal iliac artery towards the *cervix* in the broad ligaments going along with the *ureter* at first. At this point the vaginal artery is formed. It then goes upwards along the lateral border of the uterus in the direction of the tubes. Along its route it gives off the main vessels for the uterine supply. Furthermore it also supplies the tubes and ovaries through little branches (1; 2; 3). The uterine arteries follow a tortuous course in the substance of the uterus and are also very likely to build anastomoses (3).

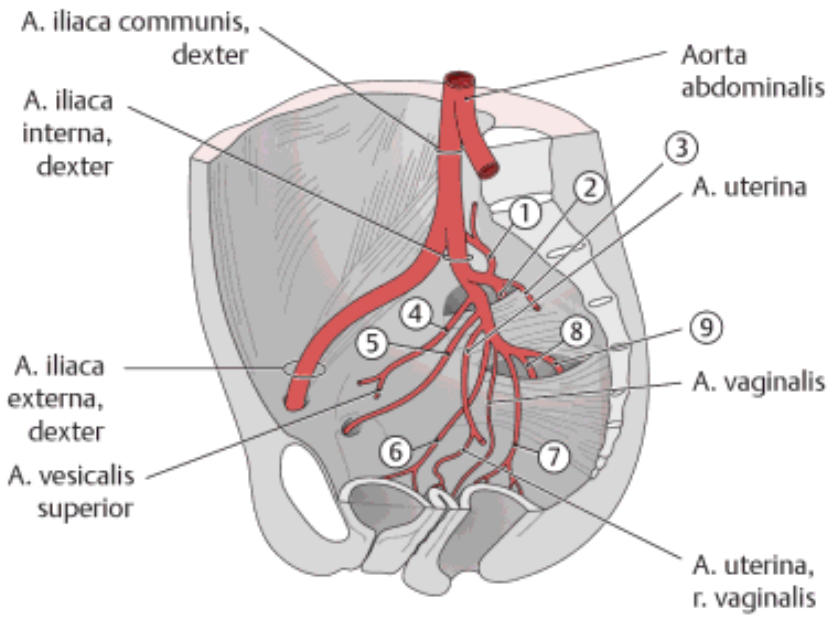

Figure 2: Arteries of the female pelvis

Data from Gilroy AM, MacPherson BR, Ross LM. Atlas of Anatomy. New York: Thieme Medical Publishers, Inc; 2008. p. 222.

Along the lateral borders of the uterus we find a large venous plexus. There are two veins on each side, the uterine veins, which are remarkable for their large size. The plexus is connected with the venous plexus of the *vagina*. Most of the

blood drains off into the internal iliac veins. Veins that take their course near the *fundus*, end in the ovarian veins (1; 2; 3).

2.1.3 The pregnant uterus

During pregnancy the female sexual organs undergo several significant changes. The uterus (primarily the *endometrium*) plays a decisive role in building the placenta. Furthermore the *myometrium* enlarges, gaining about ten times in weight, measuring about 1 kg towards the end of pregnancy. This change is characterised by both the processes of hypertrophy and hyperplasia. The *perimetrium* adapts to these changes. At first the part of the uterus where the ovum is embedded proliferates. Then the rest of the organ adapts which consequently leads to the uterus becoming globe-shaped by the end of the first trimester. At this time the *isthmus* forms the lower uterine segment. The uterus gradually fills out the whole small pelvis as most of the intestinal loops are displaced. The organ erects and at the end of the sixth month the *fundus* reaches the level of the navel. In the ninth month it's even higher, reaching well into the *epigastrium*. At the end of pregnancy the uterus tends to sit lower in the pelvis. During pregnancy the inner female sexual organs are particularly well supplied with blood. The uterine arteries enlarge but even more do the veins. The uterine arteries build up several anastomoses to drain off blood from the ovarian arteries through several little branches to provide adequate blood supply. The mucous layer of the uterus also becomes rich in vessels. Because of the dilatation of the vessels from a calibre of 2-3 mm to 5-6 mm the gravid uterus is practically flooded with blood, this being a prerequisite for a good placentation process (1; 2; 3).

2.1.4 The placenta

2.1.4.1 Placentation

Placentation starts around the 7th-12th day after fertilisation with the nidation of the ovum into the *endometrium*, now called *decidua*. The ovum is built of two layers. The central cell mass is called *embryoblast* from which the embryo will be developing later on. The external cell layer is called *trophoblast* and will form the placenta. The trophoblasts embed into the *decidua*, which is now divided into three different parts:

- *Decidua basalis*: separating the ovum from the *myometrium*
- *Decidua capsularis*: covering the embedded ovum
- *Decidua parietalis*: covering the uterine cavity

After the implantation the *trophoblast* builds a single layer of cells into the *decidua*, which is called *cytotrophoblast* and about a week later these cells begin to fuse, forming a multilayer called *syncytiotrophoblast*. This cell mass makes up the fetal part of the placenta, whereas the *decidua* constitutes the maternal part. From the 9th day on several lacunas develop within the layer of *syncytiotrophoblast*. The further invasion of the *trophoblast* into the *decidua* leads to arrosion of enlarged maternal blood vessels and more and more blood streams into the lacunas. Due to proliferation of the *cytotrophoblast* the development of *primary villi* commences. After the incorporation of embryonal connective tissue and fetal vessels they are called *secondary or tertiary villi* in which approximately around the 21st day the fetal circulation begins. Multiple *septa* divide the placenta into different lobes called *cotyledons*. On the due date the diameter of the placenta measures about 20 cm, the thickness about 2-4 cm. The weight is about 500 g (2; 4).

2.1.4.2 Fetal circulation

As the lungs of a fetus aren't able to fulfill the gas exchange that is necessary for the oxygenation of blood, the placenta takes over this job during pregnancy. The fetus is connected to the placenta by the umbilical cord which contains a single umbilical vein and two umbilical arteries (5; 6).

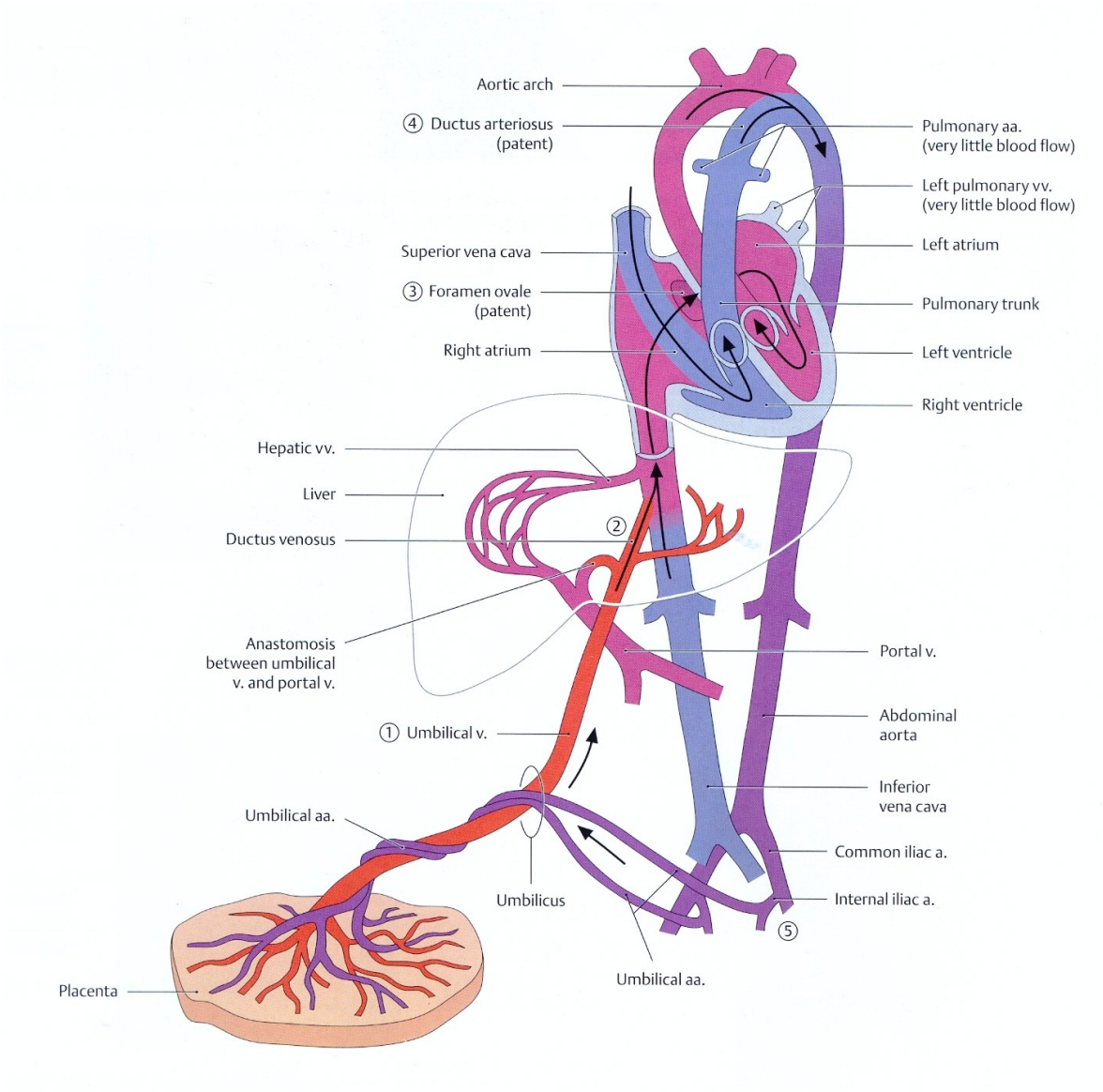

Figure 3: Fetal Circulation

Data from Gilroy AM, MacPherson BR, Ross LM. Atlas of Anatomy. New York: Thieme Medical Publishers, Inc; 2008. p. 94.

The oxygenated blood from the placenta passes through the umbilical vein of the fetus. Via the *Ductus venosus* a significant part of the blood enters the inferior vena cava bypassing the liver. The rest of the blood leads into the portal vein and passes the liver. In the inferior vena cava the oxygen-rich blood of the placenta mixes with oxygen-poor blood from the fetus. Both the superior and inferior vena cava enter the right atrium (5; 6).
Most of the blood from the inferior vena cava moves to the left atrium via the *Foramen ovale*, thereby building a right-to-left-shunt. The mixed blood passes the left ventricle and leaves through the aorta giving nutrients to the *Truncus brachiocephalicus*, the left carotid and subclavian arteries. Deoxygenated blood from the superior vena cava goes from the right atrium to the right ventricle into the *Truncus pulmonalis*, which is connected to the aorta by another right-to-left-shunt, the *Ductus arteriosus Botalli* (5; 6).
The partially oxygenated blood in the aorta supplies the fetal vessels and finally enters the two umbilical arteries, which are branches of the internal iliac arteries, and goes back to the placenta to be oxygenated again (5; 6).

2.1.4.3 The placental stage

The placental stage is the period after the birth of the child until the delivery of the placenta and fetal membranes. This normally takes about ten to twenty minutes. Due to a release of prostaglandins by the placenta itself, the uterus tends to contract and shortens to a length of about 15 cm. This leads to a size reduction of the surface, where the placenta is still attached to the uterus. In 75% the process of detaching starts in the centre of the placenta. This mechanism is named after *Schulze*. In the remaining 25% the separation of the placenta starts along its border, named the method of *Duncan*. The advantage of *Schulze's* method is the loss of a smaller amount of blood (2; 4).

There are clinical signs of placental detachment (4; 7):

- Sign of *Schröder*: the *fundus* retracts and rises above the detached placenta

- Sign of *Küstner*: pushing on the abdominal wall between symphysis and navel leads to a retraction of the umbilical cord into the vagina if the placenta hasn't detached yet
- Sign of *Ahlfeld*: during the course of ablation a clamp attached to the umbilical cord moves caudally

The maternal and fetal parts of the placenta are delivered together. The dividing line takes its course in the layer of the *decidua basalis*. The fetal membranes consisting of *decidua capsularis and parietalis* are connected to the placenta. After the detachment of the placenta it is very important to examine its surface to make sure that there are no residuals left. Residual placenta means danger to life as it might lead to severe haemorrhage, infection or trophoblastic tumour (8). The blood loss during placental stage normally measures about 300 ml. Due to strong uterine contractions and afterpains followed by *lochia* during childbed (puerperium) the wound of the uterine mucous membrane is epithelialised approximately within ten days (2; 4).

2.2 Special approach

2.2.1 Anomaly of placental separation

We talk about an anomaly of placental separation in the following three conditions: if the placenta hasn't detached within thirty minutes after delivery and/or if the blood loss measures more than an estimated 300 ml and/or if the placenta hasn't been delivered completely and a residual placenta is assumed (4). This happens in about 1% of pregnancies, more likely after termination of pregnancy (TOP) than after vaginal or caesarean delivery (9). Residual placenta even of very small size always means danger to life, so a thorough inspection for defects of the placenta after its delivery is imperative. Residual placenta might lead to immediate bleeding, haemorrhage, infection or even sepsis during childbed, and could be the cause for trophoblastic tumour (8).

We distinguish between functional and anatomical reasons for the retention of parts of the placenta (4; 7):

- functional
  - Adherent placenta (*Placenta adhaerens*): an anomaly of placental separation caused by bradytocia
  - Incarcerate placenta (*Placenta incarcerate*): the placenta is detached but retained by a spasm of the *cervix*

- anatomical
  - Accrete placenta (*Placenta accreta*): the *decidua* is missing so the *villi* reach up to the *myometrium*
  - Increte placenta (*Placenta increta*): *villi* reach into the *myometrium*
  - Percrete placenta (*Placenta percreta*): *villi* reach through the *myometrium* into the *perimetrium* or even invade surrounding organs like the urinary bladder

In cases of *placenta adhaerens* the placenta is not separating totally, in cases of anatomical reason it's not separating at all, however the anatomical cause behind the failure of separation may not affect the whole of the placenta equally. In pregnancy the uterine blood flow is highly increased. During the course of placental ablation the maternal vessels are opened up but tend to get closed soon after delivery of the placenta due to strong uterine contractions. A failure or arrest of complete placental detachment leads to a delay in the haemostiptic effect of the uterine contractions, which in turn leads to considerable amounts of blood loss. In cases of accrete, increte and percrete placentas the affected part of the placenta can't be detached at all, so initially there may be no haemorrhage at all. The diagnostic is based on missing clinical signs of placental detachment within thirty minutes postpartum (4; 7).

2.2.1.1 Management of residual placenta

As residual placenta might lead to severe immediate or delayed postpartum haemorrhage an early diagnosis is essential. It has been shown to be linked with subsequent bleeding complications, hysterectomy and longer maternal hospital stays (10). At first it is necessary to keep patients' histories in mind. Previous uterine surgeries like caesarean section or fibrome enucleations, previous D&C (dilatation and evacuation or curettage), trauma, infection, *placenta praevia*, *Asherman's* Syndrome, presence of submucous leiomyomata and advanced maternal age are the main risk factors for retained products of conception (RPOC) (11; 12). The next step would be to check for possible anatomical reasons predisposing for a retained placenta already during pregnancy. So, in case of *placenta accreta, increta or percreta* the delivery can be planned in a clinic with special service for perinatology, anaesthesia, diagnostic and invasive radiology, haematology and blood transfusions (12). In case of PPH (both primary and secondary) it is important to find out if there is truly residual placental tissue, as this would be the only indication for a curettage, which can be traumatising during the puerperium (13).

2.2.1.1.1 Ultrasonography

During pregnancy several ultrasonographic tests are carried out. It is necessary to turn one's attention to the placenta during this examination. There are several signs in normal gray-scale ultrasonography (US), which might be a sign for *placenta accreta, percreta or increta* (12):

- Placental *lacunae*
- Obliteration of clear space
- Interruption of bladder border
- *Myometrium* of less than 1 mm

Figure 4: Echogenic mass in the uterine cavity

Data from Mulic-Lutvica A, Axelsson O. Ultrasound finding of an echogenic mass in women with secondary postpartum hemorrhage is associated with retained placental tissue. Ultrasound Obstet Gynecol. 2006 Sept;28(3):312-9.

In Colour-Doppler US the examiner should look for turbulent blood flow from the placenta to surrounding tissues (12).

US can also be a useful tool to find out if RPOC is the cause for PPH after delivery of the child. However ultrasound is not always accurate. Mulic-Lutvica et al. carried out a prospective observational study to gather morphological findings corresponding to residual placenta (13). 17 of 18 patients with secondary PPH showed an echogenic mass in their uterine cavity and in 14 of these 17 cases the presence of placental tissue was histologically confirmed. Patients with an uneventful puerperium demonstrated either a mixed-echo pattern or a minor amount of fluid in their uterine cavity, so it was concluded, that this would be the common sign of the involuting uterus.

Even though the precision of US seems to vary, it is by all means a valid tool to confirm an empty uterine cavity, if RPOC should not be the cause of PPH (13).

Furthermore it is also recommended to perform an US after uterine evacuation for TOP, which leads to residual placenta in 1-3% (14). An endometrial thickness of ≥ 8 mm measured by US after TOP should lead to further investigation and eventually re-evacuation (14).

2.2.1.1.2 Magnetic resonance imaging

Magnetic resonance imaging (MR-imaging) as diagnostic tool for residual placenta has not been the subject of many studies so far. Noonan et al. had the idea to distinguish between residual placenta and gestational trophoblastic disease (GTD), since both present with similar symptoms (9).

The results showed that MR-imaging demonstrated remnants of placenta as soft-tissue mass in the uterine cavity. The *T1* and *T2* signal intensities varied and so did the amount of enhancing tissue. The degrees of myometrial thinning and obliteration of the junctional zone also diversified. In addition to that, the results for residual placenta and GTD partially overlapped. So MR-imaging is obviously not the ideal tool to distinguish GTD from retained placenta, but it could be helpful to look for anatomic variants like AVM, which could lead to complications during instrumentation of the uterine cavity (9).

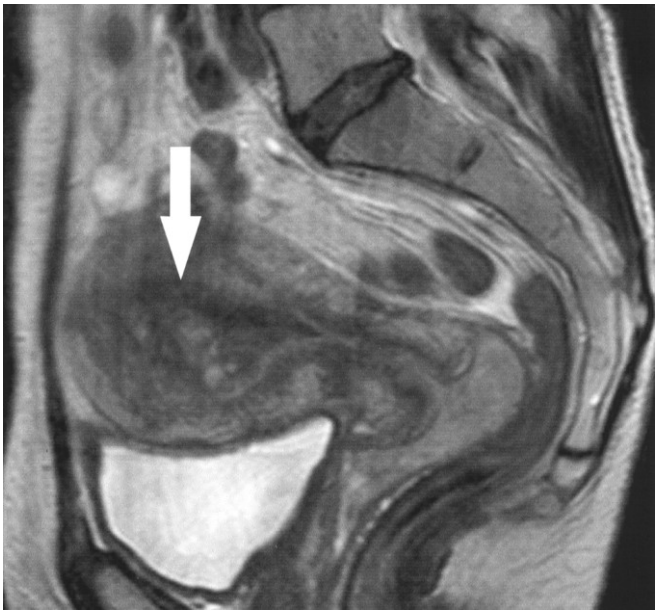

Figure 5: Heterogenous mass (arrow) in uterine cavity

Data from Noonan JB, Coakley FV, Qayyum A, Yeh BM, Wu L, Chen LM. MR imaging of retained products of conception. AJR Am J Roentgenol. 2003 Aug;181(2):435-9.

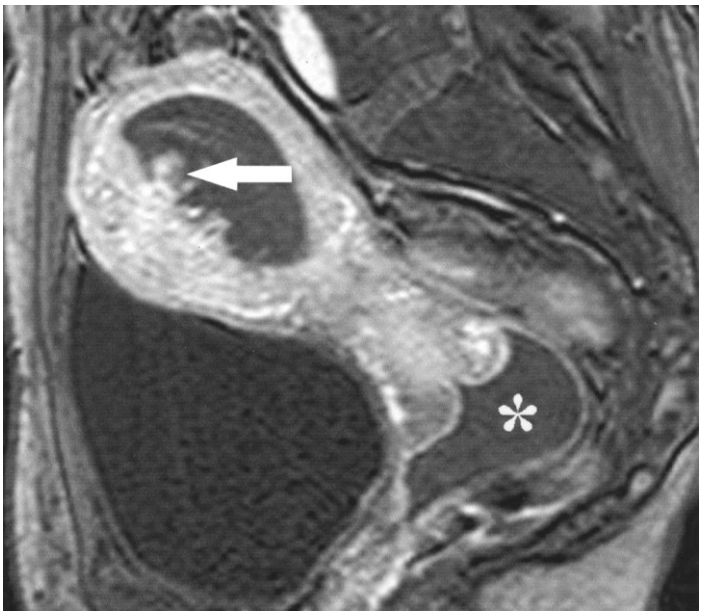

Figure 6: Areas of enhancement (arrow) within mass, fluid (asterisk) matching PPH in upper vagina

Data from Noonan JB, Coakley FV, Qayyum A, Yeh BM, Wu L, Chen LM. MR imaging of retained products of conception. AJR Am J Roentgenol. 2003 Aug;181(2):435-9.

2.2.1.1.3 Therapy of residual placenta

To avoid residual placenta due to insufficient contractions of the uterus, the World Health Organization (WHO) recommends active third stage of labour. This normally means intravenous (i.v.) administration of *Oxytocin* (Syntocinon®) soon after cutting/clamping the cord. The following steps are shown in Figure 7 (7). In case of actual residual placenta it is important to decide, whether to choose conservative management or surgery. There have been studies about conservative treatment, which should only be carried out, if the patient is haemodynamically stable and without any active bleeding. Measures that could be taken are (11):

Leaving placenta in its position AND

- Carry out adjuvant treatment like *Methotrexate*
- Bilateral ligation of hypogastric arteries
- Embolisation of uterine arteries

In cases of severe haemorrhage an early general anaesthesia for surgical intervention is recommended (7). The *Credé's* manoeuvre is used to stimulate uterine contractions and help it deliver the placenta. Therefore the obstetrician has to rub the uterus to provoke labour-pain and on its maximum intensity hold the *fundus* of the uterus firmly in his hands pushing it towards the pelvic axis (7).

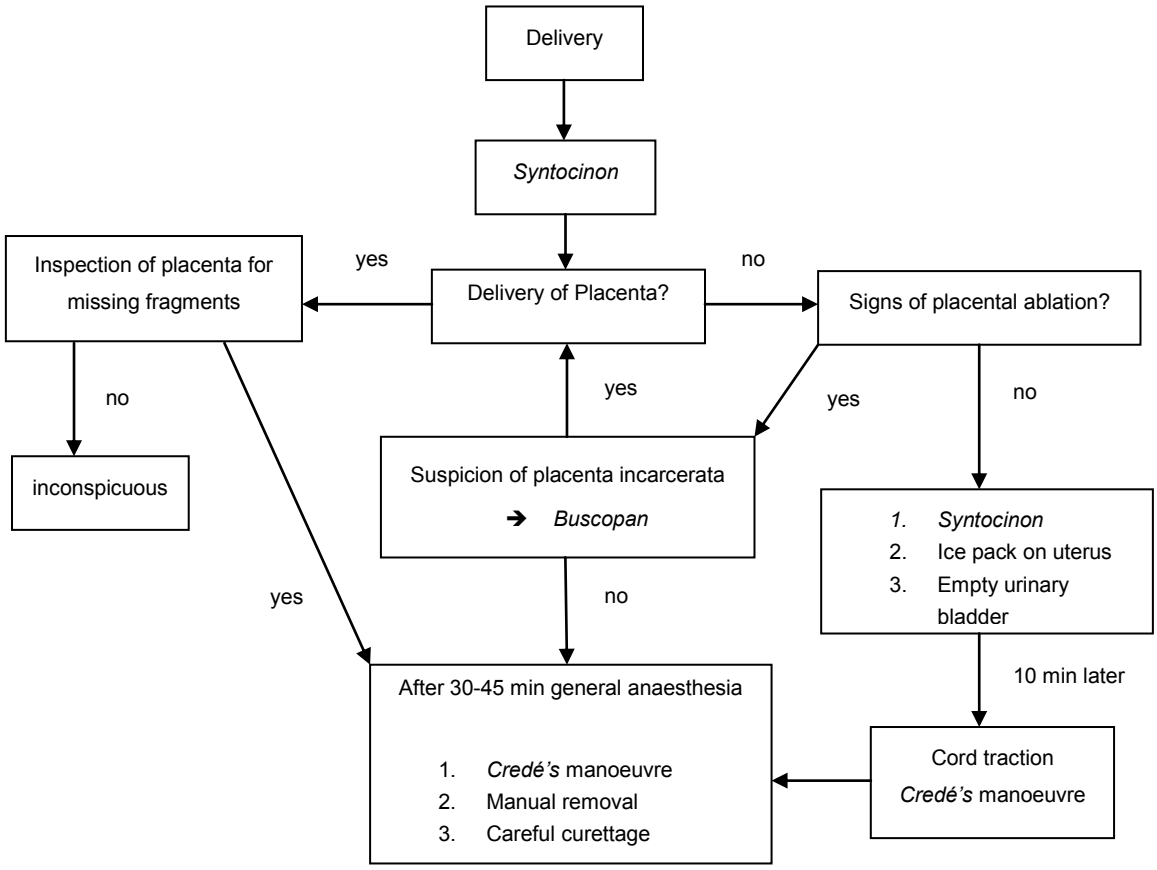

Figure 7: Approach of residual placenta

Data from Gruber S. Basics. Gynäkologie und Geburtshilfe. 3rd ed. München: Elsevier GmbH; 2009. p. 146.

Cord traction is another possibility to help the uterus deliver the placenta (7). The obstetrician pulls carefully the umbilical cord while his other hand pushes the uterus back to the pelvic axis. This manoeuvre however is quite risky as it can lead to rupture of the umbilical cord or eversion of the uterus. Other possible methods include the manual removal of the placenta or careful curettage – keeping in mind the soft consistence of the uterus after delivery. The obstetrician has to keep in

mind that perforation of the uterus is a dangerous complication of these methods (7). There is also evidence that women with repeated removal of placenta remnants or curettage after abortions tend to show intrauterine adhaesions (10).

If the placenta could not be separated by these techniques or if the haemorrhage could not be controlled by the above listed methods, further invasive interventions have to follow (manual compression, *Bakri* balloon, embolisation or ligation of the uterine arteries). The last resort would be hysterectomy (7; 10). Residual placenta is said to be one of the greatest risk factors for hysterectomy. Atony of uterus and uterine rupture are also strongly related (10). Sometimes hysterectomy is the only possibility to stop the excessive haemorrhage and safe the patient's life. However there are some severe complications linked to this procedure, such as required blood transfusions, need for re-exploration because of persistent bleeding, febrile morbidity, major surgical complications and even maternal death. Furthermore patients with the wish for future pregnancies lose their fertility (10).

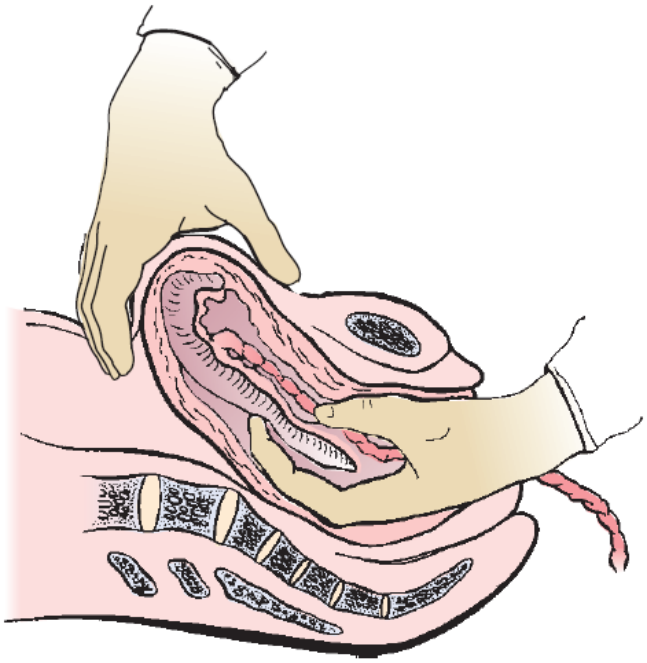

Figure 8: Manual removal of residual placenta

Data from Stauber M, Weyerstahl T. Duale Reihe. Gynäkologie und Geburtshilfe. 3rd ed. Stuttgart: Georg Thieme Verlag KG; 2007. p. 672.

2.2.2 Arteriovenous malformation of the uterus

2.2.2.1 Definition

Arteriovenous malformations (AVMs) develop out of abnormal communications between arteries and veins (15). The terms that have been used to describe this entity include cirsoid aneurysm, pulsating angioma, arteriovenous aneurysm, racemose aneurysm, arteriovenous fistula and cavernous haemangioma (16). They are said to exist more likely in the pelvis, but only rarely do they affect the uterus itself (17). The AVM is usually fed by one or more arteries, which then drain into a venous plexus, whereby the intervening capillary network is missing (18). Both the calibre of the different vessels as well as the extent of the uterine involvement might vary enormously. In most cases reported, the vessels tend to be prominent and dilated. The tortuous proliferation of channels leads to a diffuse vascular malformation. This might either be located within or on the surface of the uterine tissue, and the vessels might also open directly to the surface of the *endometrium* (19). An exact histological investigation explores that the abnormal proliferation shows both arterial and venous constituents with interconnecting fistulas at which the proportions of different vessel types may vary (20).

2.2.2.2 Subtypes

Two different subtypes might be distinguished, but it is not yet clear which of them is more common, a question where the current literature seems to be not quite sure, according to the different cases reported (21; 22).

2.2.2.2.1 Congenital uterine AVMs

The congenital type is due to a dysfunction of normal vascular embryologic development, so a vessel fails to differentiate either into an artery or a vein (23). It tends to have several feeding arteries and draining veins, connected by a *nidus* (24). Congenital AVMs are likely to invade the surrounding tissues and structures

(25). They are normally isolated, but they have also been reported in association with AVMs at other sites (15).

2.2.2.2.2 Acquired uterine AVMs

They develop after or are related to GTD, especially following treatment with chemotherapeutic agents, endometrial carcinoma or other uterine malignancies, *diethylstilboestrol* (DES) exposure, uterine trauma including prior surgery or D&C, use of intrauterine conceptive devices (IUCD), infection, subinvolution of placental site (non-obliteration of vessels after miscarriage or delivery), retained products of conception, traumatic fistula following caesarean section, necrosis of chorionic villi (venous sinuses become incorporated in scars), endometriosis or previous pregnancy (20; 26; 27; 28). This subtype is constituted by a single or bilateral feeding artery joining a single vein without a connecting *nidus* but multiple arteriovenous fistulas between the branches. Normally the uterine arteries build up the malformation without supply from extrauterine arteries (24; 25).

2.2.2.3 Epidemiology

Uterine AVM seems to be a rarity, because there are not many cases reported. We find only 73 in literature before 1997, but the true incidence is unknown. Most of the published examples are case reports or just small case series, which makes the exploration of the real frequency difficult (17). The first case was reported by Dubreuil and Loubat in 1926 (19). The youngest patient with possible diagnosis of uterine AVM was a stillborn at 34 weeks of gestation, and the oldest patient documented was a 72 year-old woman. However, most of the patients suffering from AVM were between the age of 20 and 40, which means that hormonal changes might play a role concerning the origin of this disease (17). Though there have been reports in adolescence as well as following the menopause, this entity is more likely to appear among women of reproductive age and are more prevalent in patients with bleeding complications in pregnancy, after delivery or uterine instrumentation (20; 23). As uterine AVM could lead to potentially life threatening

complications, we have to be aware, that they are probably more frequent than thought.

2.2.2.4 Previous events

As already discussed in chapter 2.2.2.2.2 many patients have undergone different clinical procedures and maybe even complications or events at different times before they were diagnosed with uterine AVM. These include pregnancies with or without complications for retained products of gestation, caesarean section, IUCD, spontaneous abortion, cervical conisation, termination for unwanted pregnancy by D&C, D&C for abortion or miscarriage or any other previous surgery (19; 21; 22; 26). Most likely these interventions were the exact moment when the symptoms of AVM showed for the first time, as the layer of *endometrium* covering the lesion is very thin (20).

2.2.2.5 Symptoms

The main acute symptom every reported case showed was vaginal or uterine bleeding either associated with medical intervention or (more rarely) spontaneously but with no obvious cause. This varied from mild intermittent to profuse or even torrential bleeding, so that in certain cases massive blood transfusion was necessary(26). There have been intermenstrual, postmenopausal and early as well as heavy delayed postpartum bleedings described (22; 26). The postpartum haemorrhage often resulted partly from curettage performed for residual placenta (20; 23). The loss of blood often led to a low haematocrit and haemoglobin (anaemia) or even to tachycardia and shock in severe cases (17; 19; 21). Symptoms like lower abdominal or back pain and dyspareunia have also been reported (27; 28). The chronic symptoms spotted were heart failure, fatigue and dyspnoea due to a serious circulatory disturbance called vascular steal syndrome (15; 25; 28). AVM could also be the reason for recurrent pregnancy wastage (29). Although AVM always carries the risk of a great magnitude of blood loss, there have been only two deaths reported in literature (15).

2.2.2.6 Diagnosis

Diagnosis of uterine AVM has proved to be difficult. Nevertheless it is important to be aware of this lesion especially preoperatively in any patient suffering from any form of recurrent abnormal vaginal or uterine bleeding. This is the only way the bleeding is treated adequately and not by curettage which might be lethal (22).
Historically the diagnosis of uterine AVM was retrospective, as it was only proven by laparotomy or hysterectomy performed for heavy bleeding (15; 19). Nowadays these interventions as diagnostic and therapeutical methods might be avoided by early diagnosis with the help of different examinations and techniques:

2.2.2.6.1 Clinical examination

The clinical examination including palpation of the lower abdomen and the investigation of the vagina per speculum is the first step of diagnosis. Both a soft and nontender abdomen can be found as well as a slightly painful one (15; 27). Speculum examination revealed mild to heavy vaginal bleeding or at least signs of blood clots in the vagina in most of the reported cases (15; 17; 19; 21; 27). Rarely a pulsatile mass in the pelvis was detected (20). The uterus is usually anteverted and is either of normal size or slightly enlarged, nontender or bulky (17; 18; 27). No thrill or bruit was mentioned (27). Further steps of investigation include the evaluation of coagulation studies and a pregnancy test, so it is possible to exclude differential diagnoses like GTD or coagulopathy (15; 27).

2.2.2.6.2 Ultrasonography

Transvaginal US is the most common imaging technique carried out for the diagnosis of uterine or vaginal bleeding. However the use of gray-scale US alone is probably not enough to distinguish between AVM and other pathologies, but might of course play a role (20; 21).

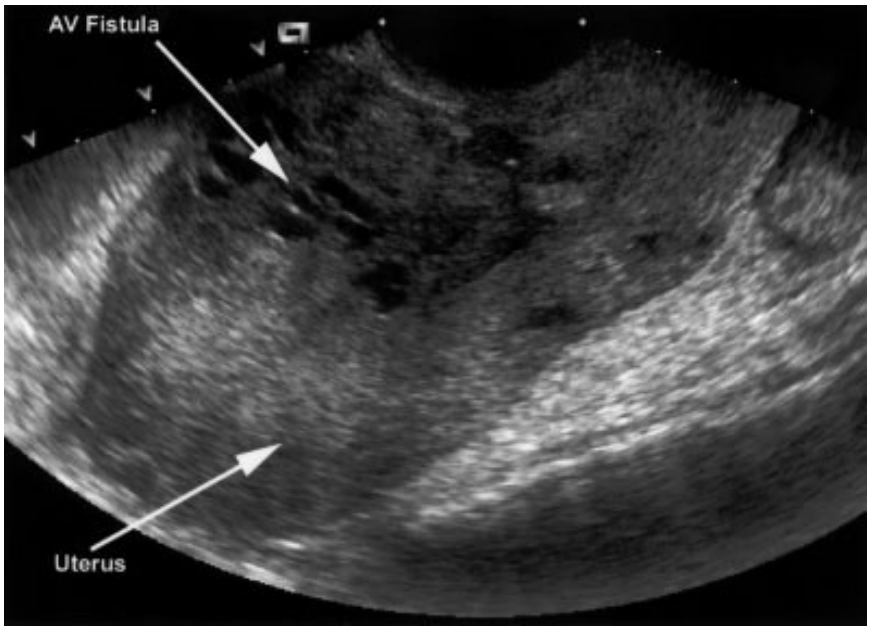

Figure 9: Gray-scale image of the arteriovenous malformation with prominent cystic spaces within the myometrium

Data from Kelly SM, Belli AM, Campbell S. Arteriovenous malformation of the uterus associated with secondary postpartum hemorrhage. Ultrasound Obstet Gynecol. 2003 Jun;21(6):602-5.

The addition of features like Colour Doppler or Pulsed Doppler and more recently different applications of volume ultrasound can contribute to the correct diagnosis to a great extent. Whereas B-mode (brightness-mode) is not specific and therefore not diagnostic (27), blood-flow studies are able to provide a more specific image of the lesion and other entities like aneurysms or chorangioma of the placenta (26; 28). The use of Pulsed Doppler allows an analysis of the waveform, which also makes the diagnosis of AVM easier (20).

As the size of vessels connecting to the AVM varies, there are different descriptions found in literature (25). Altogether is the fact that the vessels demonstrated a diameter which is greater than the normal calibre (15). Gray-scale US showed hypoechoic areas partially even multiple anechoic tortuous structures or cystic formations in the *myometrium* or an inhomogeneous mass in the *endometrium* in almost every case reported (17; 21; 24; 26; 27). In one case it was obvious that those masses were involving the scars of a prior caesarean section (26). After addition of vascular flow by Colour Doppler, hypervascularity was shown and an arterial as well as venous spectral pattern was revealed (21; 27). The mass presented a rapid and turbulent blood flow picturing a colour mosaic

with flow reversals (26; 28). Pulsed Doppler analysis of the flow pattern pointed out low-impedance and high-velocity flow through systole and diastole. A high peak systolic velocity (PSV) with low values for resistance index (RI) and pulsatility index (PI) was evaluated (20). Timmerman et al. found out (28) that the PSV value could be a useful tool to distinguish between low- and high-risk patients of AVM. A PSV value of over 0.83 m/s is said to be potentially life threatening, a value below 0.83 m/s less dangerous and a value below 0.39 m/s should be safe. The PSV value further allowed identification of the feeding artery (27).

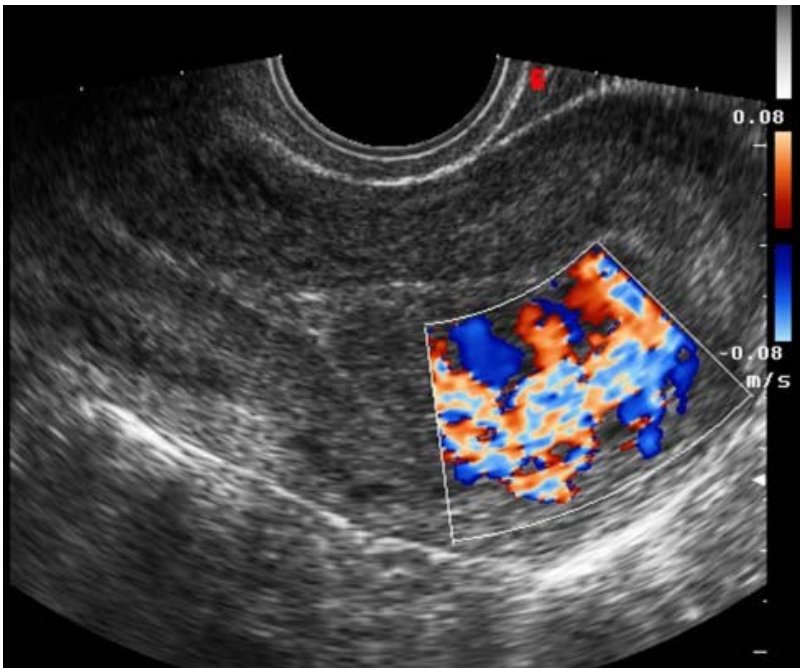

Figure 10: Longitudinal transvaginal ultrasound scan with colour Doppler demonstrating mixed arterial and venous flow in the body of the uterus posteriorly

Data from Rangarajan RD, Moloney JC, Anderson HJ. Diagnosis and nonsurgical management of uterine arteriovenous malformation. Cardiovasc Intervent Radiol. 2007 Nov-Dec;30(6):1267-70.

Ultrasonography with Colour and Pulsed Doppler is definitively the screening tool of uterine AVMs and also the ideal diagnostic method for following-up patients (24).

2.2.2.6.3 Hysteroscopy

There are only few case reports where hysteroscopy has been used to find the cause of vaginal or uterine bleeding. In these cases an unusual *endometrium* and a large pulsating vascular lesion in the uterine cavity were noted, but most of the time this kind of examination is difficult to perform, due to a view obscured by blood (15; 22), and too time consuming in an emergency situation.

2.2.2.6.4 Computed tomography angiogram

An intravenous 'dual-phase' computed tomography (CT) angiogram is sometimes performed after US to identify the complete extent of the malformation non-invasively. After injection of an iodinated contrast medium, a helical scan for arterial phase is carried out in cranio-caudal direction and inversely for venous phase scanning. Then the affected vessels can be traced over several axial sections to find out about their exact course. Often an elegant 3D (3 dimensional) reconstruction is used (18). As the results of CT angiogram match very well with those of pelvic angiography it could be a useful method for the evaluation of uterine AVMs for the planning of both surgical and conservative interventions (18).

2.2.2.6.5 Magnetic resonance imaging

MR-imaging is another non-invasive technique of tomographic imaging normally performed after US to confirm the diagnosis of uterine AVM. It is also carried out before further intervention to find out more about the lesion's extent and to determine which vessels are involved (21). Conventional and dynamic gadolinium enhanced MR-imaging revealed a pathological circulation within the expanded *endometrium*. Multiple flow-related signal voids were visible (21; 22). After infusion of contrast medium a rapid enhancement within the lesion was spotted, combined with disruption of the endometrial-junctional zone boundary (26).
If vascular malformations are suspected during US, MR-imaging is indeed a common method to evaluate the extent of the lesion and for further selection of patients for pelvic angiography (26).

2.2.2.6.6 Pelvic angiography

The invasive method of pelvic angiography is the gold standard among tomographic imaging techniques for uterine AVMs. Even though it allows a definite diagnosis, it is no longer used for purely diagnostic purposes as there are many easier and less invasive techniques like Doppler US and MR-imaging, which have replaced angiography as a screening method and are also able to determine the extent of the AVM. Traditionally a tortuous and dilated vascular mass is noted in the uterus (21; 24; 26).

The great advantage of pelvic angiography is the fact that immediate intervention in form of selective transcatheter arterial embolisation can be performed (21).

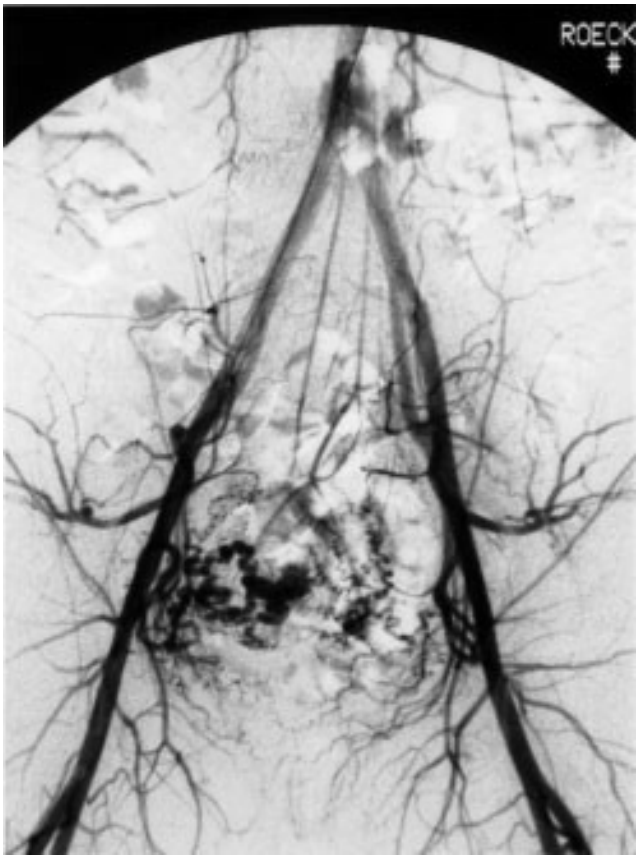

Figure 11: Early phase angiogram showing filling of the uterine artery and the arteriovenous malformation

Data from Kelly SM, Belli AM, Campbell S. Arteriovenous malformation of the uterus associated with secondary postpartum hemorrhage. Ultrasound Obstet Gynecol. 2003 Jun;21(6):602-5.

2.2.2.7 Therapy

2.2.2.7.1 Acute measures

As the main acute symptom of uterine AVM is haemorrhage, the first measure that should be taken is the controlling of active bleeding for haemodynamic stabilisation (26; 27). In accordance with literature this has either been achieved by tamponade, occlusion with *Foley* catheter bulb or intramuscular injection of *methylergonovine* or *prostaglandin F2a* (18; 26). In 30% of the reported cases, the bleeding was so severe that massive transfusions of blood were necessary because of anaemia or shock (21).
It is important always to be aware of possible AVMs so that contraindicated procedures like curettage, which might aggravate the bleeding, can be avoided in any case (19; 26).

2.2.2.7.2 Hysterectomy

Hysterectomy has historically been the therapy of choice for vaginal bleeding, especially as emergency hysterectomy for intractable uterine haemorrhage (15). Nowadays it is still carried out after recurrence of uterine AVM, non-successful attempts of other treatments like transcatheter arterial embolisation or after complications like heavy bleeding due to curettage, as it is by all means the definitive treatment to eliminate bleeding and its consequences (15; 17; 26; 27). The obvious disadvantage of hysterectomy for treatment of uterine AVM is the loss of fertility, so among patients in reproductive years this therapy might lead to considerable psychological distress (21; 22). Furthermore there are reports of uterine AVMs which could not be cured by hysterectomy as the lesion was spreading to the upper vagina and the symptoms stayed (30).

2.2.2.7.3 Transcatheter arterial embolisation

This is probably the preferred method of treatment of uterine AVMs as it is quite safe and effective, especially among patients of reproductive age, who want to retain their fertility (22).

This intervention can be carried out in combination with the diagnostic pelvic angiography, so normally the patient is asked to give her consent for embolisation prior to angiography (20). The procedure is performed under local anaesthesia by a skilled radiologist (21). The first step is the insertion and advancement of a catheter into the punctured femoral (or rarely axillary) artery (15). Then the aim is to occlude the arterial vessels which supply the uterine AVM in retrograde direction. Therefore many different materials like *polyvinyl alcohol* particles (PVA), gelfoam pledgets, *thrombin*, *isobutyl 2-cyanoacrylate*, lead microspheres and stainless steel coils have been used (15; 27). As the incidence of many collateral feeding vessels is quite high among uterine AVMs, several embolisation events might be needed to terminate the blood supply to the lesion (15).

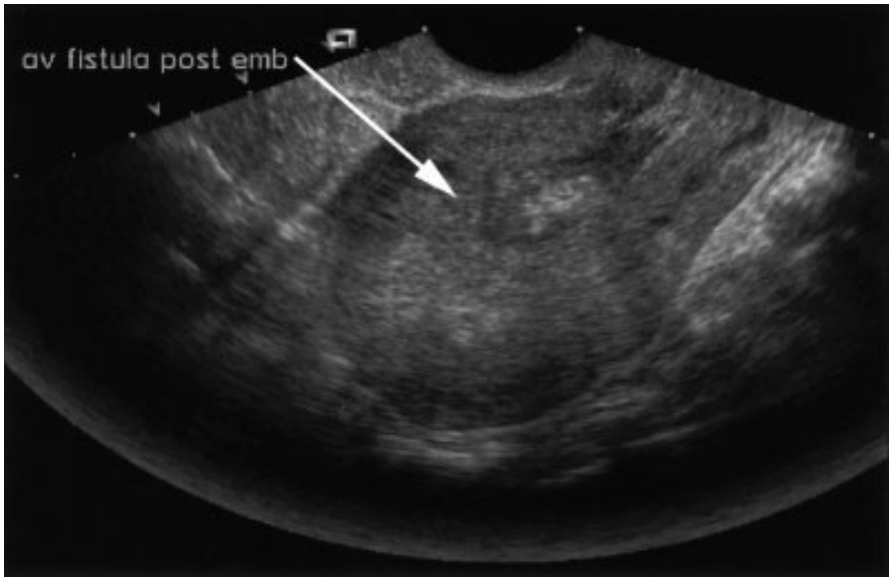

Figure 12: Gray-scale image of the arteriovenous malformation following selective embolisation

Data from Kelly SM, Belli AM, Campbell S. Arteriovenous malformation of the uterus associated with secondary postpartum hemorrhage. Ultrasound Obstet Gynecol. 2003 Jun;21(6):602-5.

Because of the different characteristics of congenital and acquired AVMs, it seems to be much easier to treat the acquired subtype, as there is no intervening network and mostly only two vessels, a feeding and a draining one (24).
One disadvantage of transcatheter arterial embolisation is that uterine AVMs are likely to build several collaterals, so recurrence happens quite often and thus more than one procedure is frequently required (22; 26). For this reason several reports mention, that it is probably necessary to perform the procedure from both sides, so that the AVM can't be supplied by the corresponding vessel of the contralateral side (22; 31).
However, other reports are of the opinion that an AVM fed by vessels of only one side should be treated by selective unilateral embolisation, as this minimises the complications for further pregnancies. The treated area is inevitably hypovascular which might affect the placenta and fetal growth (21).
Recently US-guided transvaginal embolisation of AVMs with fibrin glue was safely and successfully achieved (32).

2.2.2.7.3.1 Complications

Besides from recurrence of the lesion which can lead to a repetition of the procedure, there are not many complications reported and most of the patients showed an uneventful recovery. In some cases post-procedure fever occurred, which could be controlled conservatively (22; 26). Mild suprapubic pain was also described (22). One case report mentioned a vascular rupture after follow-up angiography, due to the high injection pressure in the coil occluded artery (22).
There are some concerns about future pregnancies expressed in literature, which are discussed in the following chapter.
By all means frequent follow-up examinations by US, MR-imaging and angiography are advisable (21; 22).

2.2.2.7.3.2 Post-procedure pregnancy

Although transcatheter arterial embolisation of uterine AVMs seems to be a safe and effective method of treatment, its long term effect on fertility has not been fully evaluated (33). In the majority of patients the therapy did not influence the uterine or ovarian function which led to the return of a normal menstrual cycling allowing successful pregnancies (22; 33). Nevertheless transient and also persistent amenorrhea has been reported, which is probably caused by a loss of ovarian arterial perfusion, which can fortunately be re-established in the majority of women (33). However, there are not many reports of successful pregnancies in current literature. The first case was described by Chapman and Lutz in 1985 (31). All in all between 1985 and 2005 thirteen cases of successful delivery have been mentioned, with delays between embolisation and pregnancy varying from six weeks to five years (31). Another report mentions a patient with ectopic tubal pregnancy after embolisation. As she was thought to have had normal reproductive function before the procedure, the hypothesis occurred, that transcatheter arterial embolisation might disturb the function of the fallopian tube (33). There is one case of embolisation after which a patient underwent in vitro fertilisation with uterine embryo transfer, which led to a dichorionic diamniotic twin intrauterine gestation (29).

Summarily it can be said, that pregnancy after transcatheter arterial embolisation carries a higher risk of prematurity, placental abnormality, ovarian dysfunction or abortion, whereas growth retardation and uterine rupture have not been reported (27). As the complications mentioned above are most likely due to a disturbance of perfusion, selective unilateral embolisation with preservation of corresponding vessels seems to improve the obstetric outlook. Furthermore delivery per caesarean section might be advisable (31).

2.2.2.7.4 Ligation of feeding arteries

As mentioned above transcatheter arterial embolisation does not always cure patients from uterine AVMs. In some cases, after an unsuccessful transcatheter intervention another treatment might be necessary. Normally, hysterectomy is the

definitive treatment. However in some cases this procedure might be too dangerous as it carries a higher risk of massive blood loss. That's the case in patients with AVM of extraordinarily dilated and tortuous vessels within and around the uterus' tissue. If so, the surgical ligation of the feeding arteries should be the therapy of choice (30).

The repetition of transcatheter arterial embolisation in those cases is also not indicated, as a controlled catheterisation in such dilated vessels is quite difficult and the higher blood flow carries the risk of pulmonary embolism caused by embolic materials (30).

2.2.2.7.5 Medical treatment

In some selected cases mainly in acquired uterine AVMs with moderate symptoms a conservative treatment in the form of medical therapy is also possible (31). There are only few cases reported with treatment of either *methylergonovine* or hormonal. The advantage is the non-invasive procedure which furthermore preserves fertility among patients in reproductive years (27). The hormonal treatment used in the published case was a combined oral contraceptive pill with 50 µg *ethinyl oestradiol* called Microgynon50®. As the reported AVM was of the acquired subtype, it might also have regressed spontaneously or as result of therapy with the contraceptive pill. Oestrogen therapy has also been used to cure gastrointestinal AVMs causing bleeding, but the exact mechanism is still unclear. It could be the hormonal influence on the endothel's integrity or an effect on the bleeding time (16). *Methylergonovine* and hormonal therapy has been prescribed to control active bleeding as well as for long-term use (16). Treatment with *goserelin acetate* (Zoladex®, Zeneca®) as initial therapy and after unsuccessful transcatheter intervention is also mentioned in literature, but doesn't seem to be quite effective (22).

In moderate cases of uterine AVM medical treatment could indeed be a successful way of therapy, however, regular follow-up is indicated in all cases (31).

2.2.3 Postpartum haemorrhage

The placental stage is quite risky for the parturient as severe postpartum haemorrhage (PPH) might occur. PPH is defined by an amount of blood loss of over 500 ml within 2-4 hours postpartum or over 1000 ml after caesarean section. There are several reasons for PPH like lesions of the vagina or coagulation disorders, the main reason however is a strong bleeding of the wound where the placenta has been attached to the *endometrium* of the uterus. This might happen after complete separation of the placenta or even with residual placenta (8).
There are many different definitions going round concerning the amount of blood loss of PPH and so are different classifications. In Australia, Belgium, Canada, France, the United Kingdom and the USA PPH is stratified by cause (13; 34):

- Third stage haemorrhage: PPH due to retained placenta
- Other immediate PPH within the first 24 hours following delivery of placenta (uterine atony)
- Delayed and secondary PPH: after the first 24 hours following delivery to 12 weeks postpartum
- Postpartum coagulation defects
- Other causes

The most common causes for secondary PPH are an abnormal involution of the placental site, endometritis or retained placental tissue. AVM of the uterus is another rare cause (13). PPH before or after delivery of placenta is the greatest risk factor of maternal mortality (8).

3 Methods and Material

At the Division of Obstetrics and Maternal Fetal Medicine at the Medical University of Graz the course of pregnancies, births and postpartum periods is documented via electronic health records called MEDOCS, PIA and ViewPoint since approximately 2003. AVMs of the uterus are known to be a possible cause of severe haemorrhage postpartum or in the puerperium. As this entity is rarely diagnosed before the occurrence of postpartum complications, for this study cases with residual placenta and postpartum surgical events like D&C have been investigated in order to find events showing the possible diagnosis of uterine AVMs. A retrospective data analysis has been carried out by investigating cases of patients with postpartum operations like D&C or hysteroscopy due to residual placenta or ongoing postpartum haemorrhage. Special attention was given to patients, who suffered from complications (severe haemorrhage, repeat interventions) after the procedure mentioned above, as this could be a sign of undetected AVM of the uterus.
For the query only electronic health records were analysed, handwritten patient charts or nursing documents have not been used.

3.1 Patient population

In an attempt to find all cases of possible postpartum haemorrhage due to AVMs of the uterus we have conducted a query of the two electronic patients records systems: MEDOCS – the general electronic documentation software of the department including both obstetrical and gynaecological cases and especially records of surgical interventions and secondly ViewPoint Fetal Database – a primarily obstetrical electronic patient records system.
The study includes all patients of the Division of Obstetrics and Maternal Fetal Medicine at the Medical University of Graz, who have been diagnosed with residual placenta after birth from 2003 to 2011. Not only cases with residual placenta after live birth were analysed, but also residual placenta after spontaneous, missed or medically induced abortion. The maternal age included

was age 17 to 45. The study contains primiparae as well as multiparae. Both singleton and multiple pregnancies that fulfilled the search criteria were included in the data analysis.

3.2 Data acquisition

An automated query has been carried out looking for either one or more of the following diagnosis or medical procedures in patients' electronic health records from 2003 to 2011 (*Table 1*).

Diagnosis:
Residual placenta
Haemorrhage in the puerperium
Postpartum anaemia due to haemorrhage
Postpartum clotting disorders
Placental polyp
Other pathologic condition of the placenta
Sepsis
Medical procedures:
Curettage
Dilatation and Curettage

Table 1: Considered diagnosis and procedures

The information gathered this way was collected in a data file generated in Microsoft Office Excel 2007. As there were about 4000 cases reported, the next step was to extract all cases with documentation of actual residual placenta in MEDOCS. For all further analysis these 277 cases have been used in a detailed retrospective investigation using the selected patients' electronic health records in

MEDOCS and ViewPoint. The following parameters have been selected and a data file in Microsoft Office Excel 2007 has been created (*Table 2*).

Maternal date of birth
Age of patient on day of current examination
Date of current examination
Relevant previous conditions (caesarean section, abortion, other uterine surgeries)
Date of delivery of current child (or date of abortion)
Mode of conception
Gravidity
Parity
Single or multiple pregnancy
Gestational age (week of pregnancy)
Mode of birth (spontaneous, caesarean section, vacuum extraction, forceps delivery)
Special circumstances of the delivery
Diagnosis residual placenta (yes/ no), placenta missing fragments?
Further diagnosis (haemorrhage in puerperium, sepsis, placental polyp, clotting disorders)
Anomaly of placental separation (yes/ no)
Management and medical service
Amount of blood loss (moderate/ severe)
Haemoglobin/ Anaemia
Blood transfusions (yes/ no)

Table 2: Parameters of detailed analysis

After having a detailed look at the collected parameters, only cases with severe haemorrhage (as clinically most relevant sign of an AVM) were analysed again to find out more about the histological examination of the placenta and the course of haemoglobin and its treatment.

3.3 Analysis and statistical evaluation

After the acquisition of the relevant data had been completed, the analysis was carried out using Microsoft Office Excel 2007. Using the filtering function, tables and figures were generated by bringing the collected parameters into relation. Firstly the whole patient population was analysed and secondly cases before and after the completed 24th week of pregnancy were examined separately.

4 Results

All together there were 277 patients between 2003 and 2011 showing the diagnosis 'residual placenta' (code o73.0 or o73.1) in their electronic MEDOCS health records. More precisely spoken there were actually 273 patients but 277 cases, as 4 patients showed the diagnosis twice in the period mentioned above. In the following chapters those four cases will be treated as individual patients.

4.1 Maternal facts

The range of maternal age at the date of delivery goes from 17 to 44 years in the study (*Figure 13*). The average maternal age is 30 years, the median 30.5 years. 4 patients are 18 years or younger which amounts for 1.4%.

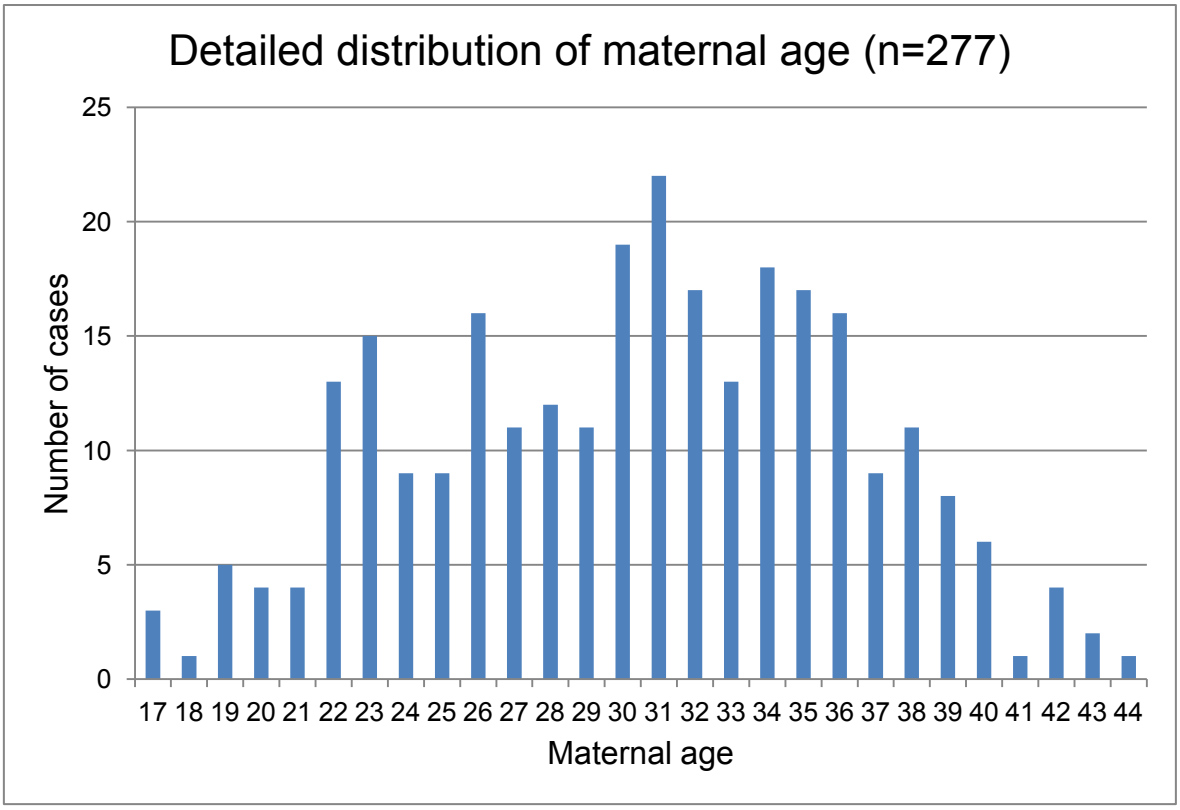

Figure 13: Detailed distribution of maternal age

75 patients (27.1%) are 35 years or older (*Figure 14*).

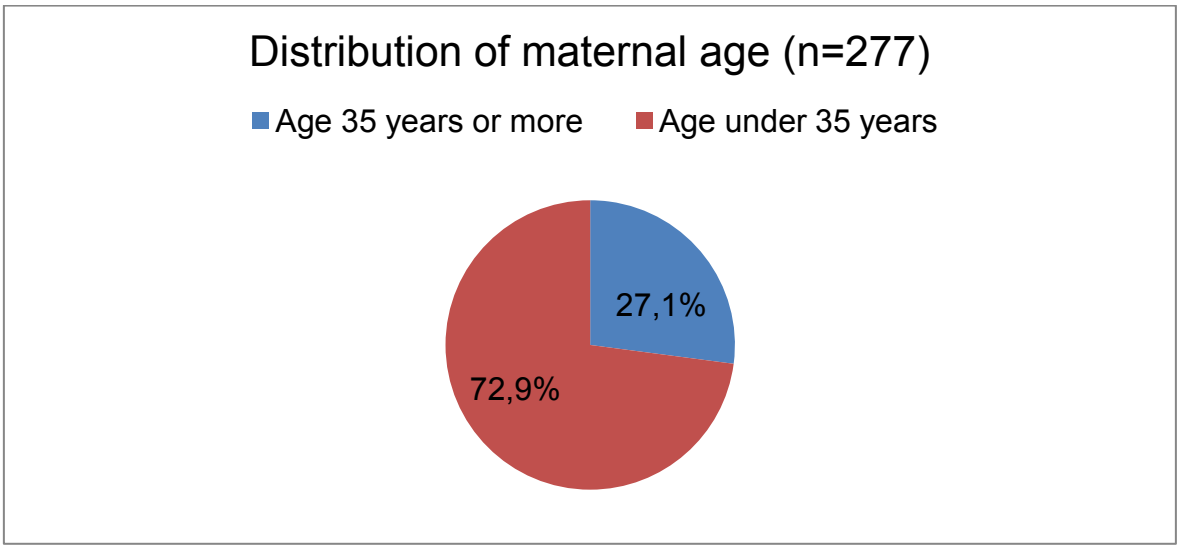

Figure 14: Distribution of maternal age

115 patients of 277 (41.5%) had at least one previous medical event, which could be related to residual placenta, before their current delivery or miscarriage (*Figure 15*). 156 patients didn't show any prior gynaecological or obstetrical events (56.3%). In 6 cases the patient history did not include data about the possible existence of such previous events.

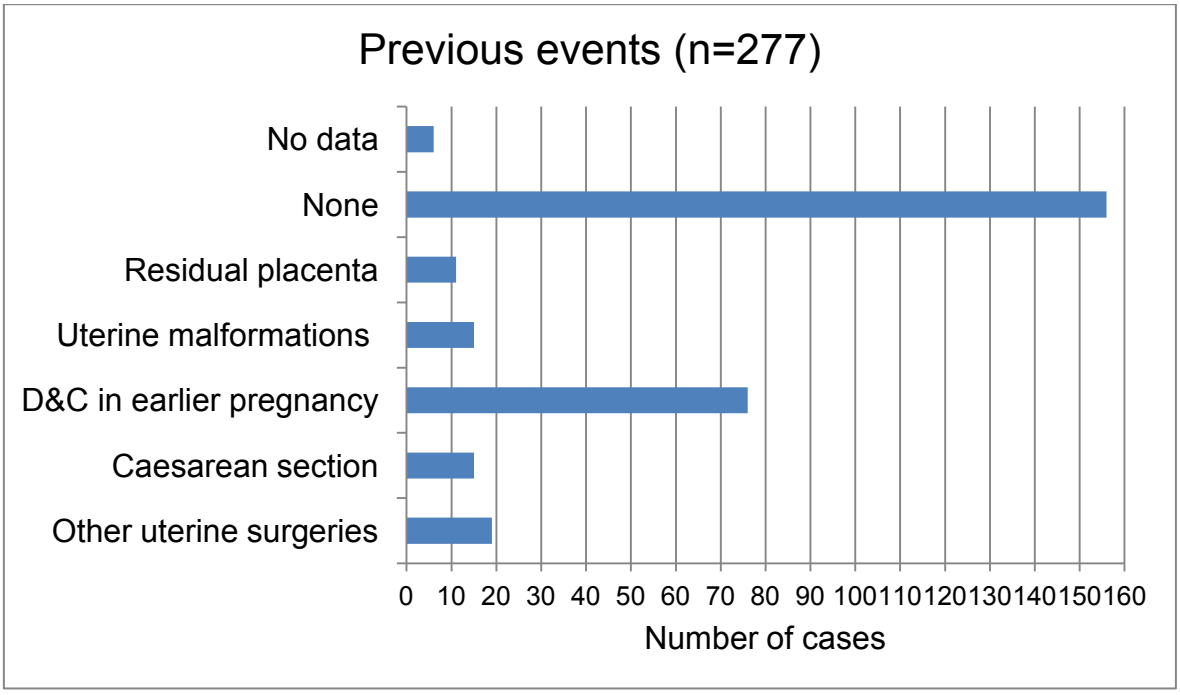

Figure 15: Previous events

11 patients already experienced residual placenta after a previous delivery (4.0%). 15 women (5.4%) suffered from uterine malformations (like *uterus myomatosus, bicornis, arcuatus, subseptus*), endometriosis or polyps. A D&C was carried out in earlier pregnancies in 76 patients (27.4%), mostly because of TOP. In 15 patients (5.4%) a caesarean section was performed in an earlier pregnancy. 19 women (6.9%) underwent other uterine surgeries like conisation or cerclage.

4.2 Pregnancy and delivery

The average gestational age of patients at the time of the procedure was the 36th week of pregnancy within a range from the 6th week to the 43rd week, so the median was the 30th week (*Figure 16*). In 28 cases it was not possible to find a detailed gestational age so they were just divided into cases before or after the 24th week of pregnancy by considering the individual context.

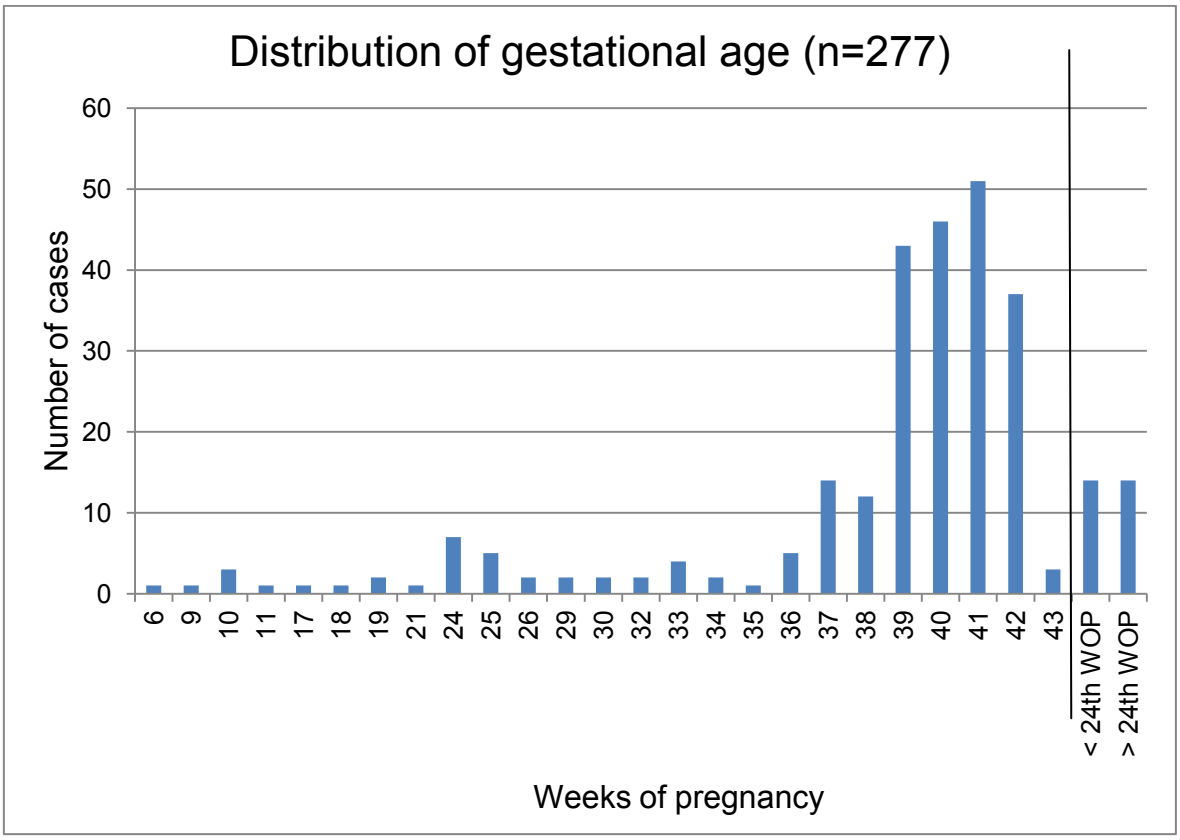

Figure 16: Distribution of gestational age

Of 277 cases there were 31 cases (11.2%) before the completed 24th week and 246 cases (88.8%) older than the completed 24th week (*Figure 17*).

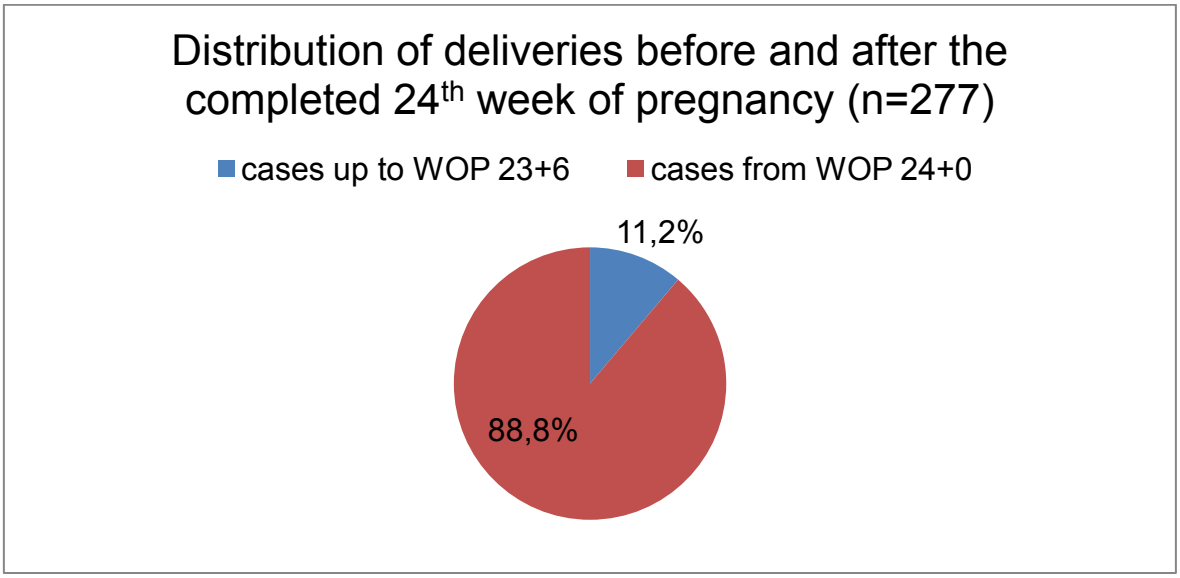

Figure 17: Distribution of deliveries before and after the completed 24th week

As the cases before the completed 24th week were abortions, the birth mode was only analysed in the group with gestational age over 24 weeks (*Figure 18*).

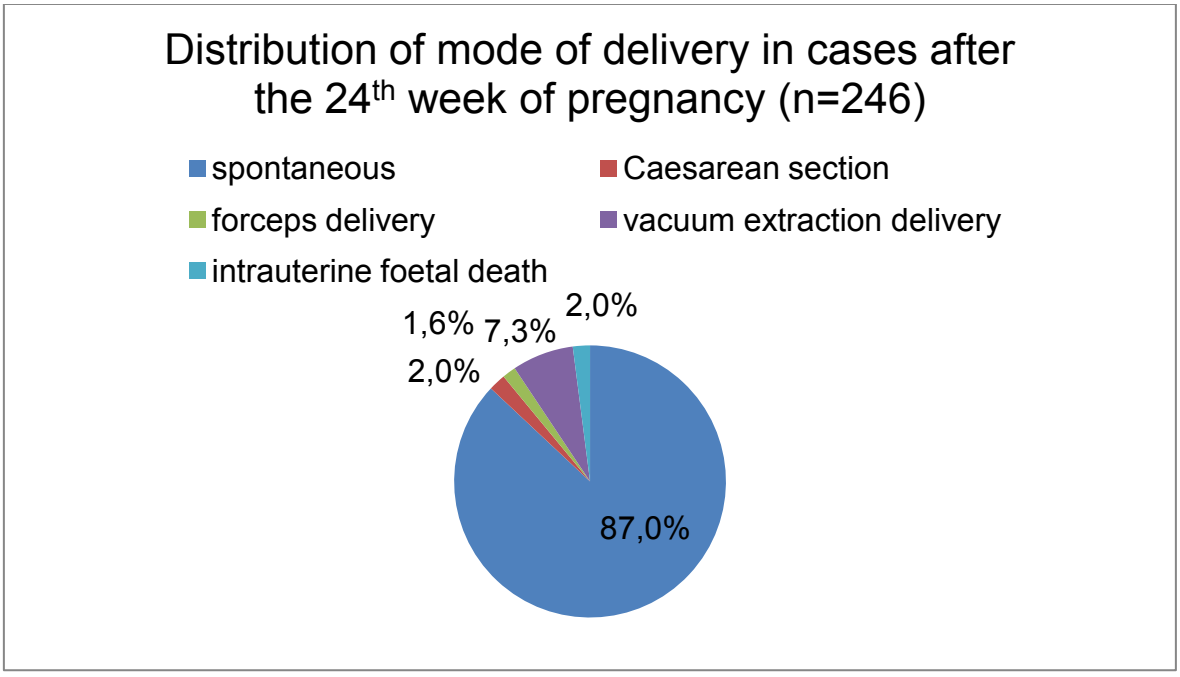

Figure 18: Distribution of mode of delivery in cases after the 24th week

214 patients of 246 had a spontaneous delivery (87.0%). This patient population contains 213 singleton pregnancies and 1 twin pregnancy. A caesarean section was performed in 5 patients (2.0%). 4 women (1.6%) underwent forceps delivery and 18 women (7.3%) had a vacuum extraction assisted delivery. In 5 cases (2%) the pregnancy was terminated due to intrauterine fetal death.

For the majority of patients (34.7%) the current pregnancy was their first, for 1 woman it was the 10th pregnancy (*Figure 19*). In 15 patients' health records it was not possible to find out about the number of pregnancy.

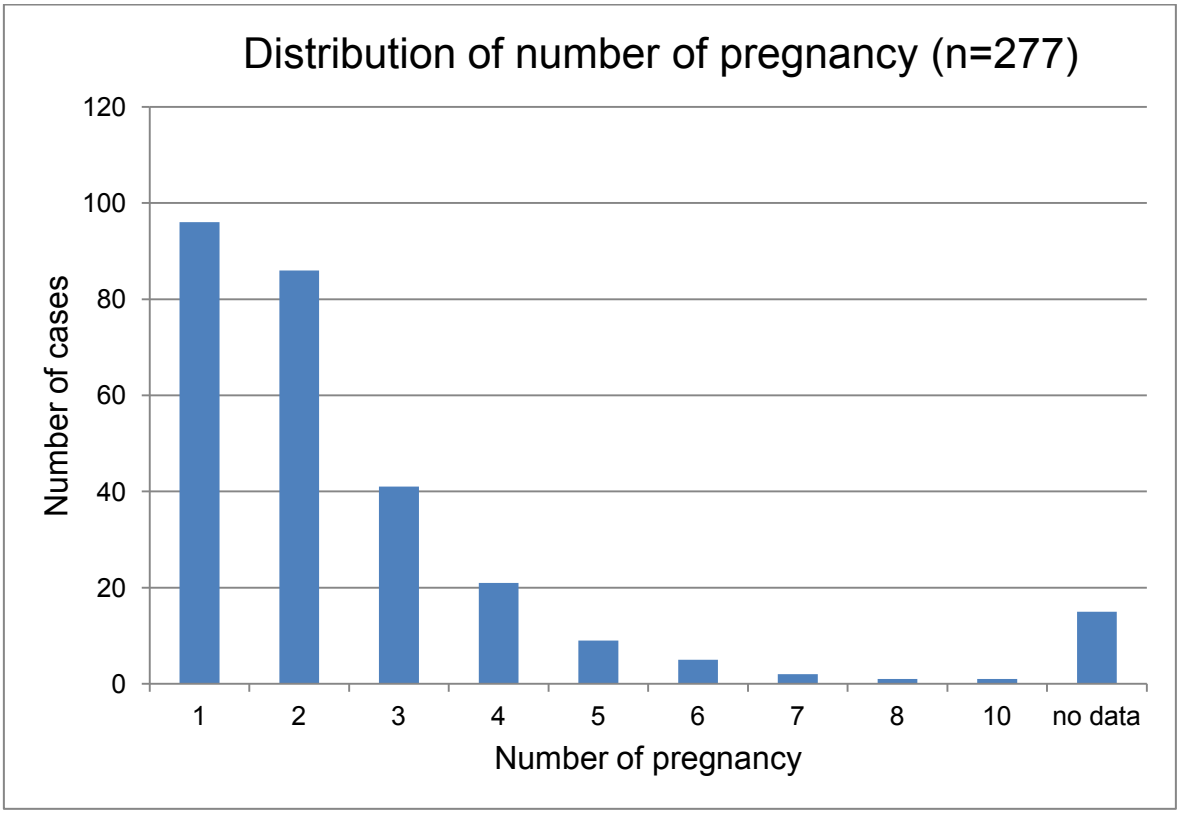

Figure 19: Distribution of number of pregnancy

For 119 patients (43.0%) the current delivery was their first (*Figure 20*). 34 of those primiparae had at least 1 abortion before. In 19 cases (6.9%) the current pregnancy was terminated by abortion, which is parity 0 in the figure. It was the second delivery for 79 women (28.5%). 25 of the cases (9.0%) had their third delivery. 10 women (3.6%) underwent their fourth delivery. 6 patients (2.2%) gave

birth for the fifth time. For 2 women (0.7%) the current delivery was their sixth. For 2 patients it was the seventh and eighth delivery respectively. In 15 cases (5.4%) the number of their current delivery was not documented in MEDOCS or ViewPoint health records.

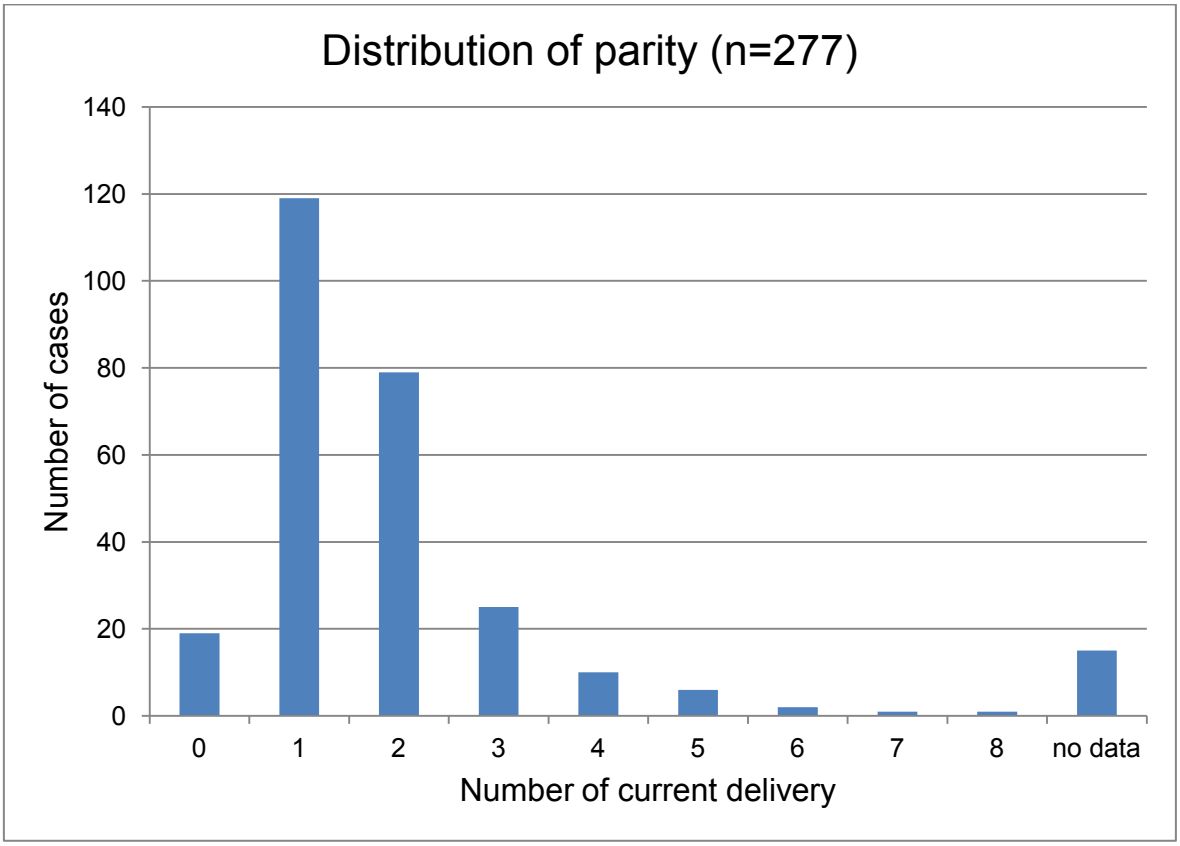

Figure 20: Distribution of parity

4.3 Placenta

277 patients showed the diagnosis 'residual placenta' in their health record in MEDOCS. 157 women showed the detailed description of *placenta adhaerens* in ViewPoint Fetal Database, which is 56.7% (*Figure 21*). In 4 cases a *placenta accreta* was suspected (1.4%). 109 patients were diagnosed with retained placenta (39.4%). In 7 cases (2.5%) prolonged placental detachment occurred.

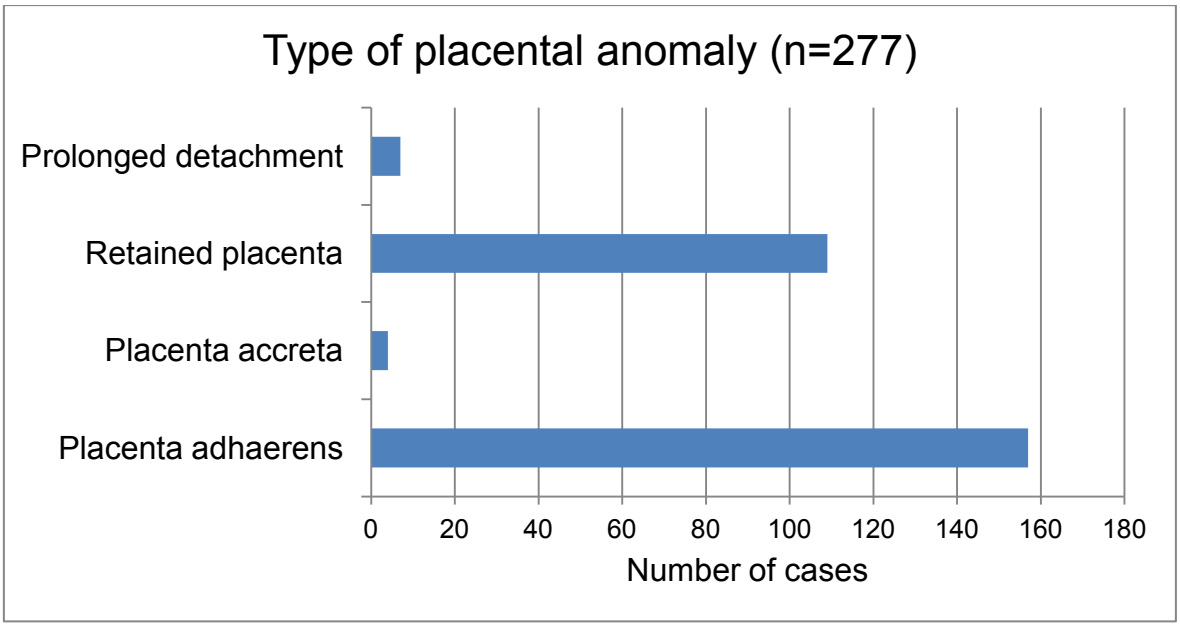

Figure 21: Type of placental anomaly

Besides from the diagnosis residual placenta, patients also showed other diagnoses in MEDOCS (*Figure 22*). In 32 women (11.6%) haemorrhage in the puerperium was documented. 2 patients suffered from sepsis (0.7%). 7 health records revealed postpartum anaemia due to haemorrhage (2.5%). 1 woman had a placental polyp (0.4%). Other pathologic condition of the placenta was detected in 2 cases (0.7%).

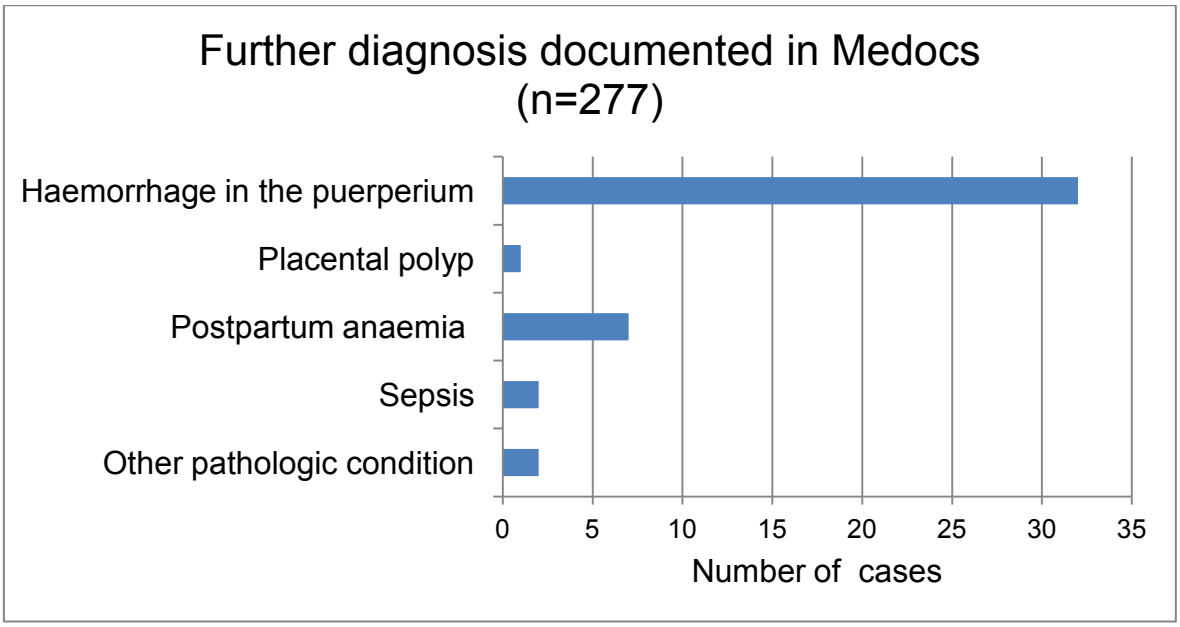

Figure 22: Further diagnosis documented in MEDOCS

4.4 Treatment

After making the diagnosis of anomaly of placental separation, several different measures were taken at the Division of Obstetrics and Maternal Fetal Medicine at the Medical University of Graz (*Figure 23*). It has to be mentioned that in a number of cases more than one treatment in succession was performed. In 19 cases (6.9%) there was no documentation of such treatment found in either MEDOCS or ViewPoint health records. In 108 cases (39.0%) the medication of Syntocinon® and Buscopan® was given in order to induce or maintain uterine contractions. The majority of 222 patients, which accounts for 80.1%, were treated with manual removal of the placenta. In 48 cases (17.3%) an instrumental removal (D&C) was carried out. 32 women (11.6%) had a successful cord traction manoeuvre performed. 4 patients underwent hysteroscopy (HSC), which is 1.4%. In 2 women (0.7%) the measure of laparoscopy (LSC) was taken.

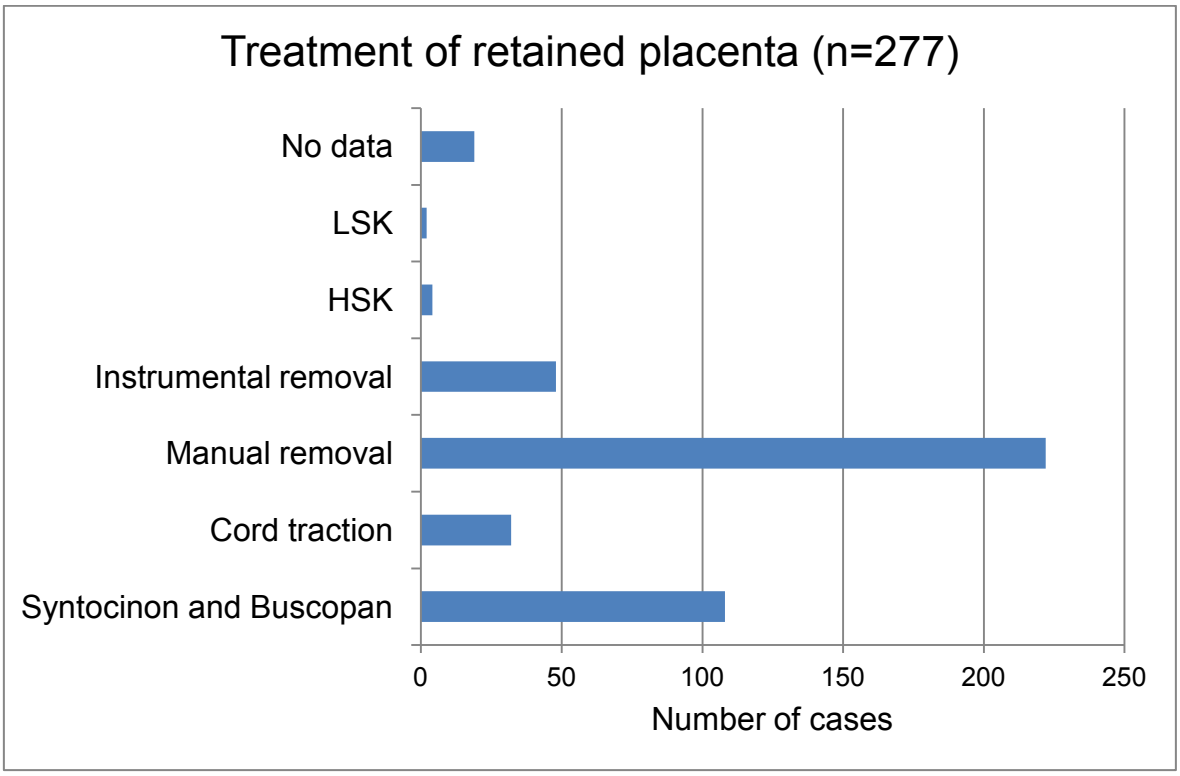

Figure 23: Treatment of retained placenta

252 patients had their treatment carried out on the day of their delivery, which accounts for a majority of 91.0% (*Figure 24*). 25 women (9.0%) were treated within a range of 1 to over 11 weeks postpartum. It has to be mentioned that 3 women were treated twice within the period, which was again neglected and analysed as individual cases.

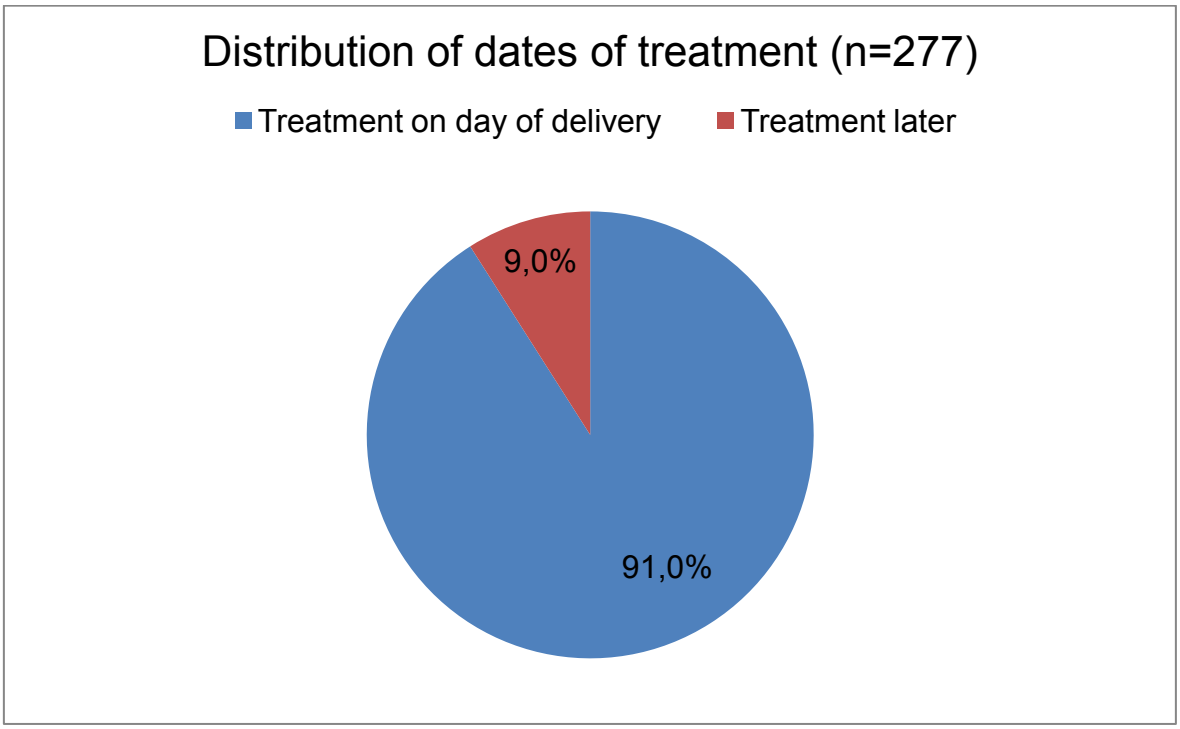

Figure 24: Distribution of dates of treatment

7 of the patients, who had their treatment later, were treated within the first week after their delivery (25.0%)(*Figure 25*). 6 women got their therapy in the fifth week (21.4%) and 3 women in their seventh week postpartum (10.7%). 2 patients were treated in their third, sixth, ninth and eleventh week after their delivery respectively (7.1%). 1 patient got her treatment in her second, eighth, tenth or after the eleventh week postpartum respectively (3.6%). Interestingly, none of the patients was treated in the fourth week postpartum.

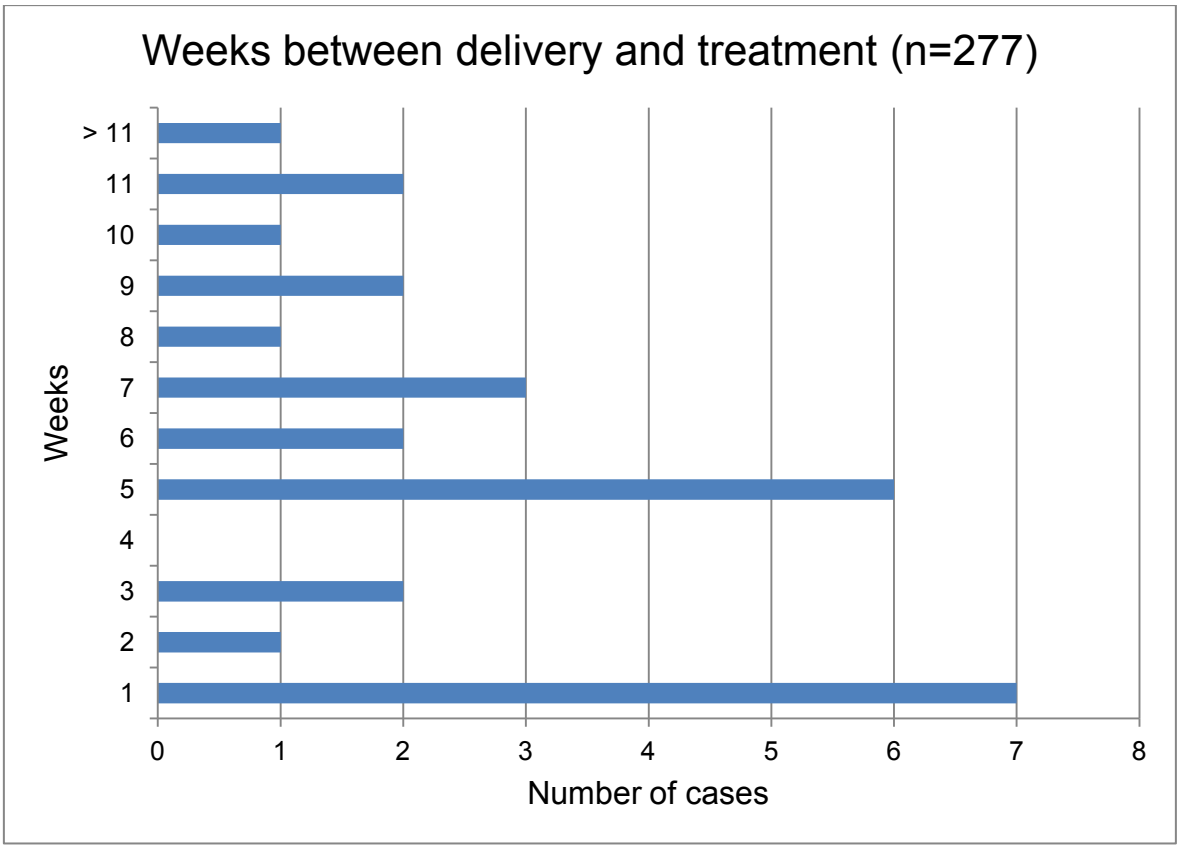

Figure 25: Weeks between delivery and treatment

4.5 Haemorrhage

The documentation of haemorrhage was analysed under two aspects. Firstly the subjective severity of haemorrhage postpartum in each case was investigated with the help of the electronic health record of ViewPoint Fetal Database which showed subjective description of the amount of blood loss with differentiation between moderate or severe blood loss (*Figure 26*). 235 women experienced moderate haemorrhage, which accounts for a majority of 84.8%. In 42 cases the amount of blood loss was higher, which is a percentage of 15.2% of severe haemorrhage.

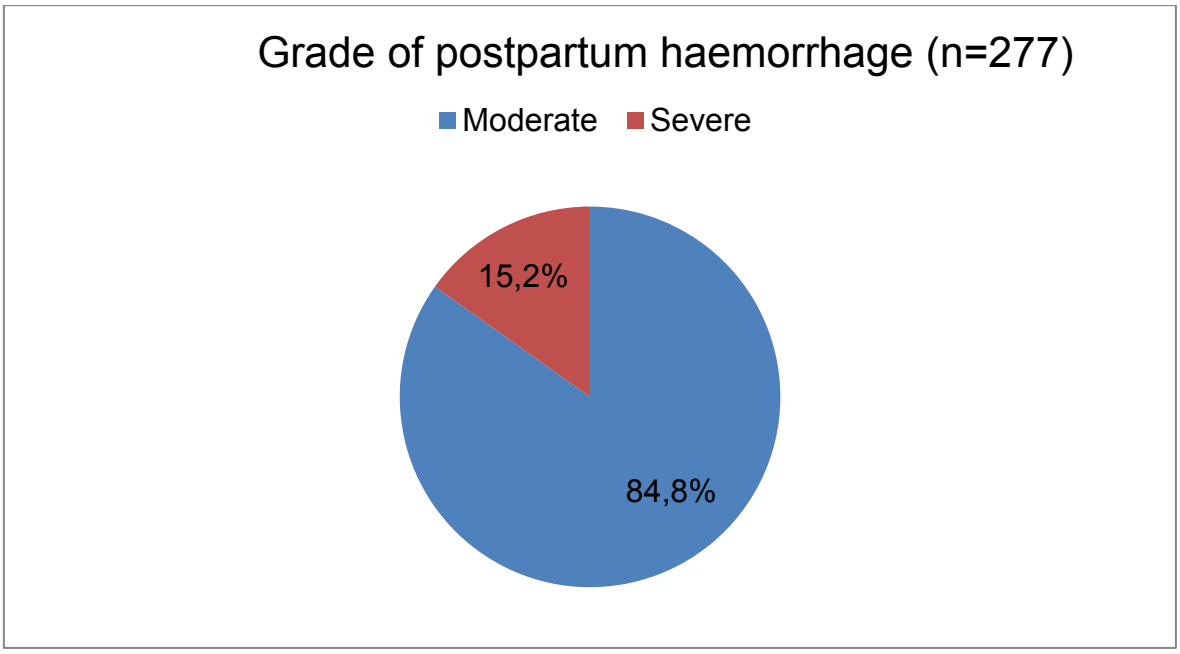

Figure 26: Grade of postpartum haemorrhage

6 of 42 cases with severe haemorrhage in accordance with the description of ViewPoint were treated with blood transfusions (14.3%)(*Figure 27*). The other 36 patients (85.7%) didn't receive any blood transfusions. In average 2 units of erythrocytes were given to the patients.

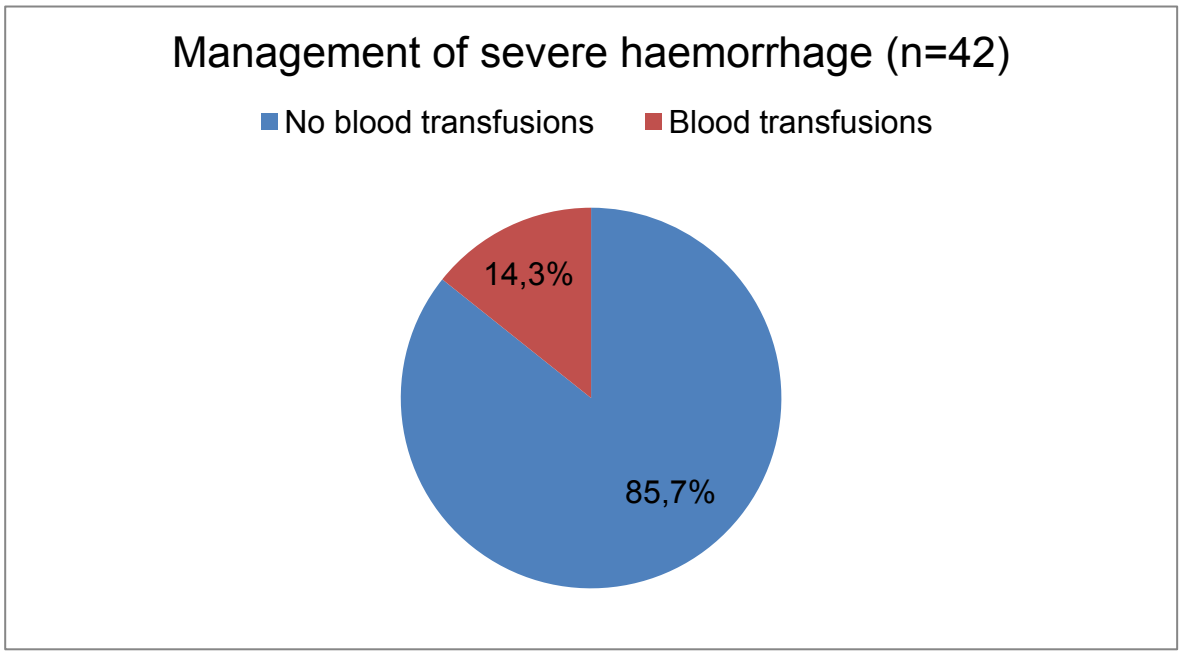

Figure 27: Management of severe haemorrhage

35 of the women with severe haemorrhage (83.3%) were advised to take oral iron substitution postpartum (*Figure 28*). In 7 cases (16.7%) no documentation about iron supplements was found. Documentation about parenteral iron supplementation was not found.

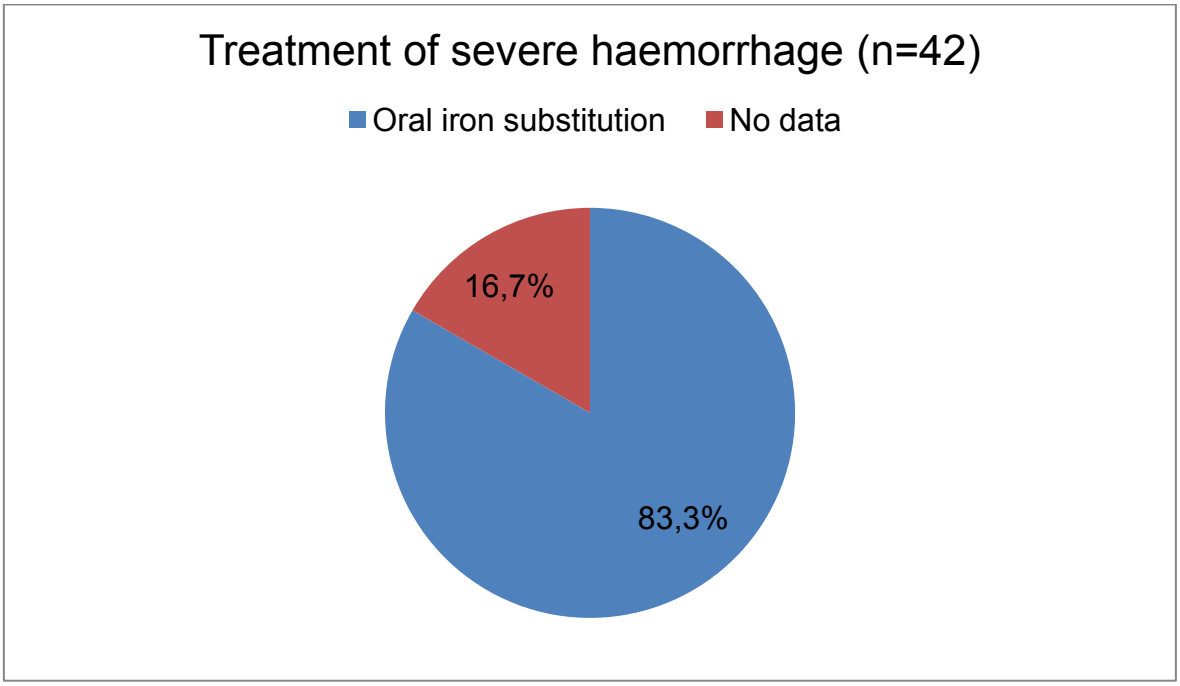

Figure 28: Treatment of severe haemorrhage

The second aspect was to investigate objectively the postpartum haemoglobin (Hb) count. The laboratory findings of postpartum Hb were taken from ViewPoint Fetal Database, or if not documented, from MEDOCS health record (*Figure 29*). In 59 cases (21.3%) no postpartum Hb was documented either in ViewPoint or MEDOCS health record.

161 patients had a postpartum Hb over 10 g/dl, which is a majority of 58.1%. 19 women showed a laboratory finding of postpartum Hb between 9.1 g/dl to 10 g/dl (6.9%). A postpartum Hb between 8.1 g/dl and 9 g/dl was measured in 15 cases (5.4%). 17 women had a postpartum Hb between 7 g/dl and 8 g/dl (6.1%). 6 patients showed a postpartum Hb lower than 7 g/dl (2.2%).

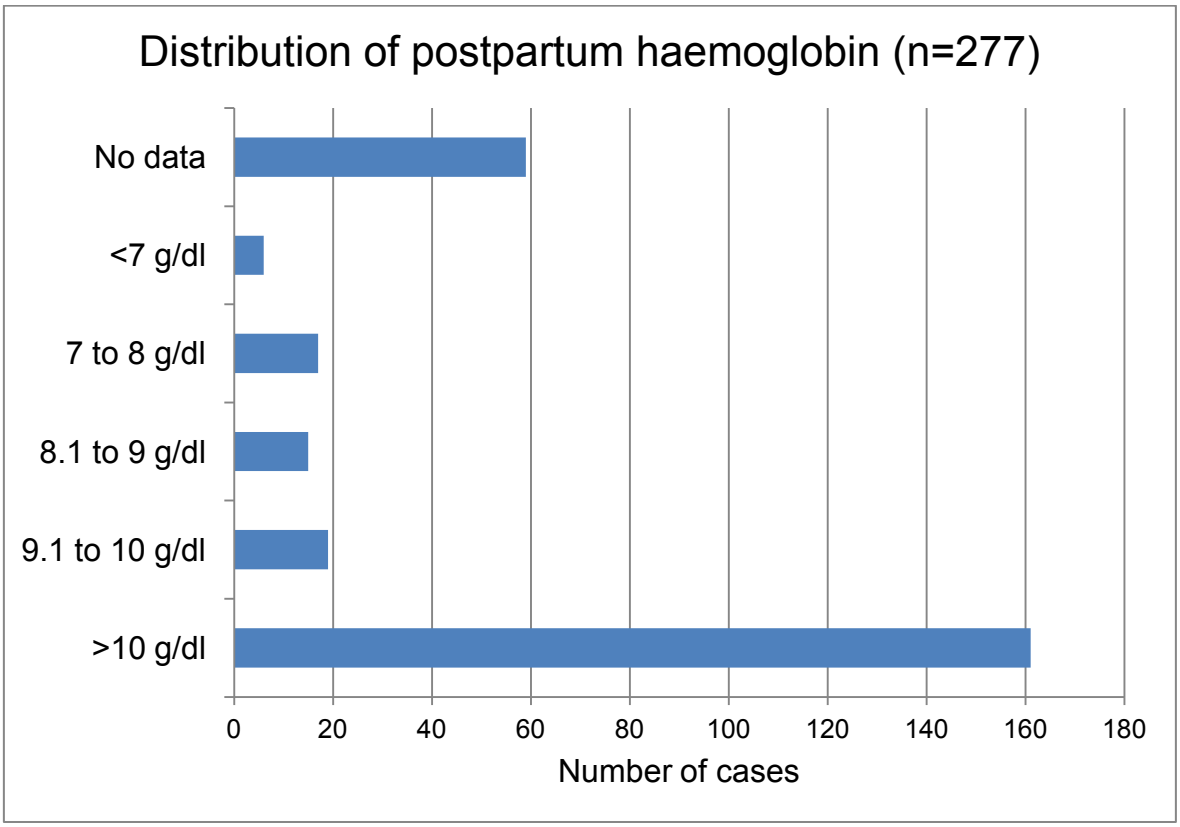

Figure 29: Distribution of postpartum haemoglobin

4.6 Postpartum anaemia

The distribution of postpartum Hb leads to the diagnosis of postpartum anaemia under 10 g/dl of Hb in 56 cases (20.2%)(*Figure 30*). 162 patients didn't suffer from postpartum anaemia as their postpartum Hb was higher than 10 g/dl (58.5%). Again in 59 cases (21.3%) there was no data available.

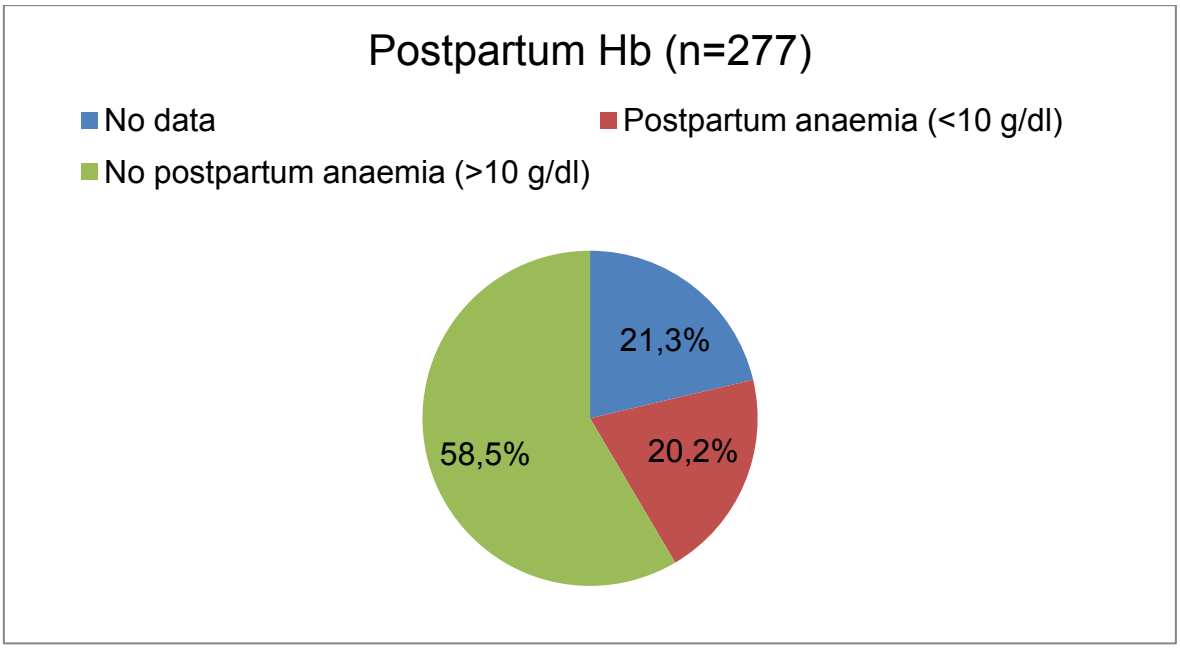

Figure 30: Postpartum Hb

In 11 of 56 cases with postpartum anaemia under 10 g/dl a therapy with blood transfusions was recommended (19.7%)(*Figure 31*), but only 9 patients actually received blood transfusions (16.1%), while 2 patients (3.6%) refused the therapy. The majority of 45 patients with a postpartum Hb count of less than 10 g/dl didn't get any blood transfusions (80.4%). Again in average 2 units of erythrocyte suspension were given to the patients.

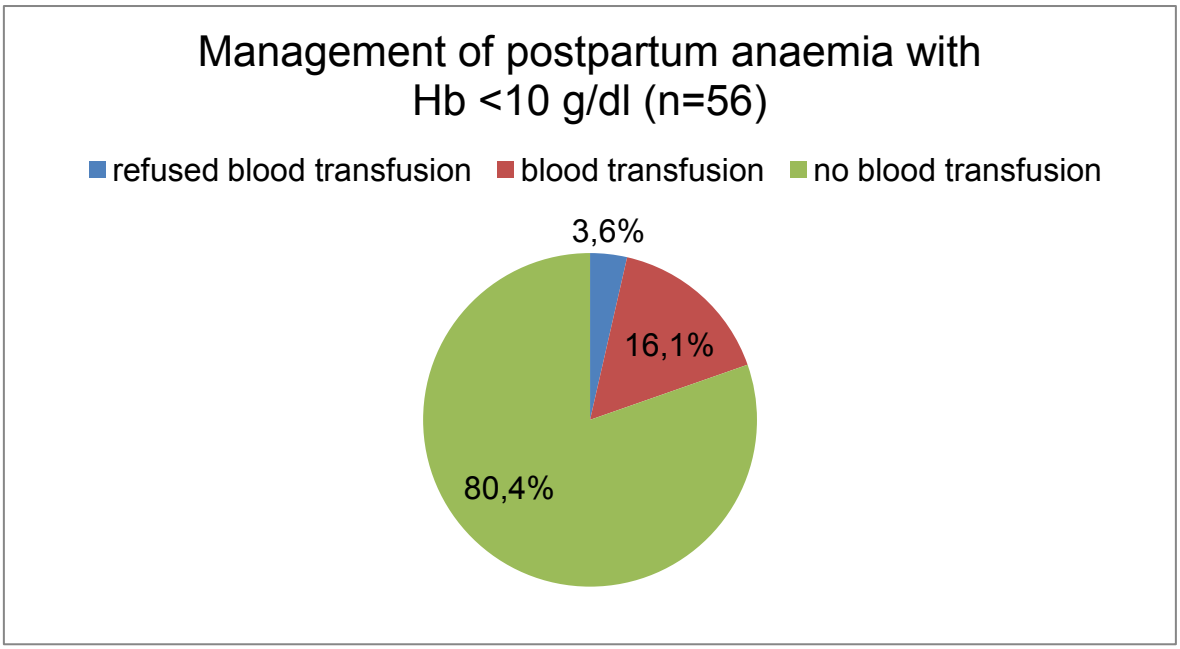

Figure 31: Management of postpartum anaemia with Hb <10 g/dl

In comparison, in 7 of 21 cases (33.4%) with severe postpartum anaemia with Hb under 8 g/dl blood transfusions were recommended (*Figure 32*). As 1 woman refused the therapy (4.8%), there were 6 patients, who actually received blood transfusions (28.6%). In 14 cases no blood transfusions were given (66.7%).

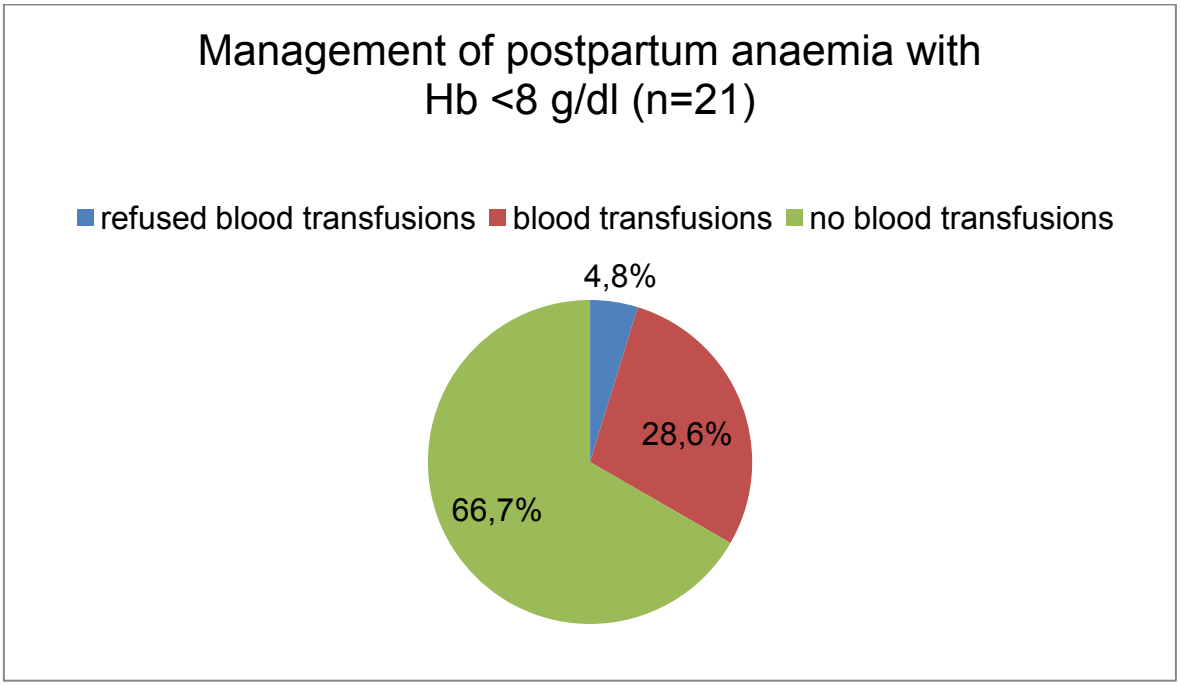

Figure 32: Management of postpartum anaemia with Hb <8 g/dl

From 42 cases with subjective severe haemorrhage in the electronic health record of ViewPoint Fetal Database 26 women (61.9%) indeed suffered from postpartum anaemia of under 10 g/dl Hb (*Figure 33*). However, 14 of 42 patients (33.3%) didn't show an Hb count lower than 10 g/dl and in 2 cases no postpartum Hb was documented (4.8%).

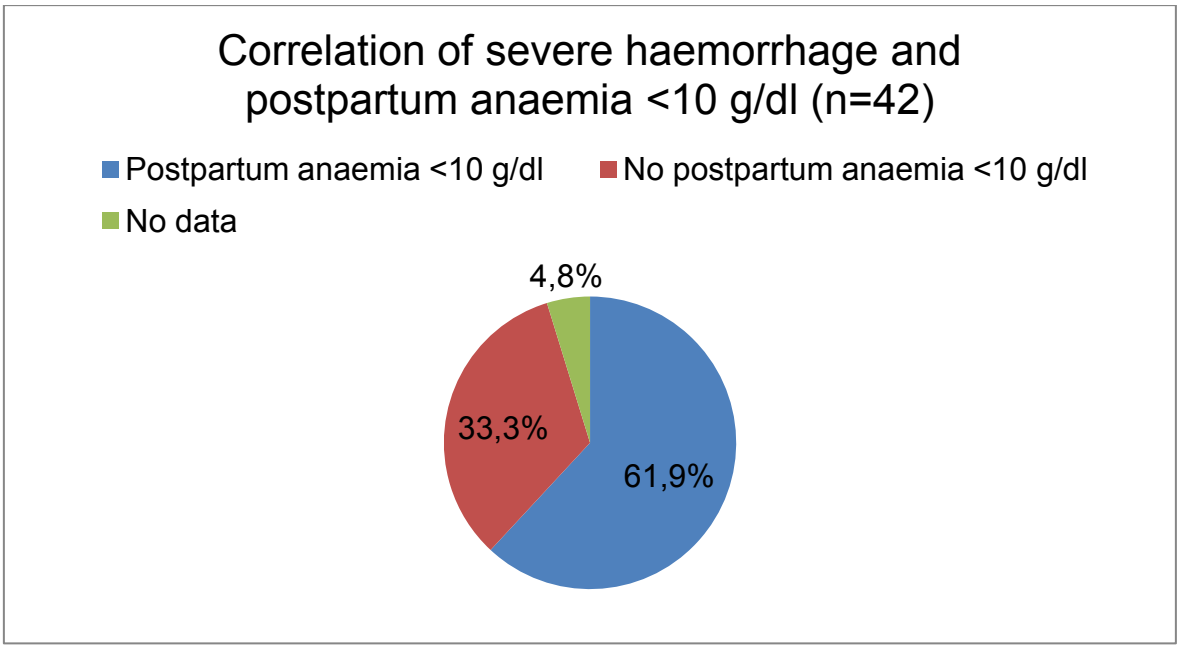

Figure 33: Correlation of severe haemorrhage and anaemia <10 g/dl

In 12 of 42 cases (28.6%) with subjective severe haemorrhage according to the electronic health record of ViewPoint Fetal Database, the diagnosis of severe postpartum anaemia of Hb count under 8 g/dl (*Figure 34*) could be verified. 28 patients didn't suffer from postpartum anaemia under 8 g/dl (66.7%). Again in 2 cases (4.8%) there was no documentation of postpartum Hb available despite the severe haemorrhage in the birth documentation.

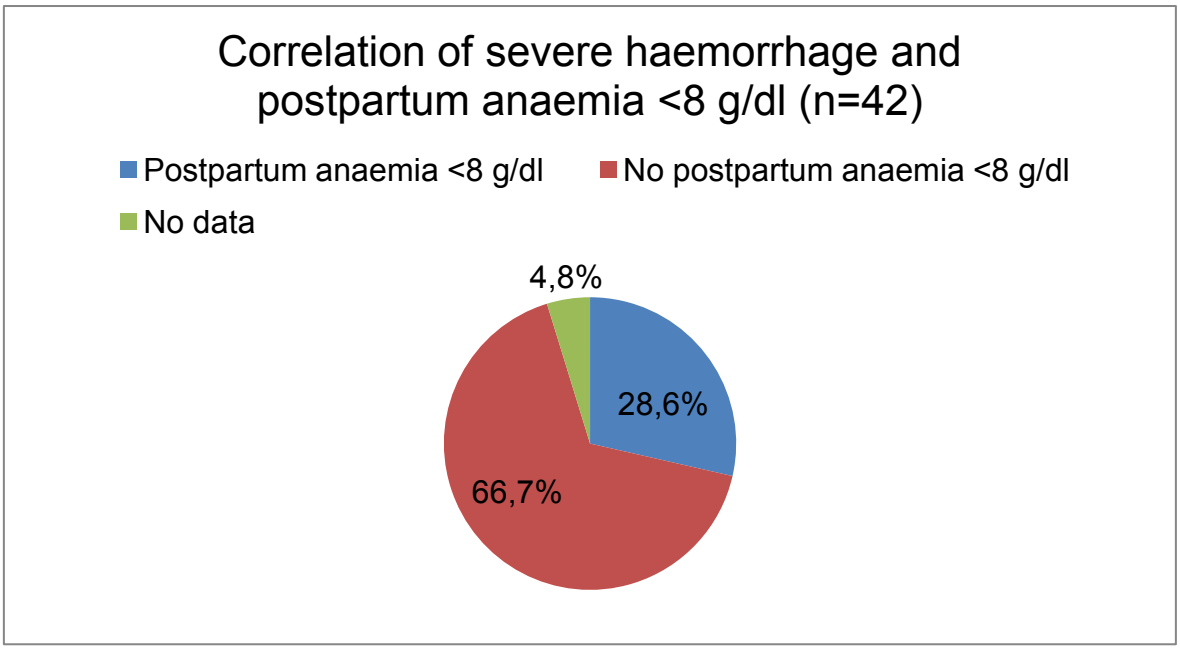

Figure 34: Correlation of severe haemorrhage and anaemia <8 g/dl

In 19 of 42 cases with subjective severe haemorrhage it was possible to compare the laboratory findings of praepartum and postpartum Hb (*Figure 35*). The highest decrease of Hb was 4.4 g/dl in two cases. In 1 case the Hb shows an increase of 0.1 g/dl.

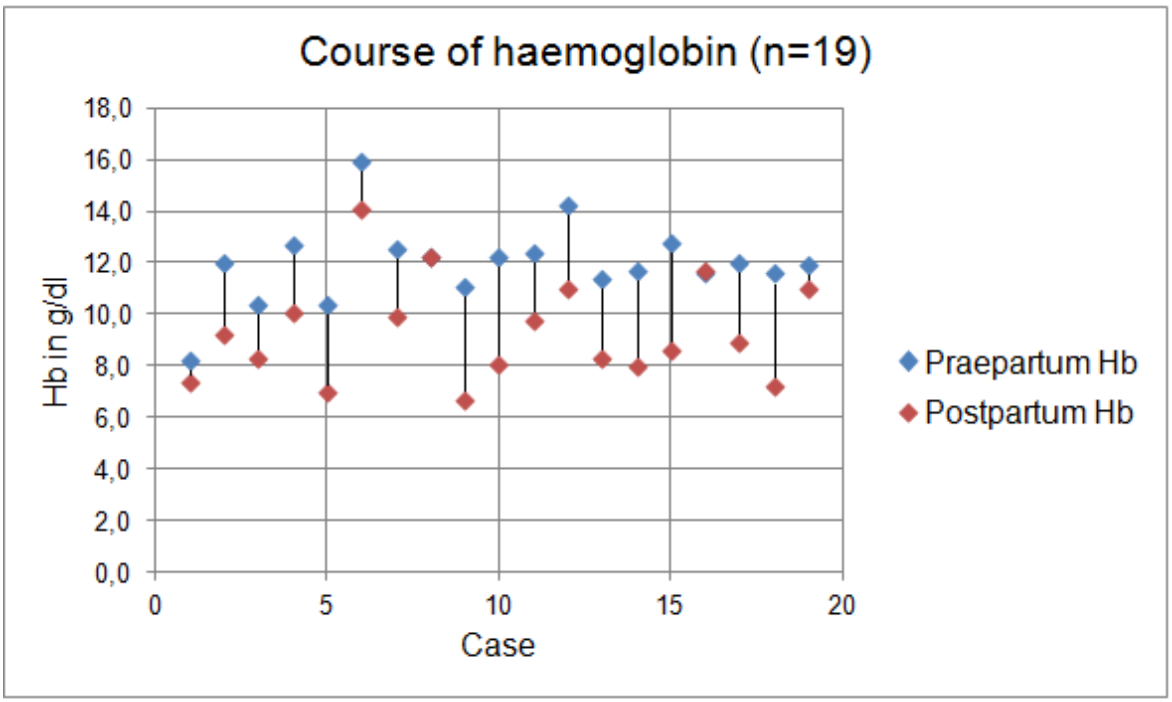

Figure 35: Course of haemoglobin

5 Discussion

None of the cases with residual placenta investigated in this study from 2003 to 2011 shows the actual diagnosis of ‘arteriovenous malformation of the uterus’ in the electronic health records. This is due to the fact that no abnormal vascular connection was proven by prae- or postpartum diagnostic methods. At least 42 of the patients did show symptoms, which would be compatible with the diagnosis of AVM. AVM primarily presents with bleeding complications, which can occur early or delayed in the postpartum period. This postpartum haemorrhage is more likely to happen after obstetrical complications like residual placenta and even more often after surgical interventions.

Therefore it’s not possible to completely exclude AVMs even without proof, although the diagnosis of AVM in the analysed cases will stay speculative. However it is important to bare in mind the possibility of the existence of AVM. Women with bleeding complications after delivery should be treated as high-risk in subsequent pregnancies as it might be possible that those complications reoccur in the following pregnancies. It would be a good idea if patients with a history of residual placenta and severe haemorrhage after surgical treatment should undergo Colour flow US in their future pregnancies, in order to detect possible vascular malformations in the uterus to interpret possible postpartum bleeding with the necessary caution.

The study corresponds to the current literature, AVMs certainly are a rare cause for obstetrical complications and so its relevance in the context of obstetric problems is put into question. In the analysed period of 8 years there was only a small number of severe complications due to residual placenta and postpartum surgical interventions. Also the amount of blood loss and number of diagnosed postpartum anaemia was kept within a limit.

The majority of cases with suspected AVMs of the uterus occurred in mature gestational age, and there was only one case with severe haemorrhage before the

24th week of pregnancy. More than one quarter of the studied cases were women over the age of 35 years, which might be another important epidemiologic factor. However, a woman of over 35 years shows a greater chance to have experienced previous obstetrical or surgical conditions and measurements, which also increases the risk to develop AVMs or a residual placenta. All the previous events identified in cases of the study have been reported in literature as possible risk factors for AVM.

Most of the cases of the study experienced residual placenta with bleeding complications during their first pregnancy and delivery. Summing up all cases showing the diagnosis after the first pregnancy and delivery, the outcome shows that residual placenta is more likely to occur after previous pregnancies and deliveries. The statistics show a lower number of cases in higher number of pregnancy or delivery, which is due to the fact, that we live in a society where it is more popular to have fewer children.

The outcome of the study with no death or necessity for hysterectomy shows the adequacy of the therapy given to the patients. In an absolute majority of cases the treatment was carried out on the same day of the delivery, so the diagnosis of residual placenta was soon revealed. Depending on the severity of complications, conservative measures like administration of medication for uterine contractions or surgery under general anaesthesia were taken. It was not necessary to take any further steps to control severe bleeding complications.

Cases with residual placenta didn't occur very often in the investigated period and in those detected cases the problem could nearly always be controlled with one single procedure and moderate blood loss. Only in 3 cases it was necessary to carry out a second measure.

About 20% of all patients with residual placenta in the period suffered from a postpartum anaemia with an Hb count of lower than 10 g/dl and about 8% showed an Hb count of lower than 8 g/dl. The standard therapy of anaemia is to give blood transfusions, which was recommended to about 20% of the patients with anaemia with an Hb count of lower than 10 g/dl and to about 33% of the patients with

anaemia with an Hb count of lower than 8 g/dl. At the Division of Obstetrics and Maternal Fetal Medicine at the Medical University of Graz the standard procedure in cases with an Hb count of lower than 8 g/dl is to offer the administration of erythrocyte suspension to the patient. The woman of course does not have to accept this and can refuse the therapy. This refusal is mostly documented in the handwritten patient charts/records and may not be copied into the electronic health records of the patient. For the study only electronic health records have been analysed. This is why it is possible, that the statistics show such a low percentage of women with an Hb count of lower than 8 g/dl, who actually received erythrocyte suspensions. In cases of emergency (unconsciousness, non-responding patient, massive haemorrhage) primary a selective blood substitution therapy is used (erythrocyte suspension, plasma concentrate, volume supplementation).

Another problem due to bleeding complications might be an iron deficiency. The majority of cases with severe haemorrhage in the study received oral iron supplements. Again in some cases no documentation was found about iron substitution at all, which might again be the problem of handwritten patient refusal, which was not included in the analysis. One reason for the decline of oral iron supplementation could be the high rate of gastroenterological side effects like diarrhoea, nausea or obstipation. In December 2010 an oral presentation about i.v. iron substitution was held by Prof. Christoph Gasche of the Medical University of Vienna at the Division of Obstetrics and Maternal Fetal Medicine at the Medical University of Graz (35). In his study he presents a new product for i.v. iron administration called Ferinject®. Women with an Hb count of lower than 10 g/dl within ten days postpartum received either i.v. iron supplementation of Ferinject® or oral iron supplementation of *iron sulphate.* Not only did the i.v. administration show less side effects than the oral one, it also showed a significant increase of their Hb count of more than 2 g/dl after two and four weeks, and a significant increase of 3 g/dl of Hb after two, four and seven weeks. It also shows that the iron stores have been filling up. In about 80% of the patients only one infusion of Ferinject® was given (35). At the Division of Obstetrics and Maternal Fetal Medicine at the Medical University of Graz since 2010 the i.v. iron supplementation of Ferinject® has gotten more and more popular due to the easy single administration and less side effects for the patients.

One problem of this retrospective study was the inconsistent and sometimes incomplete documentation in the patients' electronic health records. Handwritten patient charts have not been analysed at all. It was difficult to compare the results with a high number of undocumented details. The programs used for electronic documentation offer to much free space for the single examiner, so the same details revealed in different patients are documented in different spaces of the electronic health records. So it can easily be overlooked by a second examiner. For the future a more consistent documentation should be established, which requires training for all staff members working with those programs. This will not only guarantee a complete, homogenous patient record that can easily be continued to be used by every staff member, it will also be easier to compare different managements and outcomes.

To totally understand the problem of uterine AVM in the context of obstetrics it might be necessary to carry out prospective studies. Special attention should be given to possible vascular malformations in the praepartum period. The problem is of course that such detailed screening examinations of patients will take a lot of time and cost a lot of money, so it should be considered in cases with possible consequences of certain results.

Even though the complications of residual placenta in cases with suspected AVM of the uterus could be well controlled in the cases of the presented study, it is important to guarantee a detailed medical education of the patients. Women, especially those, who already suffered from bleeding complications after residual placenta, have to know about the entity and the chance that more than one clinical procedure might be necessary after their delivery. More clinical interventions might lead to even more haemorrhage, therefore a longer hospital stay, a longer recovery period and psychological stress.

AVMs of the uterus stay a rarity. However, they remain to be a risk factor for severe bleeding complications after delivery and especially after residual placenta followed by surgical intervention. The standard therapy seems to be adequate, but it is important to know, that arteriovenous malformations could as well lead to uncontrollable haemorrhage and therefore should be kept in mind.

6 References of the text

(1) Hafferl A. Lehrbuch der topographischen Anatomie. 2nd ed. Berlin, Göttingen, Heidelberg: Springer Verlag oHG; 1957. p. 614-45.

(2) Rauber A, Kopsch F. Anatomie des Menschen. Lehrbuch und Atlas. Band II: Innere Organe. Stuttgart: Georg Thieme Verlag; 1987. p. 487-540.

(3) Gray H. Gray's anatomy. London: The Promotional Reprint Company Limited; 1997. p. 378-688.

(4) Stauber M, Weyerstahl T. Duale Reihe. Gynäkologie und Geburtshilfe. 3rd ed. Stuttgart: Georg Thieme Verlag KG; 2007. p. 463-743.

(5) Schünke M, Schulte E, Schumacher U. Prometheus. LernAtlas der Anatomie. Hals und Innere Organe. Stuttgart: Georg Thieme Verlag; 2005. p. 244-93.

(6) Gilroy AM, MacPherson BR, Ross LM. Atlas of Anatomy. New York: Thieme Medical Publishers, Inc; 2008. p. 94-5.

(7) Gruber S. Basics. Gynäkologie und Geburtshilfe. 3rd ed. München: Elsevier GmbH; 2009. p. 146-7.

(8) Dudenhausen JW. Praktische Geburtshilfe mit geburtshilflichen Operationen. 20th ed. Berlin: Walter de Gruyter GmbH & Co KG; 2008. p. 187-382.

(9) Noonan JB, Coakley FV, Qayyum A, Yeh BM, Wu L, Chen LM. MR imaging of retained products of conception. AJR Am J Roentgenol. 2003 Aug;181(2):435-9.

(10) Bodelon C, Bernabe-Ortiz A, Schiff MA, Reed SD. Factors associated with peripartum hysterectomy. Obstet Gynecol. 2009 Jul;114(1):115-23.

(11) Mahendru R, Taneja BK, Malik S. Preservation of fertility following abnormally adherent placenta treated conservatively: a case report. Cases J. 2009 Dec 18;2:9349.

(12) Thia EWH, Lee SL, Tan HK, Tan LK. Ultrasonographical features of morbidly-adherent placentas. Singapore Med J. 2007 Sept;48(9):799-802.

(13) Mulic-Lutvica A, Axelsson O. Ultrasound finding of an echogenic mass in women with secondary postpartum hemorrhage is associated with retained placental tissue. Ultrasound Obstet Gynecol. 2006 Sept;28(3):312-9.

(14) Debby A, Malinger G, Harow E, Golan A, Glezerman M. Transvaginal ultrasound after first-trimester uterine evacuation reduces the incidence of retained products of conception. Ultrasound Obstet Gynecol. 2006 Jan;27(1):61-4.

(15) Manolitsas T, Hurley V, Gilford E. Uterine arteriovenous malformation- a rare cause of uterine haemorrhage. Aust NZ J Obstet Gynaecol. 1994 May;34(2):197-9.

(16) Khatree MH, Titiz H. Medical treatment of a uterine arteriovenous malformation. Aust NZ J Obstet Gynaecol. 1999 Aug;39(3):378-80.

(17) Hoffman MK, Meilstrup JW, Shackelford DP, Kaminski PF. Arteriovenous malformations of the uterus: an uncommon cause of vaginal bleeding. Obstet Gynecol Surv. 1997 Dec;52(12):736-40.

(18) Gulati MS, Paul SB, Batra A, Sarma D, Dadhwal V, Nath J. Uterine arteriovenous malformations: the role of intravenous ‘dual-phase’ CT angiography. Clin Imaging. 2000 Jan-Feb;24(1):10-4.

(19) Fleming H, Östör AG, Pickel H, Fortune DW. Arteriovenous malformations of the uterus. Obstet Gynecol. 1989 Feb;73(2):209-14.

(20) Kelly SM, Belli AM, Campbell S. Arteriovenous malformation of the uterus associated with secondary postpartum hemorrhage. Ultrasound Obstet Gynecol. 2003 Jun;21(6):602-5.

(21) Rangarajan RD, Moloney JC, Anderson HJ. Diagnosis and nonsurgical management of uterine arteriovenous malformation. Cardiovasc Intervent Radiol. 2007 Nov-Dec;30(6):1267-70.

(22) Nicholson AA, Turnbull LW, Coady AM, Guthrie K. Diagnosis and management of uterine arterio-venous malformations. Clin Radiol. 1999 Apr;54(4):265-9.

(23) Aziz N, Lenzi TA, Jeffrey RB Jr, Lyell DJ. Postpartum uterine arteriovenous fistula. Obstet Gynecol. 2004 May;103(5 Pt 2):1076-8.

(24) Kwon JH, Kim GS. Obstetric iatrogenic arterial injuries of the uterus: diagnosis with US and treatment with transcatheter arterial embolization. Radiographics. 2002 Jan-Feb;22(1):35-46.

(25) Polat P, Suma S, Kantarcý M, Alper F, Levent A. Color Doppler US in the evaluation of uterine vascular abnormalities. Radiographics. 2002 Jan-Feb;22(1):47-53.

(26) Ahn HY, Park IY, Lee G, Kim SJ, Shin JC. Uterine arteriovenous malformation. Arch Gynecol Obstet. 2005 Feb;271(2):172-5.

(27) Clarke MJ, Mitchell PJ. Uterine arteriovenous malformation: a rare cause of uterine bleeding. Diagnosis and treatment. Australas Radiol. 2003 Sept;47(3):302-5.

(28) Timmerman D, Wauters J, Van Calenbergh S, Van Schoubroeck D, Maleux G, Van Den Bosch T, Spitz B. Color Doppler imaging is a valuable tool for the diagnosis and management of uterine vascular malformations. Ultrasound Obstet Gynecol. 2003 Jun;21(6):570-7.

(29) Gopal M, Goldberg J, Klein TA, Fossum GT. Embolization of a uterine arteriovenous malformation followed by a twin pregnancy. Obstet Gynecol. 2003 Oct;102(4):696-8.

(30) Yokomine D, Yoshinaga M, Baba Y, Matsuo T, Iguro Y, Nakajo M, Douchi T. Successful management of uterine arteriovenous malformation by ligation of feeding artery after unsuccessful uterine artery embolization. J Obstet Gynaecol Res. 2009 Feb;35(1):183-8.

(31) Delotte J, Chevallier P, Benoit B, Castillon JM, Bongain A. Pregnancy after embolization therapy for uterine arteriovenous malformation. Fertil Steril. 2006 Jan;85(1):228.

(32) Schwärzler P. Department of Obstetrics and Gynecology Feldkirch, Austria. Personal communication. 2011.

(33) Nasu K, Nishida M, Yoshimatsu J, Narahara H. Ectopic pregnancy after successful treatment with percutaneous transcatheter uterine arterial embolization for congenital uterine arteriovenous malformation: a case report. Arch Gynecol Obstet. 2008 Aug;278(2):171-2.

(34) Knight M, Callaghan WM, Berg C, Alexander S, Bouvier-Colle MH, Ford JB et al. Trends in postpartum hemorrhage in high resource countries: a review and recommendations from the International Postpartum Hemorrhage Collaborative Group. BMC Pregnancy Childbirth. 2009 Nov 27;9:55.

(35) Gasche C. Iron deficiency in gynecology. Department of Gastroenterology of the Medical University of Vienna. Oral presentation at the Medical University of Graz. Dec 2010.