

Diploma Thesis

**RECONSTRUCTION OF THE EARLOBE AFTER
PIERCING OR STRETCHING.**

**Literature review and analysis of currently available
methods.**

submitted by
Julia Maria Wimbauer

to attain the academic degree

**Doctor medicinae universae
(Dr. med. univ.)**

at the
Medical University of Graz

conducted at the
Department of Plastic, Aesthetic and Reconstructive Surgery

under supervision of
Dr. Martin Grohmann

and
Univ. Prof. Dr. Michael Schintler

Graz, October 2016

1. Statutory declaration

I declare on my honor that I have written the present work independently and without any help from others, that I have not used any other sources than the sources indicated, and that the sources used have been marked as such.

Graz, October 2016

Julia Maria Wimbauer eh

2. Acknowledgements

First of all I would like to express my gratitude to my supervisors, Dr. Martin Grohmann and Univ. Prof. Dr. Michael Schintler, who were always available when problems or questions of all sorts appeared and whose support was outstanding from the beginning.

Moreover, special thanks to all my friends and study colleagues who encouraged me during my whole study at the Medical University.

Finally, I would like to thank my parents, grandparents and siblings for all their love and support during and far beyond medical study.

3. Table of contents

1. Statutory declaration	2
2. Acknowledgements	3
3. Table of contents	4
4. Figure Legends	5
5. Tables	7
6. Summary (Abstract German)	8
7. Abstract English	9
8. Introduction	10
8.1. Basics.....	12
8.1.1. Overview and classification.....	12
8.1.1.1. External ear.....	13
8.1.1.1.1. Anatomy of the external ear.....	13
8.1.1.1.1.1. Eardrum.....	13
8.1.1.1.1.2. External auditory canal.....	14
8.1.1.1.1.3. Auricle.....	15
8.1.1.1.2. Vessels of the auricle and external auditory canal.....	17
8.1.1.1.3. Nerves of the auricle and external auditory canal.....	19
8.1.1.1.4. Muscles and ligaments of the auricle.....	20
8.1.1.1.5. Lymph drainage.....	22
8.1.1.1.6. Development of the external ear.....	22
8.1.1.1.7. Development of malformations of the external ear.....	23
8.1.1.1.8. Anthropometry of the auricle.....	24
9. Methods	25
10. Discussion	50
11. References	51

4. Figure Legends

Figure 1	Arterial blood supply of the anterior (a) and posterior (b) auricular surface.....	18
Figure 2	Sensory supply of the anterior (a) and posterior (b) auricular surface.....	19
Figure 3	Muscles and ligaments of the anterior (a) and posterior (b) auricular surface.....	21
Figure 4	Development of the auricle.....	23
Figure 5	Flowchart of the literature review process.....	27
Figure 6	a. Chalazion clamp, b. Skin hook and sterile tongue blade.....	29
Figure 7	a,b. Excision and closure with simple stitches, c. Use of a punch biopsy tool instead of a scalpel blade.....	30
Figure 8	Purse string.....	31
Figure 9	Method by Grohmann.....	32
Figure 10	Heart shaped earlobe.....	33
Figure 11	Multiple wedge excision.....	34
Figure 12	Reconstruction with L-plasty.....	35
Figure 13	Reconstruction with a bi-lobed flap.....	36
Figure 14a	Single wedge excision of excess earlobe tissue.....	37

Figure 15	Z-plasty to avoid heart shaped earlobe.....	38
Figure 16	Reconstruction by Bastazini.....	39
Figure 17	Reconstruction by Williams.....	40
Figure 18	Reconstruction by Arasaratnam.....	41
Figure 19	Method by Snell.....	42
Figure 20	Method by Zeiderman et al.....	44
Figure 21	Split earlobe repair.....	45
Figure 22	Small Z-plasty to avoid a linear scar.....	46
Figure 23	Method described by Collins.....	47
Figure 24	Method described by Sharma.....	48
Figure 25	Method for large defects described by Collins.....	49

5. Tables

Table 1 Overview of the available and described techniques

6. Summary (Abstract German)

Hintergrund: Die Dehnung des Ohrläppchens und das daraus resultierende Entstehen von Fleischtunnel sind heutzutage ein trendiges Merkmal zur Körpermodifikation. Ist eine Rekonstruktion des Ohrläppchens erforderlich, kann das Erreichen einer anatomischen Wiederherstellung aufgrund der beachtlichen Größe des Defektes herausfordernd sein. Die Zielsetzung dieser Arbeit ist es, einen Überblick über die verschiedenen chirurgischen Herangehensweisen für den Wiederaufbau des beschädigten Ohrläppchens, verursacht durch dessen Dehnung, zu geben.

Methodik: Eine umfassende Literaturrecherche wurde mit den Datenbanken MEDLINE und PubMed durchgeführt. Zusätzlich wurde eine neue Sammlung von chirurgischen Methoden zur Rekonstruktion des Ohrläppchens analysiert. Alle gängigen Operationstechniken wurden zusammengefasst und ergänzend Zeichnungen der einzelnen Methoden angefertigt.

Ergebnisse: Es wurden insgesamt sechzehn verschiedene chirurgische Ansätze gefunden und beschrieben. Die besonderen Vorteile der einzelnen Verfahren wurden evaluiert und ergänzend exemplarische Zeichnungen der komplexen rekonstruktiven Techniken angefertigt.

Schlussfolgerung: Zusammenfassend lassen sich die meisten Defekte des Ohrläppchens operativ im ambulanten Bereich rekonstruieren. Die geeignete Operationstechnik sollte basierend auf der Erfahrung des jeweiligen Chirurgen und der Größe des Defektes gewählt werden. Vernarbung kann zu unangenehmen Missbildungen führen.

7. Abstract English

Background: Earlobe stretching and the resulting emergence of flesh tunnels are nowadays a trendy type of body modification. In case a reconstruction of the earlobe is required, the achievement of an anatomical reconstruction can be challenging due to the considerable size of the defect. The aim was to give an overview of the different surgical approaches for the reconstruction of the damaged earlobe caused by stretching.

Methods: A comprehensive literature review was performed including MEDLINE and PubMed databases. In addition, a new collection of surgical methods for earlobe reconstruction was analyzed. All commonly used surgical techniques were summarized and drawings of each method were performed.

Results: A total of sixteen different surgical approaches were found and described. Drawings of complex reconstructive techniques were performed and special benefits of each method were highlighted.

Conclusion: In summary, most earlobe defects can be reconstructed in an outpatient setting. Based on the surgeons' experience and the size of the defect each physician has to choose the appropriate surgical technique. Scarring may lead to unpleasant deformities.

8. Introduction

Body modification is a universal art form that has been practiced for thousands of years and can be defined as temporary or permanent alteration of parts of the human body, which includes procedures such as tattooing or body piercing. (1,2) It is done for motivations such as religious or mystical affiliations, shock value, sexual enhancement, aesthetic reasons, denoting affiliation, trust, loyalty and self-expression. (3)

One of the oldest piercing techniques, the labret piercing, has been performed by ancient cultures all over the globe. Aztecs and Mayans commonly performed this method, which was reserved for male members from higher castes. (4) Piercing of cheek, tongue or lips was a traditional practice in Chinese and Hindu cultures as well. (5,6) Beside these ancient piercing techniques, piercings and body modifications due to religious and cultural motivations can be also seen today. The Makololo tribe of Malawi (Africa) female members is still wearing lip plates called “Pelele” for beauty and sexual reasons. (7) In India, Sri Lanka and Malaysia, sadhus (ascetics) place temporary piercings through their cheeks or tongue for ritual, mystical reasons or for their documentation of trance. (8) Nowadays, the western civilization is using “plugs”, to expand earlobe piercings and create large gauge flesh tunnels. Especially in the younger population these types of tunnels are seen as en vogue and trendy. Popular materials used for these plugs are glass and metal but more and more also plugs made of wood, plastic or bones are used. The common conical shape of the plug allows to be easily inserted.

The process of getting a flesh tunnel through the earlobe is piercing of the ear. After a waiting period of at least two months, which is recommended by most piercing studios, as a second step, the stretching or “gauging” of the earlobe piercing can be performed. This gauging procedure has to be performed gradually by slowly increasing the diameter in order to perform a continuous tension and stretching of the created tunnel. This tunnel will expand more and more over time, while using conical plugs is stepwise increasing the diameter. Another method is to gauge by replacing the “old” objects with larger gauge objects, which have an increased diameter. Those objects are widely known as plug, expander, taper or

stretcher. The gauge sizes usually start at 1.0 mm and increase in 0.5 to 1.0 mm steps up to a final diameter of several centimeters. With regards to the gauging procedure and the possibility of infections, the biggest risk is described by piercers as a “blow out”. This complication can be described as “eversion of the skin tunnel” out the back of the piercing, which happens if someone tries to stretch too quickly. This tissue trauma may cause permanent damage of the earlobe and leads further to dermal necrosis of that. Removal of the plug may cause cosmetically unpleasant deformations and ptosis of the earlobe as a result. Recreation of an aesthetically satisfying earlobe requires specific reconstructive methods. Depending on the gauged diameter of the pierced ear and the damaged shape of the earlobe, the reconstructive methods used can vary.

Obviously there is no review article available, which describes the various available reconstructive methods for correction of the pierced ear. Therefore, the aim of this work was to give an overview of the available methods and show up the different approaches for the surgical reconstruction of the damaged earlobe.

8.1. Basics

8.1.1. Overview, classification

The ear is divided into three sections:

1. External ear (auris externa)
2. Middle ear (auris media)
3. Internal ear (auris interna) (9)

The auris externa receives sound waves from the surrounding region with the auricle and transmits these waves into the external auditory meatus (meatus acusticus externus) to the eardrum (membrana tympanica). (9)

The auris media is located in the petrous part of the temporal bone (pars petrosa ossis temporalis) and consists of air-filled and mucous-lined spaces. These are connected to the epipharynx by the auditory tube (tuba auditoria). The tuba auditoria is the central space of the middle ear. It contains the three auditory ossicles: malleus (hammer), incus (anvil) and stapes. Through these, the sound is transmitted from the membrana tympanica (eardrum) to the fenestra ovalis (oval window) and from there on to the auris interna. (9,10) The cellulae mastoidae (mastoid cells) are secondary spaces that are connected to the main space. (9)

The internal ear is a bony labyrinth (labyrinthus osseus) in the pars petrosa ossis temporalis, whose cavities are filled with lymph fluid. (10) Developmentally and anatomically, the auris interna consists of two functionally different organs, including the organum cochleare (organ of hearing) and the organum vestibulare (equilibrium organ). (9)

8.1.1.1. External ear

The auris externa is divided into three sections:

1. Eardrum (membrana tympanica) as the medial border
2. External auditory meatus (meatus acusticus externus)
3. Auricle (auricula) (9)

8.1.1.1.1. Anatomy of the external ear

8.1.1.1.1.1. Eardrum

The membrana tympanica forms the medial boundary between the auris externa and the auris media, whereby the external auditory canal is separated from the tympanic cavity. It is a tendinous skin about 0.1 mm thick and composed of three layers: the outer skin (stratum cutaneum), the base layer (lamina propria) and the inner mucosa (stratum mucosum). (9)

When viewing within the ear (otoscopy), the eardrum appears pearl gray and round/oval in the healthy state. When viewed from the outside, a funnel-shaped retraction is seen in the center. The innermost point of the involution forms the navel (umbo membranae tympanicae). (11) The umbo corresponds to the lower end of the hammer handle (manubrium mallei), which shines through the eardrum membrane as a light bone structure (stria mallearis), and runs anteriorly upwards to posteriorly downwards. At the upper end of the stria mallearis, the short process of the hammer forms the prominentia mallearis. From this projection, two folds (plica mallearis anterior and posterior) span a loose part of the eardrum, the shrapnell membrane (pars flaccida), upwards anteriorly and backwards posteriorly. The other part corresponds to the tense main part of the eardrum, the so-called pars tensa. The pars tensa can be divided by two imaginary lines into four quadrants, where portions of the auditory ossicles of the auris media appear in the posterior upper quadrant, the fourth quadrant. In the second quadrant, the anterior lower quadrant, light shining in produces a triangular light reflex, which

can be observed in the healthy eardrum. (9,10) A line along the hammer-handle makes the division, the other runs perpendicularly through the umbo membranae tympanicae.

Anchoring tissue of the membrana tympanica consists of a fibrous holding ring (anulus fibrocartilagineus), which is interrupted in the region of the pars flaccida and is embedded in a groove of the temporal bone (sulcus tympanicus of the os temporale). The tension of the membrana tympanica is regulated by the musculus tensor tympani, which attaches to the hammer.

The feeding vessels of the tympanic membrane are located on the inside and arise from the arteria tympanica anterior as well as from the arteria stylomastoidea, and run radially. On the outside, the vessels of the stria mallearis originate from the arteria auricularis profunda. Venous blood of the inner and outer sides of the membrana tympanica merges at the edge of the tympanic membrane, and is then transported via the vena meningea media, the venous plexus, and the bulbus venae jugularis. The nervous supply on the outer surface of the eardrum is the nervus auriculotemporalis and the ramus auricularis of the vagus nerve. The inner surface of the eardrum is supplied by the plexus tympanicus and sensory fibers of the nervus facialis and by sensory fibers of the nervus glossopharyngeus. (9)

8.1.1.1.2. External auditory canal

The meatus acusticus externus is an approximately 3.5 cm long S-shaped curved duct, which extends as far as the eardrum and is lined with skin. (9,10). The cartilaginous external auditory meatus (meatus acusticus externus cartilagineus) is separate from the bony external auditory meatus (meatus acusticus externus osseus). (9)

The cartilaginous part is connected by the connective tissue to the bony part of the duct, forming a trough-shaped continuation of the elastic auricular cartilage, which is supplemented by connective tissue and forms a closed duct. (11) The cartilage is penetrated in some places by holes and incisions, the so-called santorini columns. In these places, the cartilage is closed by connective tissue and thus achieves higher deformability of the external auditory canal.

The bony part is ellipsoidal in cross-section and extends in its longitudinal axis from the top posteriorly to the bottom anteriorly. (9)

The auditory canal of the adult is made up of cartilage in the outer (lateral) third and is padded with fat, connective tissue, and muscle. The remaining two internal (medial) thirds are bony and covered only by a thin skin. In children between five and six years of age, both the cartilaginous and the bony part are of equal length. In the one-year-old child, the cartilaginous portion accounts for two thirds, and only one third is bony.

The floor and the anterior wall of the meatus acusticus externus are formed by the pars tympanica. The thin front wall is attached directly to the fossa mandibularis (mandibular fossa) and is involved in the formation of the temporomandibular joint. The posterior wall of the external auditory canal is formed by the pars petrosa, and the pars squamosa of the temporal bone forms the roof. Both the posterior wall and the roof are bordered by air-filled spaces of the auris media, the cervical mastoid process (cellulae mastoideae), and the entrance cavity (antrum mastoideum).

The skin of the meatus acusticus externus is a continuation of the external skin. This is composed of a stratified, keratinized squamous epithelium, which is rich in sebaceous glands and hair in the cartilaginous part; this becomes sparser in the bony part, and is completely absent at the end. In the subcutis, the glands of the ear (glandulae ceruminosae et sebaceae) can be found; these lead into the hair follicles in children, and lie next to the hair follicles in adults. These large-lumen, tubulous, and apocryphal glands produce sebum, which forms the main component of earwax (cerumen). (9,10)

8.1.1.1.3. Auricle

The auricle is a funnel-shaped skin fold supported by an elastic cartilage (cartilago auricularis) and is variable in shape and size. The earlobe (lobulus auricularis) contains only adipose tissue, and cartilaginous support is absent. Through its crescent-shaped elevations and depressions, the auricle can better reflect sound waves coming from the environment, and guide them in the direction of the external auditory canal.

Each normal auricle has certain folds. The helix, which forms the rolled edge of the pinna, the smaller anterior edge (anthelix) within the helix with its y-form, and the tragus and antitragus at the anterior and inferior side of the entrance to the meatus acusticus externus, are of great importance for orientation (9,10) The conch-shaped choncha connect the anthelix with the cartilaginous external auditory canal. The fossa triangularis lies between the y-shaped beginnings of the anthelix. The end of the anthelix ends in the antitragus. Between the tragus and antitragus is the interstitial incisura. (12) The tragus represents a cartilaginous bulge anterior to the porus acusticus externus, and often features small hair follicles. (9,10) Developmentally, an additional bead, the so-called his-tuberculum, can occur above the tragus. In the upper part of the edge, there is also a small tubercle, the darwin tubercle, which extends toward the scapha. The posterior auricular surface is formed by the eminentia scaphae, the eminentia fossae triangularis, and the eminentia cavum conchae. In between is the sulcus anthelicis transversus, the fossa anthelicis, as well as the sulcus posterior. (12)

From the histological point of view, the auricle consists of a skin covering approximately 0.8 to 1.2 mm thick, which is firmly united with the connective tissue capsule of the cartilage (perichondrium) and does not allow slippage of the skin. The backside of the auricle, on the other hand, has an additional layer of fat between the skin and perichondrium, which makes the skin slippery. (12) The part of skin, which lies above the cartilage, contains sebaceous glands and ear-glands (cerebral glands). The thin secretions of the ceruminous glands together with tallow from the sebaceous glands and dead epithelial cells form cerumen. (13) At the entrance to the meatus acusticus externus, the so-called tragi (protective hair) are found, especially in the elderly. (9) The folded cartilage of the auricle (cartilago auricularis) is about 1.0 to 3.0 mm thick, and due to its firm consistency, forms the foundation of the auricula. (12) Cartilage tissue is composed of cartilage cells (chondrocytes) and extracellular matrix. The proteoglycans and collagen fibrils in the extracellular matrix lend the cartilage its pressure-elastic property, whereby the pinna can be deformed by pressure, and after release, immediately returns to its original shape. Since this cartilage, in contrast to hyaline cartilage and fibroid cartilage, contains additional matrix components made of elastic fibers, it is called elastic cartilage. (13)

8.1.1.1.2. Vessels of the auricle and external auditory canal

The arterial vascular supply of the auricula is made up of two arteries.

First from the arteria auricularis posterior, a branch of the arteria carotis externa, which supplies the auricle with blood from the caudal aspect, and second from the arteria temporalis superficialis (also a branch of the arteria carotis externa), which forms the arteriae auriculares anteriores at the front of the auricle. The arteries form anastomoses with each other. The meatus acusticus externus is additionally supplied by the arteria auricularis profunda. Venous blood is transported away from the anterior surface of the auricle via accompanying veins of the said arteries. Venous blood flows to the vena temporalis superficialis and the vena facialis into the vena jugularis interna. The posterior surface of the auricle releases its venous blood through the vena auricularis posterior into the vena jugularis externa. (9,12,14)

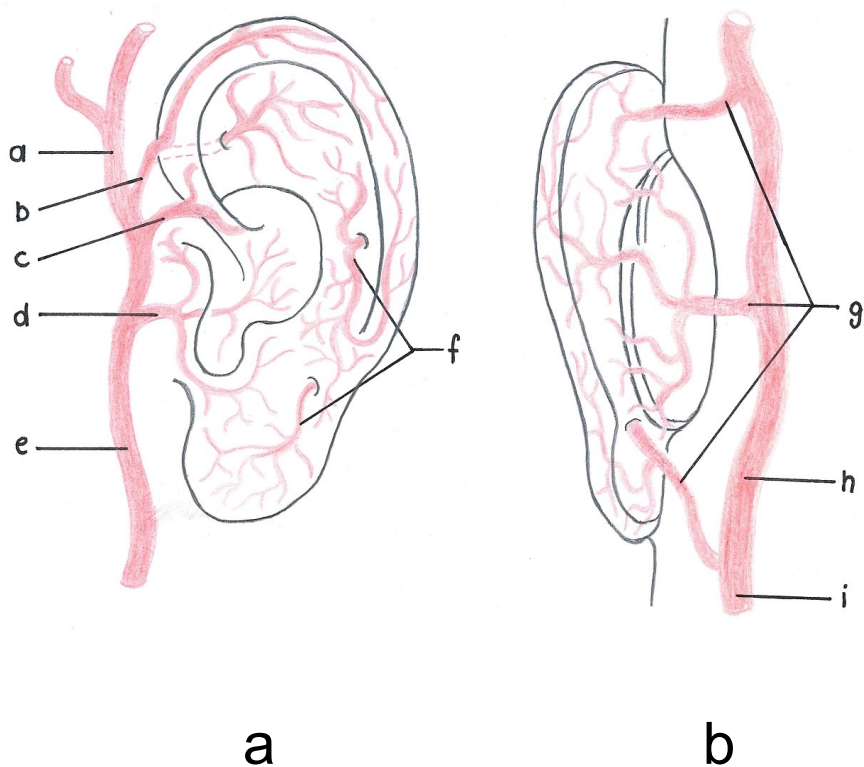


Figure 1: Arterial blood supply of the anterior **(a)** and posterior **(b)** auricular surface; depicted after Weerda 2007. (12)

- a)** Superficial temporal artery (*A. temporalis superficialis*)
- b)** Superior branch of the superficial temporal artery (*R. superior a. temporalis superficialis*)
- c)** Middle branch of the superficial temporal artery (*R. medialis a. temporalis superficialis*)
- d)** Inferior branch of the superficial temporal artery (*R. inferior a. temporalis superficialis*)
- e)** External carotid artery (*A. carotis externa*)
- f)** Perforating vessels (*Rr. perforantes*)
- g)** Perforating vessels (*Rr. perforantes*)
- h)** Posterior auricular artery (*A. auricularis posterior*)
- i)** External carotid artery (*A. carotis externa*)

8.1.1.1.3. Nerves of the auricle and the external auditory canal

The outer ear muscles are motor-innervated by the facial nerve (*nervus facialis*). The sensory innervation of the posterior surface of the auricle takes place through the great auricular nerve (*nervus auricularis magnus*) and the lesser occipital nerve (*nervus occipitalis minor*). The anterior surface, the anterior upper part of the external acoustic meatus (*meatus acusticus externus*), and the anterior upper part of the external surface of the tympanic membrane (*membrana tympanica*) are innervated by the *nervus auriculotemporalis* (auriculotemporal nerve).

The rami auriculares of the *nervus facialis*, the *nervus glossopharyngeus* (glossopharyngeal nerve), and the *nervus vagus* (vagus nerve) also partially innervate the external surface of the eardrum, the floor of the *meatus acusticus externus*, and the adjacent part of the external auditory canal. (9)

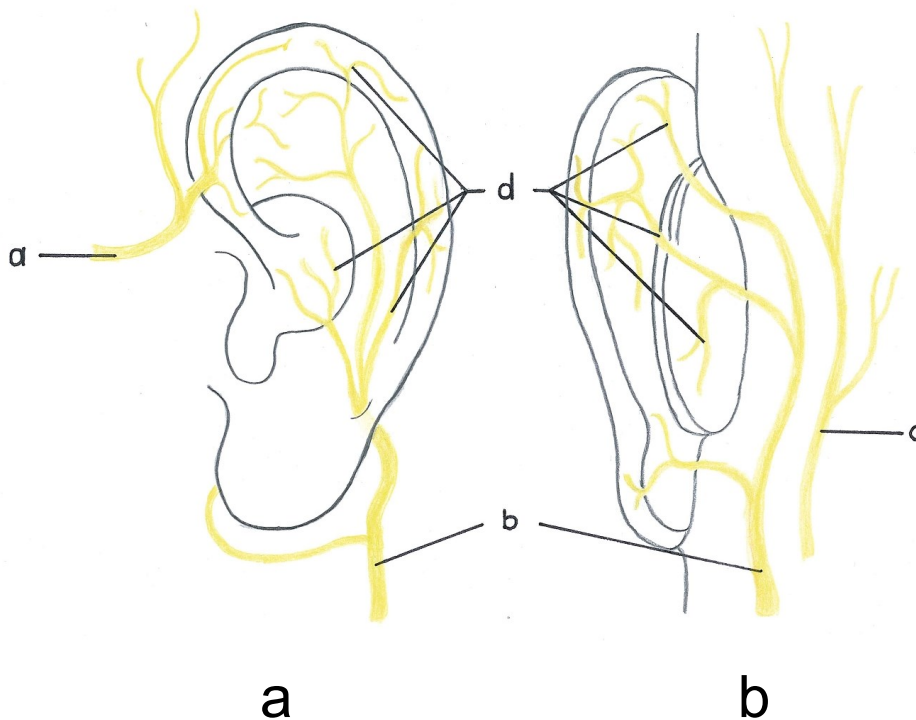


Figure 2: Sensory supply of the anterior (**a**) and posterior (**b**) auricular surface; depicted after Weerda 2007. (12)

- a) Auriculotemporal nerve (*N. auriculotemporalis*)
- b) Great auricular nerve (*N. auricularis magnus*)
- c) Lesser occipital nerve (*N. occipitalis minor*)
- d) Perforating vessels (*Rr. perforantes*)

8.1.1.1.4. Muscles and ligaments of the auricle

The auricle has two groups of muscles, both outer and inner muscles, these muscles being relatively unimportant and small. (9,14,15) The external muscles connect the head to the auricle and move them as a whole. These muscles include the musculus auricularis superior, the musculus auricularis anterior, as well as the musculus auricularis posterior. The upper auricular nerve (musculus auricularis superior) has its attachment to the aponeurosis epicranialis (galea aponeurotica) and pulls the auricle from above to pull it upwards. The anterior auricular muscle (musculus auricularis anterior) arises from the fascia temporalis, arrives at the spina helices of the auricle, and pulls anteriorly. The posterior auricular muscle (musculus auricularis posterior) pulls from the posterior, horizontal to the inner surface of the auricle, and serves the function of pulling the auricle backward. The internal muscles arise from the cartilaginous anterior and posterior surface of the auricula, and attach to it again. (9,14) These include, at the front of the auricle, the musculus helices major et minor, as well as the musculus tragicus et antitragicus. The musculus obliquus auriculae, the musculus transversus auriculae, as well as the musculus incisurae helices are found on the anterior side of the auricle. These small rudimentary muscles constitute the rest of the sphincter of the auricula externa. In some animals, the meatus acusticus externus can still be occluded, whereas in human, this function is practically irrelevant. (9)

The auricula is stabilized by the two anterior ligaments (ligamentum auriculare superius and ligamentum auriculare anterius), as well as by a posterior ligament (ligamentum auriculare posterius). (15)

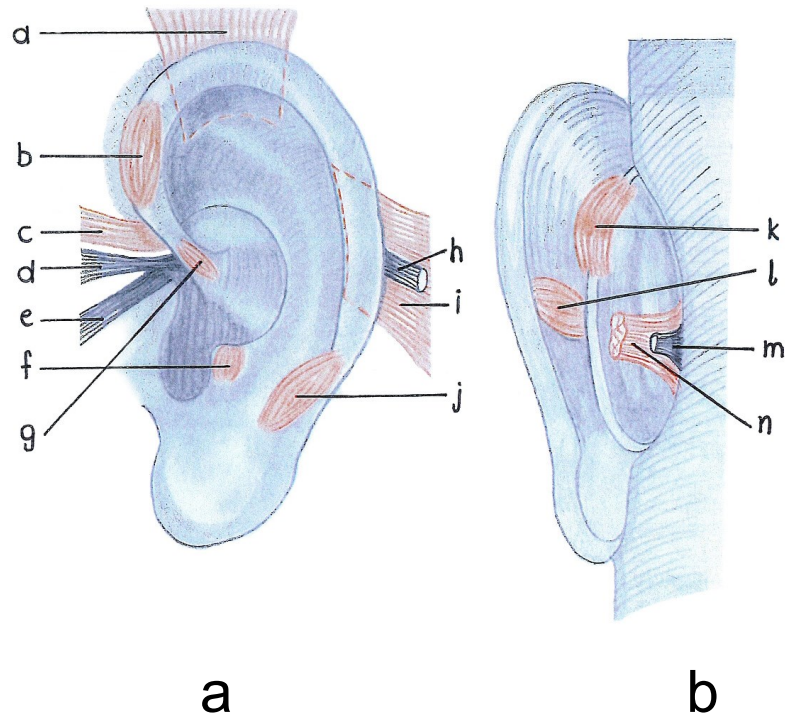


Figure 3: Muscles and ligaments of the anterior **(a)** and posterior **(b)** auricular surface; depicted after Weerda (2007). (12)

- a) M. auricularis superior (Superior auricular muscle)
- b) Helicis major muscle (M. helicis major)
- c) Anterior auricular muscle (M. auricularis anterior)
- d) Superior auricular ligament (Lig. auriculare superius)
- e) Anterior auricular ligament (Lig. auriculare anterius)
- f) Tragus muscle (M. tragicus)
- g) Helicis minor muscle (M. helicis minor)
- h) Posterior auricular ligament (Lig. auriculare posterius)
- i) Posterior auricular muscle (M. auricularis posterius)
- j) Antitragicus muscle (M. antitragicus)
- k) Obliquus auriculæ muscle (M. obliquus auriculæ)
- l) Transverse auricular muscle (M. transversus auriculæ)
- m) Posterior auricular ligament (Lig. auriculare posterius)
- n) Posterior auricular muscle (M. auricularis posterius)

8.1.1.1.5. Lymph drainage

Lymph drainage of the auricula and the cartilaginous meatus acusticus externus occurs preauricularly in the direction of the glandula parotidea, and postauricularly in the mastoid region. (12) The lymph vessels run even to the upper cervical lymph nodes, the nodi lymphatici cervicales laterales superficiales et profundi, as well as regional lymph nodes (nodi lymphatici parotidei superficiales et profundi, nodi lymphatici retroauriculares, and nodi lymphatici mastoidei). (9)

8.1.1.1.6. Development of the external ear

The equilibrium organs as well as the auditory organs constitute an anatomical unit. The external ear of the adult is divided into three parts (the auricle, the external auditory canal, and the eardrum), which develop from thickenings of the mesenchyme. These mesenchymal thickenings form the first and second branchial arches (mandibular and hyoid arches), which consist of six auricular depressions and are arranged circularly around the first branchial cleft.

In the development of the tympanic membrane, not only the first pharyngeal pouch is involved, but also the first branchial cleft, whereby the ectoderm of the first branchial cleft and the endoderm of the first pharyngeal pouch are joined. The first branchial cleft, with its dorsal portion, also forms the external auditory canal, as it protrudes inwards like a funnel-shaped tube.

At the beginning of the third month of development, the floor of the auditory canal is formed by the auditory canal. This results from proliferation of epithelial cells, which then dissolve in the seventh month of development and participate in development of the eardrum. If the auditory canal does not disintegrate in some cases until birth, congenital deafness results.

During the sixth week of development, the pinna is formed from the auricular depressions around the first branchial cleft. (9,16) The mesenchymal hillocks 1 to 3, originating from the mandibular arch, form the anterior part of the auricle. The mesenchymal hillocks 4 to 6, however, which originate from the hyoid arch, form the rear part of the auricle. (12)

Through the development of the lower jaw, the attachments of the auricle shift from the anterior and caudal position into their final posterior and cranial position at the level of the eyes. (12,16,17)

As soon as the seventh development week is reached, the mesenchyme of the mandibular arch is formed back to the fetal phase, whereby the mature ear ultimately consists of approximately 85% of the hyoid arch. (12,18)

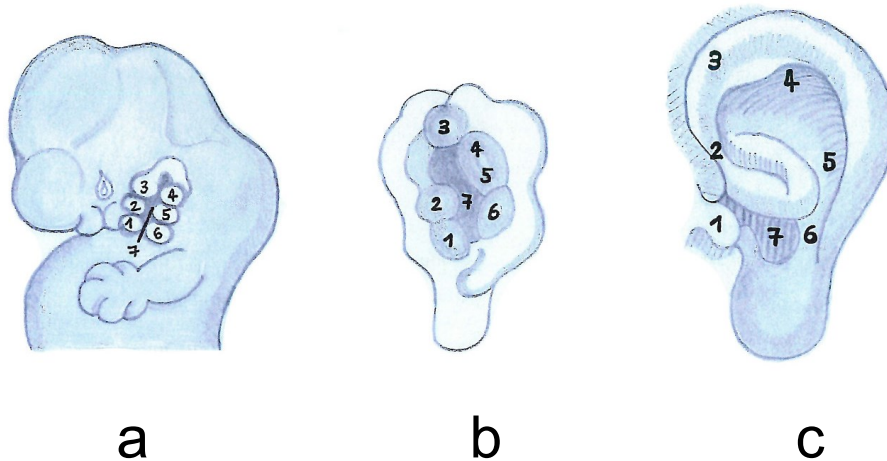


Figure 4: Development of the auricle: **a)** shows the position of the six auricular buds (hillocks) around the first branchial cleft and the position of the external ear compared to the lower jaw. By forming and enlarging the lower jaw, the auricle moves upwards in a rotary motion; 1)-6) hillocks, 7) first branchial cleft **b)** and **c)** illustrate fusion of the auricular hillocks and development of the auricle; depicted after Sadler 2008. (16)

8.1.1.1.7. Development of malformations of the external ear

Developmental and differentiation-inhibiting processes in some parts of the auditory system or in the area of the branchial cleft may potentially lead to variously differentiated malformations of the auricula. Malformations in the form of excess tissue, such as additional auricular appendages or cyst and fistula formation can also occur. (12)

8.1.1.1.8. Anthropometry of the auricle

Accurate knowledge of auricular anatomy plays an important role in the successful correctional, constructing, and reconstructing surgery of the auricula. The position and size of the auricle on the head is of decisive importance for individual operative planning. The clinically most important anthropometric standards are dependent on age, body size, and sex of the patient.

In the case of children in particular, growth has to be taken into account, since a surgically constructed auricle does not show any size growth. The prospective, fully grown body length should be calculated by determining relative body size in comparison with others and with the parents. For a more precise growth analysis, X-ray imaging of the carpal bones can also be performed.

The length of the ear muscles and the auricle width are both age- and size-dependent. The length of the auricle increases from 53 mm to about 63 mm from the age of five years into adulthood. The growth of the auricle ends at about twenty years of age. At the age of six, the ear canal reaches 85%, with nine years approximately 90%, and at the age of fifteen, 95% of its final length. The dependence of auricle width on age and body size is much less pronounced. The increase of auricle width from five years old to adulthood is only minimal, at 2.0 mm. At the age of six, 95% of the auricula's width has already been reached. (12) The normal projection of the ear is at a helix-mastoid distance of 17 to 21 mm, which corresponds approximately to an angle of thirty degrees between the auricle and the occipital plane. (19)

The earlobe has no specific function but plays an important aesthetic role. With a copious blood supply and without cartilage, its surgical reconstruction places a challenge due to the hardness of preserving a natural appearance and longstanding outcome. (20)

9. Methods

A comprehensive literature research was performed using the databases MEDLINE and PubMed by including following search term: (repair[Title/Abstract] OR correction[Title/Abstract] OR reconstruction[Title/Abstract]) AND (earlobe[Title/Abstract] OR earlobes[Title/Abstract] OR ear lobe[Title/Abstract] OR ear lobes[Title/Abstract]) on March 3rd, 2015. A second look for new available literature with the same search term was done on May 13th, 2015. Articles selected for this review specifically were written in English language and focused on the surgical management and techniques for reconstruction of the deformed earlobe due to piercings and plugs. Articles that referred to earlobe reconstruction due to trauma, congenital and acquired cleft deformities and torn earlobes, were excluded. Furthermore, one new method performed by M. Grohmann MD, which is not described in literature, was added to this review. The available and described techniques were summarized in a spreadsheet in Excel 2010 (Microsoft, Richmond, VA, USA) (Table 1) and depicted in a flowchart using Word 2010 (Microsoft, Richmond, VA, USA) (Figure 1). To show a stepwise user manual of the available techniques, drawings of each method were created (by J. M. Wimbauer CM).

A formal ethical review board approval was not required, because no personal or patient data was used.

Technique	Authors	Year
Simple stitches	Tan EC.	1989
Purse string	Vujevich J., ObagiS.	2006
Method described by Grohmann	Grohmann M.	2015
Multiple Wedge Excisions	De la Sotta P.	2010
Reconstruction with L-Plasty	Henderson J., Malata CM.	2010
Reconstruction with a bilobed Flap design	-	-
Single Wedge excision of excess earlobe tissue	-	-
Reconstruction by Bastazini & Pianaro	Bastazini I., Pianaro C.	2013
Reconstruction by Williams & Majumder	Williams AM., Majumder S.	2010
Reconstruction by Arasaratnam	Arasaratnam RBS.	2011
Method by Snell & Caplash	Snell BJ., Caplash Y.	2013
Method by Zeiderman et al	Zeidermann MR.	2014
Split earlobe repair	Pardue A. M.	1973
Method described by Collins	Collins J.	2015
Method described by Sharma	Sharma R.	2014
Method for large defects described by Collins	Collins J.	2015

Table 1: Overview of the available and described techniques

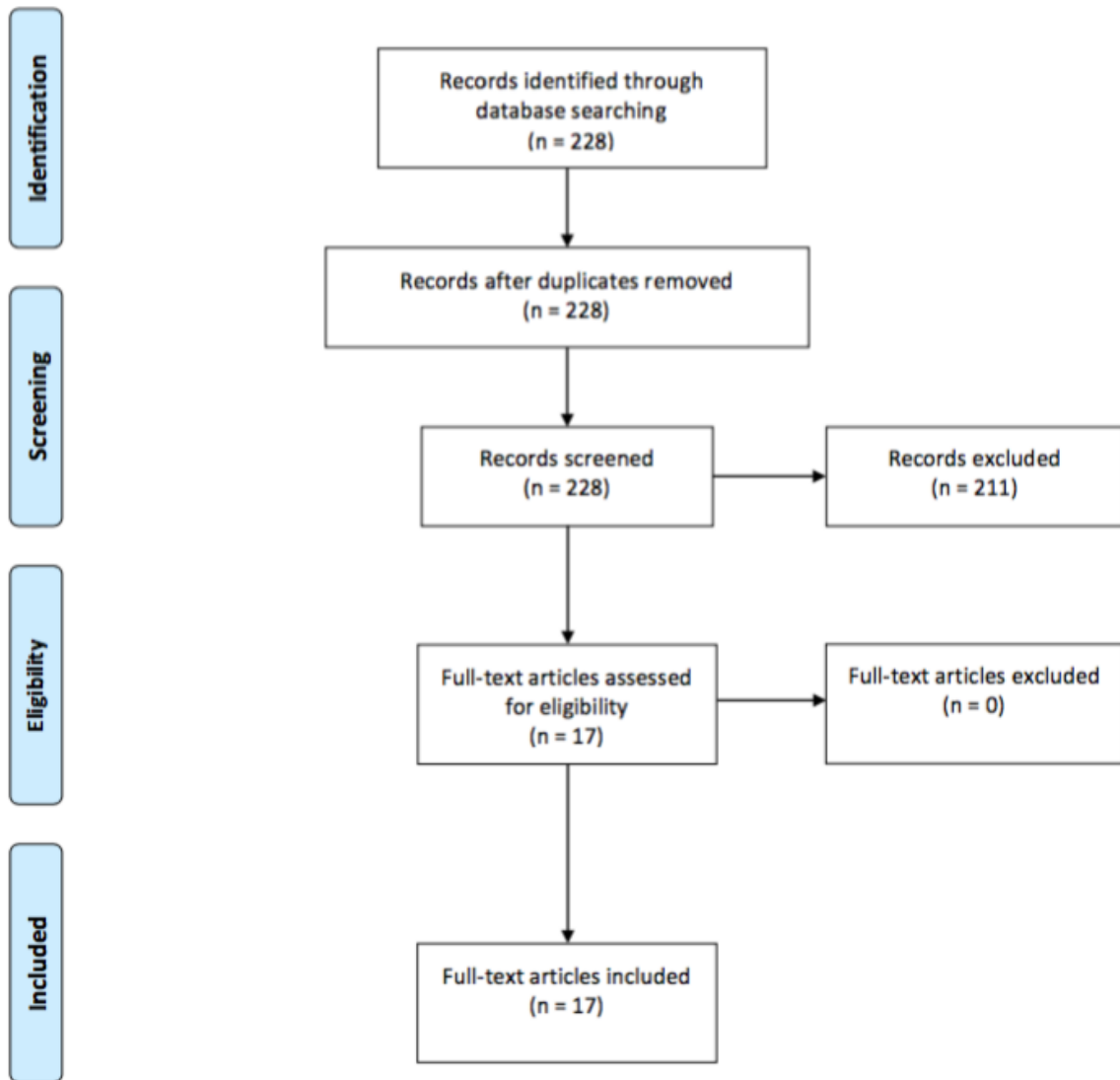


Figure 5: Flowchart of the literature review process

Surgical Techniques

Once a piercing has been placed and the tissue has been stretched, a dilated hole will remain. Large gauge piercings frequently create round defects larger than 1.0 cm. Small stretches may recover and will constrict after removal of the piercing. This may of course vary between individuals. The surgical reconstruction needs to be adapted to the diameter of the defect as well as the original shape of the earlobe. Old photographic images or the contralateral side, if remained untouched, may be helpful as a template. The procedure can easily be performed under local anesthesia. A greater auricular nerve block may be given. To assist, chalazion clamps (Figure 6a), skin hooks and sterile tongue blades (Figure 6b) have been described as helpful tools (21). For excision various methods have been described in literature (22,23), whereas using either a 15-blade scalpel or monopolar electrocautery is recommended. Sutures should be placed in two layers with absorbable 4-0 or 5-0 subcuticular single stitch sutures. For the closure of the skin, non-absorbable 5-0 or 6-0 monofilament single stitched sutures are recommended. To prevent scarring, the stitches should be removed before seven days. Prior to surgery the earrings should not be worn for six weeks to allow for maximum tissue contracture (24).

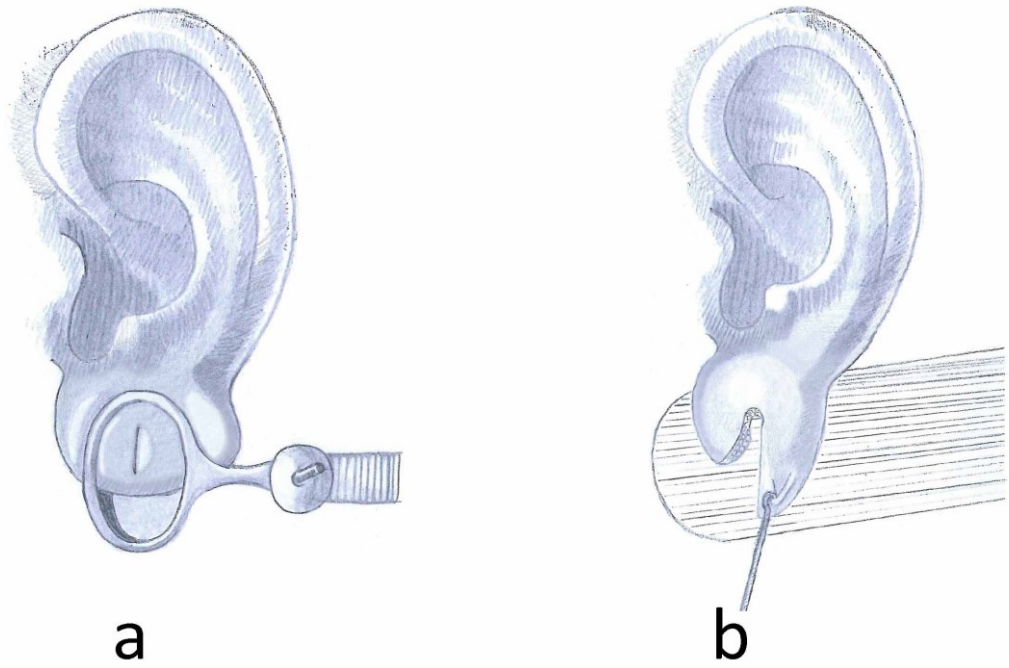


Figure 6: a. Chalazion clamp, b. Skin hook and sterile tongue blade

I. Simple stitches:

For defects with a diameter less than 10 mm an excision of the inner margin of the tunnel can be performed (Figure 7a) and the defect closed with simple stitches (Figure 7b).

The use of a punch biopsy tool instead of a scalpel blade has been described as useful to excise small holes or partial clefts (Figure 7c) (25,26).

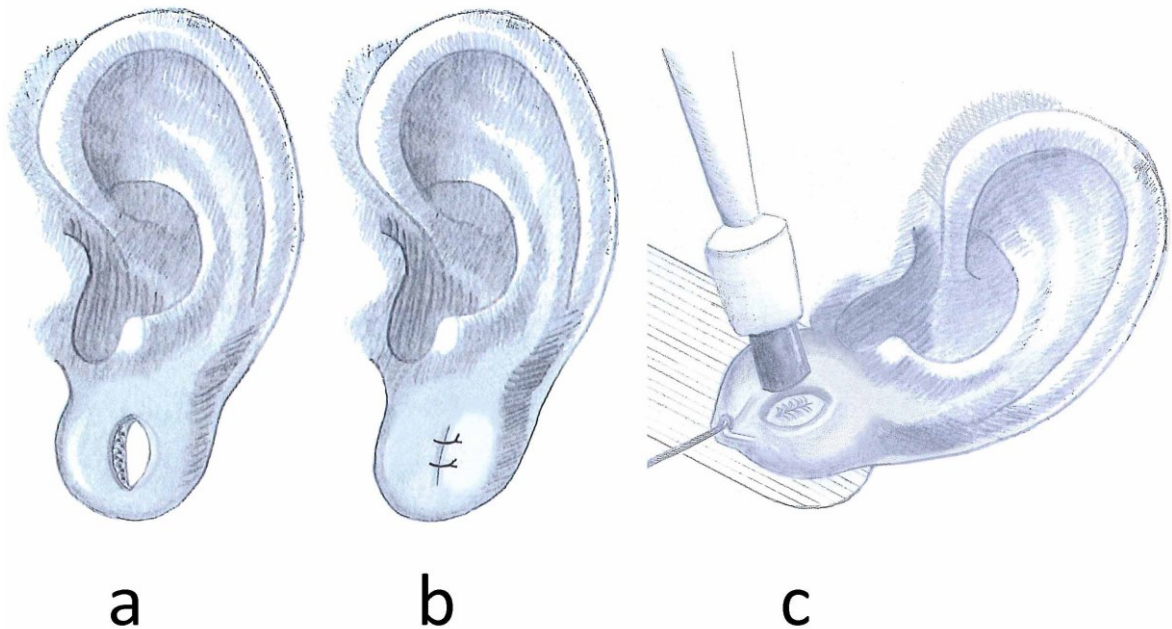


Figure 7: **a,b.** Excision and closure with simple stitches, **c.** Use of a punch biopsy tool instead of a scalpel blade

II. Purse string:

As described by Vujevich and Obagi (27) a repair with the use of the purse string suture technique may be performed in patients with small defects up to 10 mm (Figure 8a). Repeated procedures have been described for larger defects. The placement of two 6-0 polypropylene sutures through the anterior and posterior aspect of the dilated earlobe in purse string technique were described and left in place for four weeks followed by another repeated procedure (Figure 8b). After a period of time, further surgical intervention may be considered, depending on whether the patient either retains a pierced ear or completely closes the defect. Excess tissue may be corrected by a small Z-plasty (Figure 8c).

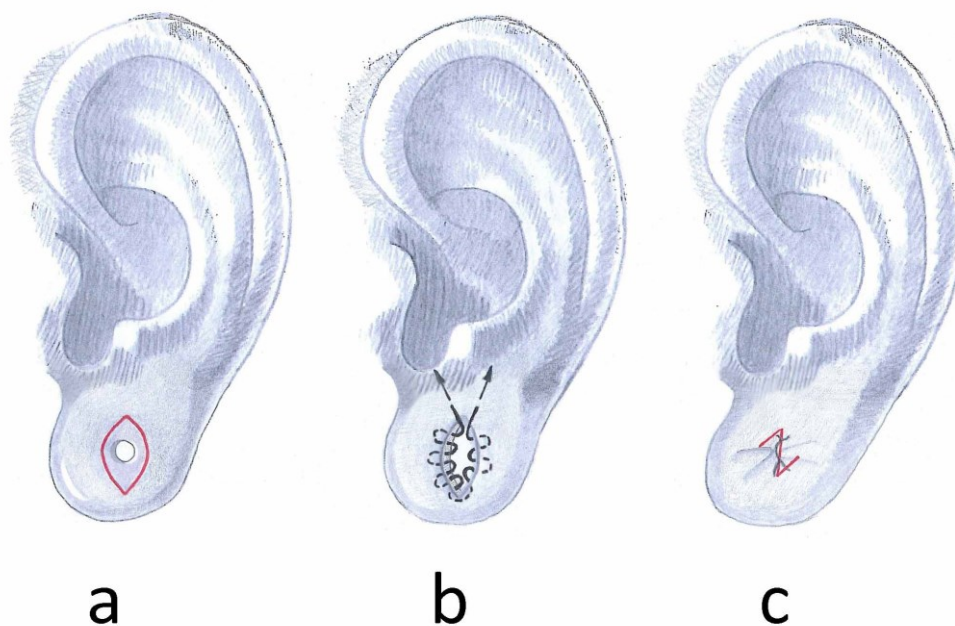


Figure 8: Purse string

III. Double opposing Z-plasty (Method by Grohmann):

For small lobes, not requiring resection of excess tissue, the bidirectional Z-plasty may be used as an aesthetically pleasant and sophisticated method (Figure 9a). Scar deformities caused by shrinking and contracture, also known as the “heart shaped earlobe”, as shown in Figure 10, can thereby be prevented. This can be achieved by performing a bilateral approach with a skin incision followed by de-epithelialization of the tunnel. After placing the subcutaneous sutures the adaptation leads to plenty of excess skin which then can be dissolved by multiple Z-plasties in a bidirectional manner as shown in Figure 9b and Figure 9c.

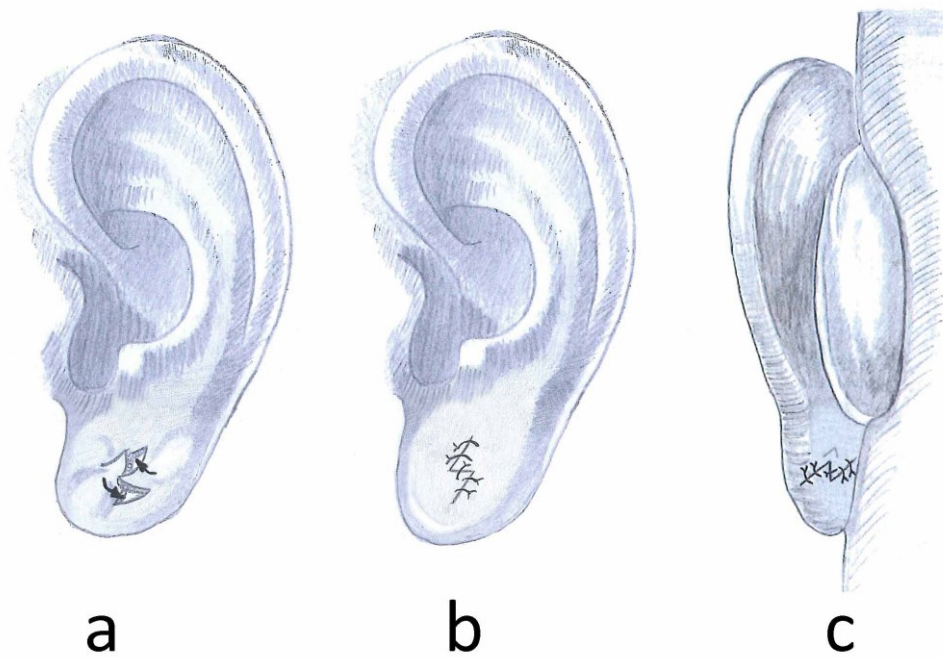


Figure 9: Method by Grohmann

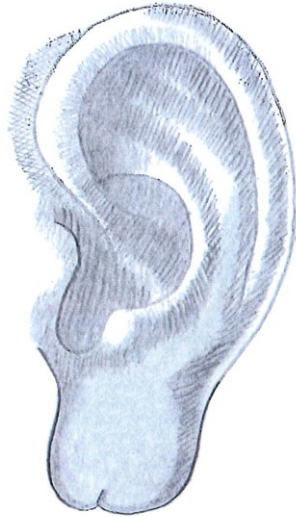

Figure 10: Heart shaped earlobe

IV. Multiple wedge excisions:

This method has first been described by de la Sotta et al. (28). After the de-epithelialization of the earlobe canal, multiple wedges are excised (Figure 11a). The number of wedges depends on the size of the defect. The defect is then closed with interrupted sutures on each side of the lobe (Figure 11b).

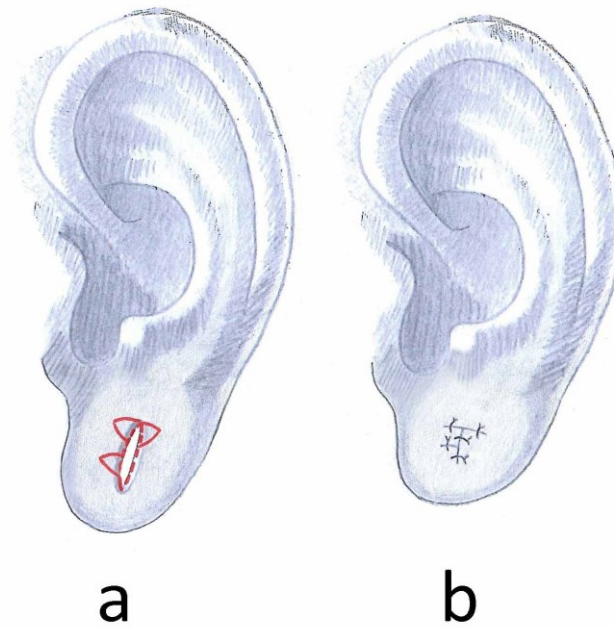


Figure 11: Multiple wedge excision

V. Reconstruction with L-plasty:

For large defects reconstruction with a single flap design can be the treatment of choice (29) in order to achieve a cosmetically satisfying result. The lateral margin of the earlobe, which is part of the tunnel, is used as a random pattern flap (Figure 12a). The resection and closure of the defect can be done in an L-shaped manner. (Figure 12b and Figure 12c).

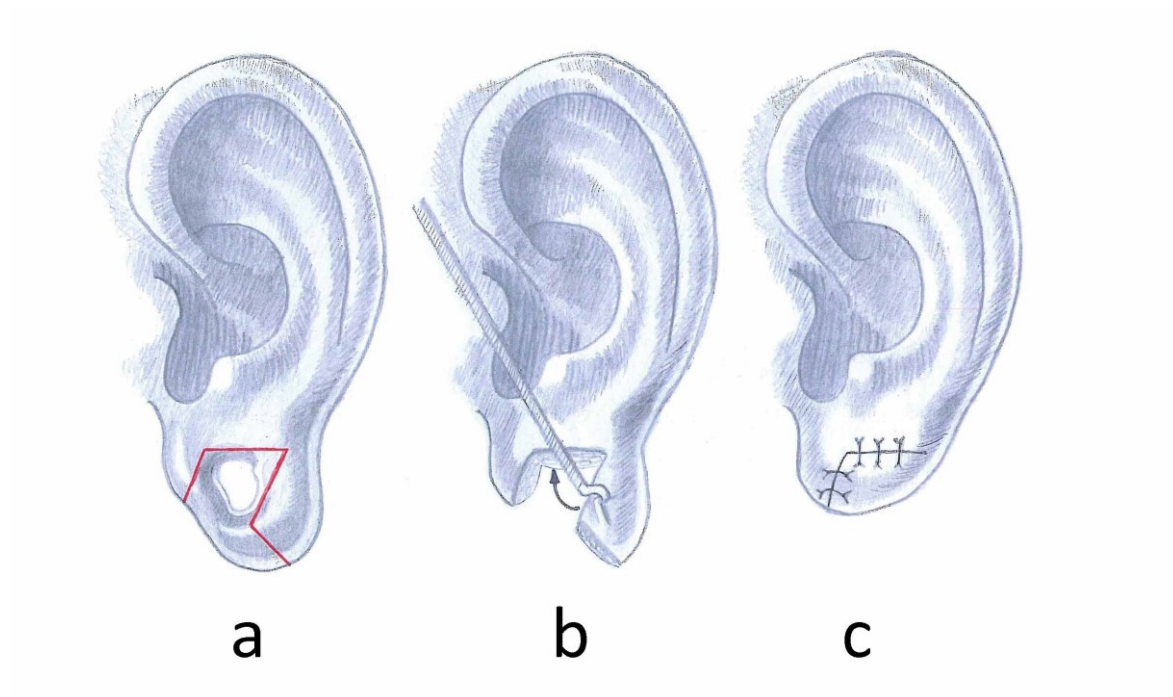


Figure 12: Reconstruction with L-plasty

VI. Reconstruction with a bilobed flap design:

For very large defects and big lobes a double flap design as shown in Figure 13a can be an option. After de-epithelialization and resection of the redundant tissue (Figure 13b) the two flaps can be sutured into place (Figure 13c). In this way, sufficient vascularity may be provided if special circumstances such as very thin margins of the dilated lobule exist.

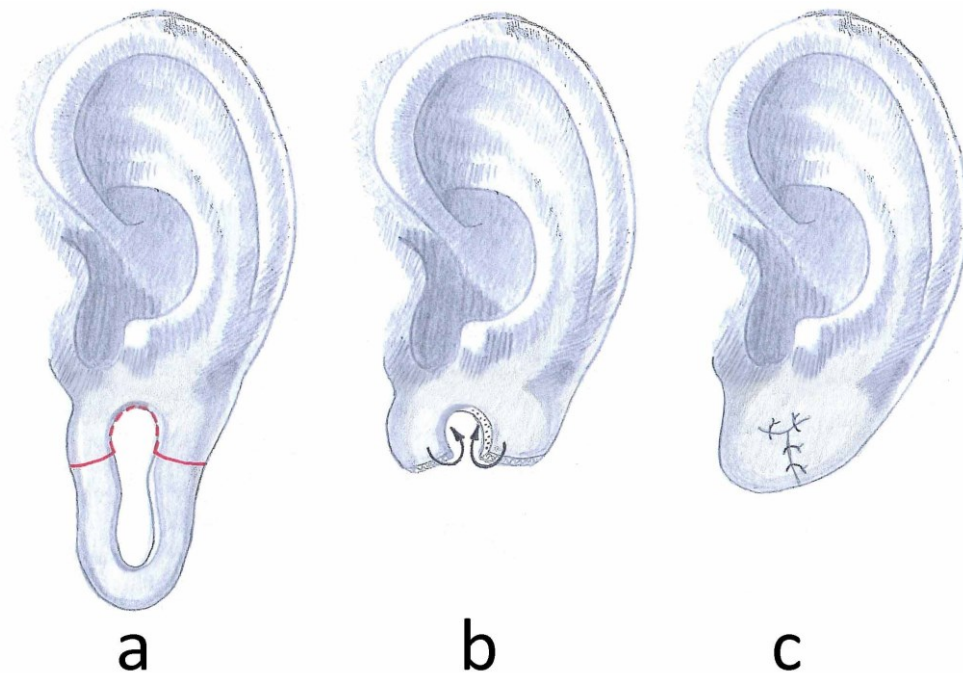


Figure 13: Reconstruction with a bi-lobed flap

VII. Single wedge excision of excess earlobe tissue:

This method can be the treatment of choice for large lobe deformities after earplug removal. The method includes the resection of the excess lobe tissue including the tunnel that needs to be resected or de-epithelialized (Figure 14a). A vertical suture towards the margin cannot be avoided with this technique (Figure 14b).

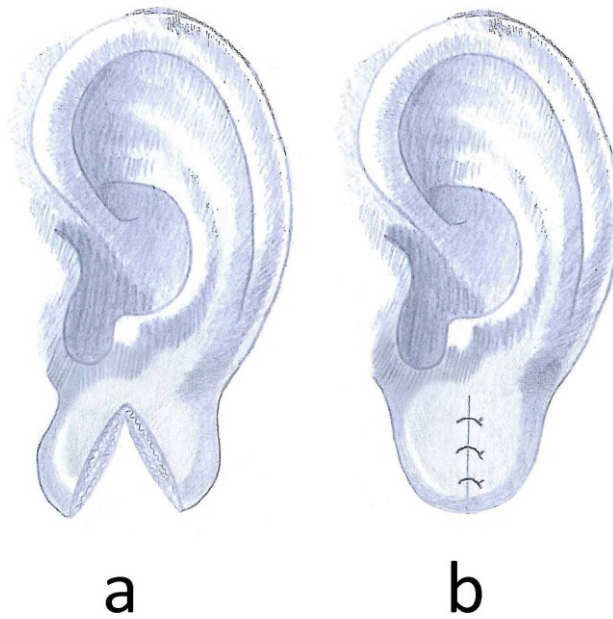


Figure 14: Single wedge excision of excess earlobe tissue

Once again a Z-plasty may help to avoid a “heart shaped earlobe” deformity (Figure 15a) and may achieve better long-term aesthetic results (Figure 15b and Figure 15c).

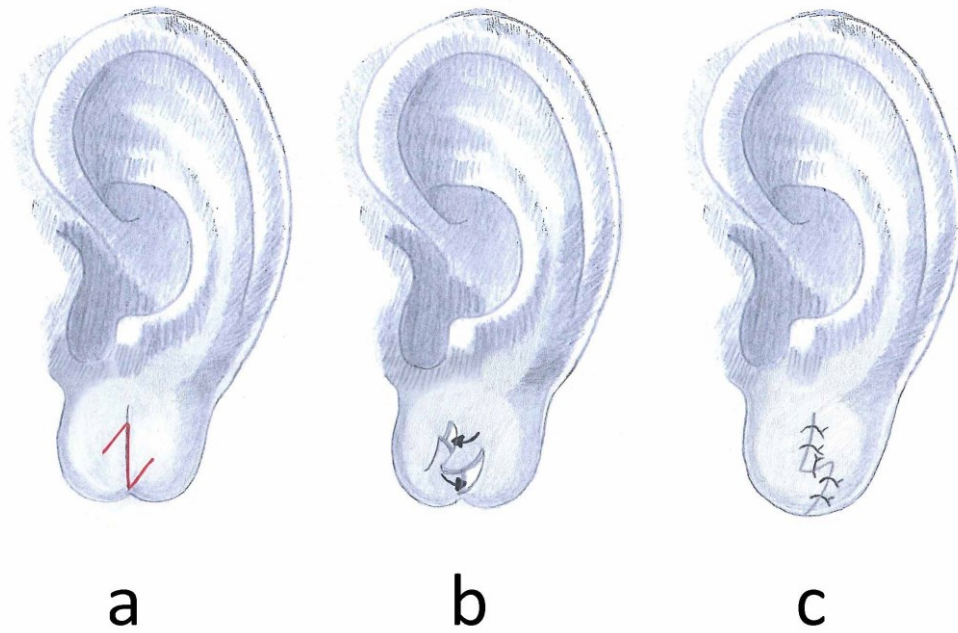


Figure 15: Z-plasty to avoid heart shaped earlobe

VIII. Reconstruction by Bastazini:

This method can be used to avoid decrease in the volume of the earlobe (30). An incision is made near the anterior aspect. The inner aspect is then de-epithelialized and folded superiorly, this way the removal of tissue can be minimized to be able to keep more volume for the reconstruction of the lobule (Figure 16a). Depending on the presenting tissue surplus, the excess tissue of the dilated rim can then be resected. The outer surface can further be de-epithelialized and sutured to the remaining anterior aspect of the lobule (Figure 16b and Figure 16c). As mentioned above, this method tries to regain as much tissue volume as possible but may have disadvantages such as insufficient blood supply of the folded flap or unpleasant scar tissue formations. It has been described that this technique could be a pleasant alternative for unilateral gauge piercing deformities in order to achieve better symmetry.

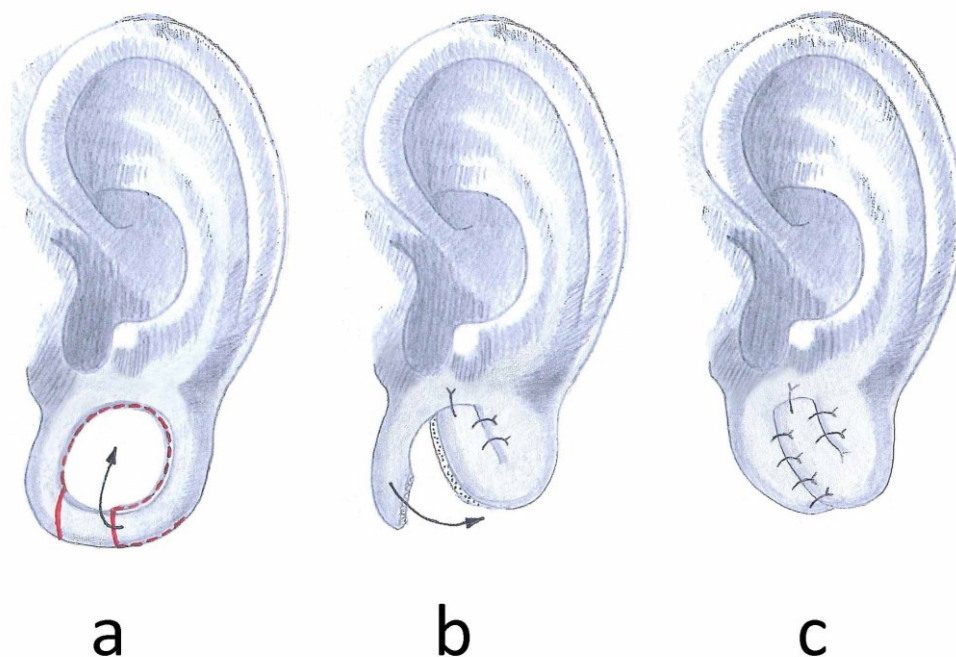


Figure 16: Reconstruction by Bastazini

IX. Reconstruction by Williams:

This method, in contrast to the method described above, proposes immediate excision of excess earlobe tissue as well as de-epithelialization of the earlobe margin. (31) The description of this method is not very detailed and the amount of necessary margin de-epithelialization can only be guessed. (Figure 17) However, the authors describe this method in two patients and achieving cosmetically pleasant results. Earlobe reduction is significant and precise planning of this technique is necessary.

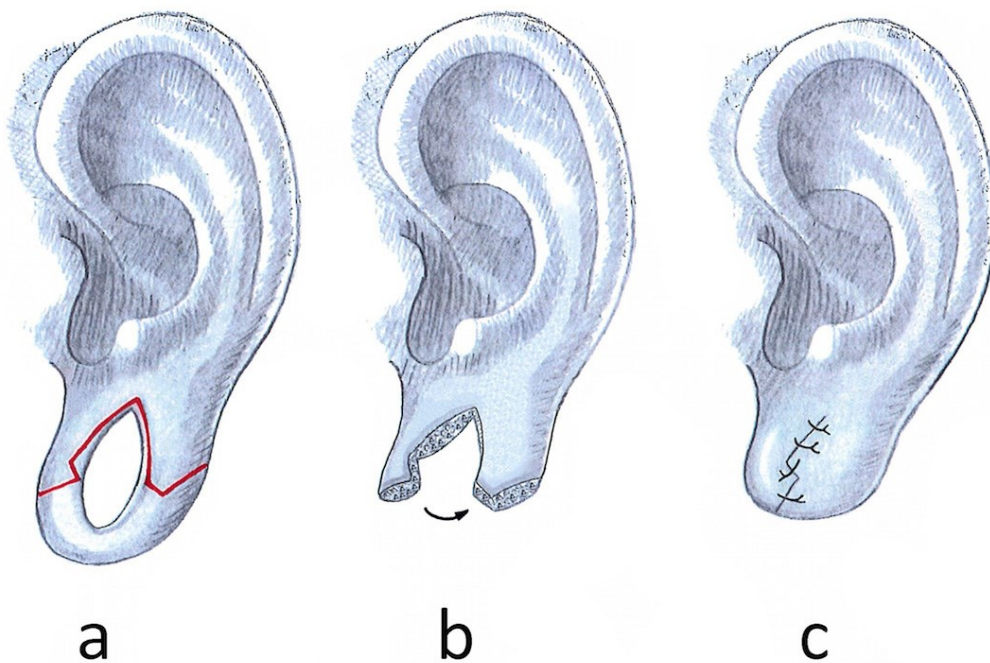


Figure 17: Reconstruction by Williams

X. Reconstruction by Arasaratnam:

First de-epithelialization of the inner margin is performed (Figure 18a), followed by a linear approximation and anterior folding of the expanded tissue (Figure 18b and Figure 18c) (32). This is another method to maximize the tissue preservation and to avoid destruction to the outline of the rim. (Figure 18d) Long-term results of this method are not reported.

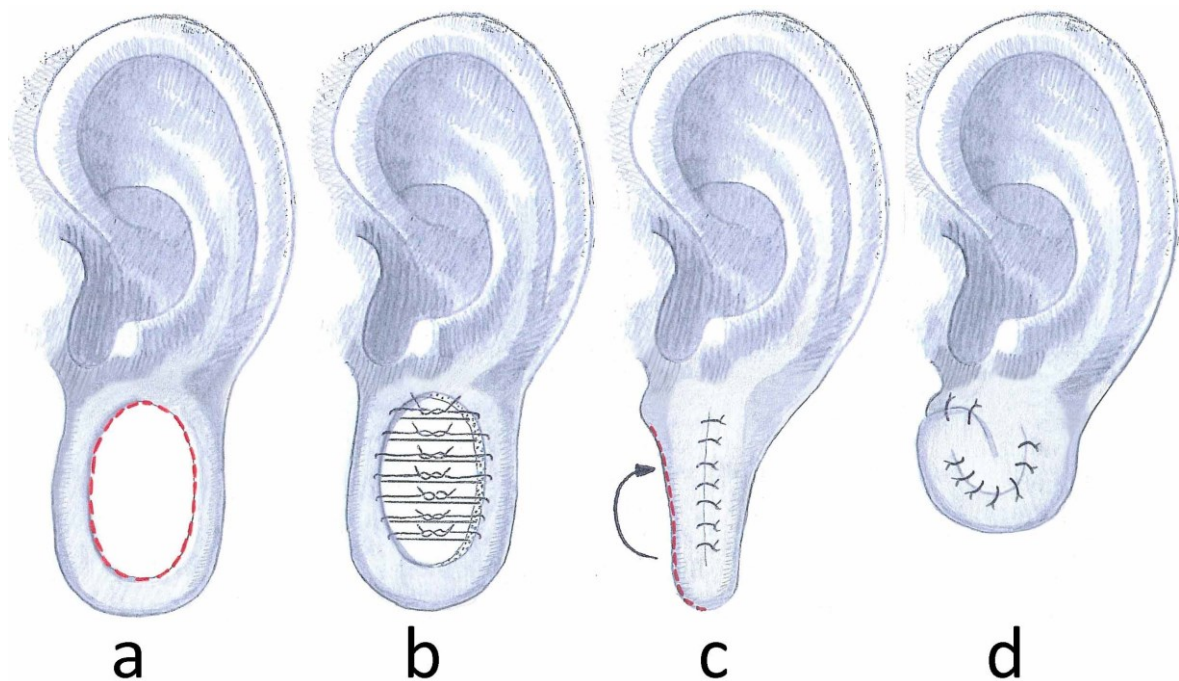


Figure 18: Reconstruction by Arasaratnam

XI. Method by Snell:

This technique (33) has been described as the “rolled-up anchovy” method. The inferior rim is separated at the transition between the anterior first and second third (Figure 19a). The inferior rim as well as the outer rim of the posterior flap is then de-epithelialized as far as necessary. The flap is then curled upon itself (Figure 19b) sutured into place and covered with the small anterior flap (Figure 19c). Sufficient earlobe tissue is provided in this method and the size of the lobe can be adapted to the patients’ wish.

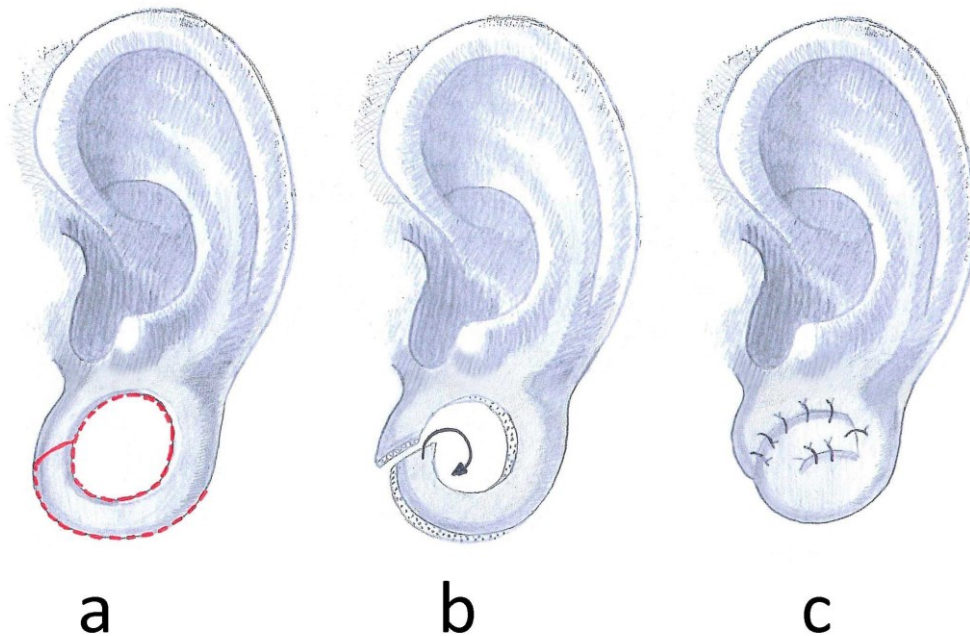


Figure 19: Method by Snell

XII. Method by Zeiderman et al.:

The “double opposing perpendicular linear closure technique” is performed by a circular de-epithelialization of the inner margin as a first step (Figure 20a and Figure 20d). (34) From this approach the tissue is then undermined with a small scissor. The closure in the anterior aspect is performed by a linear horizontal closure (Figure 20b) followed by another linear closure in the posterior aspect oriented ninety degrees to the anterior one in a vertically oriented manner (Figure 20e). This way the authors describe to avoid dog-ear deformity and achieve a rounded ear lobule outline free of notching (Figure 20c and Figure 20f). Satisfactory outcomes have been described with the use of this method, however in some cases wrinkling of the excess tissue may be arise and persist permanently.

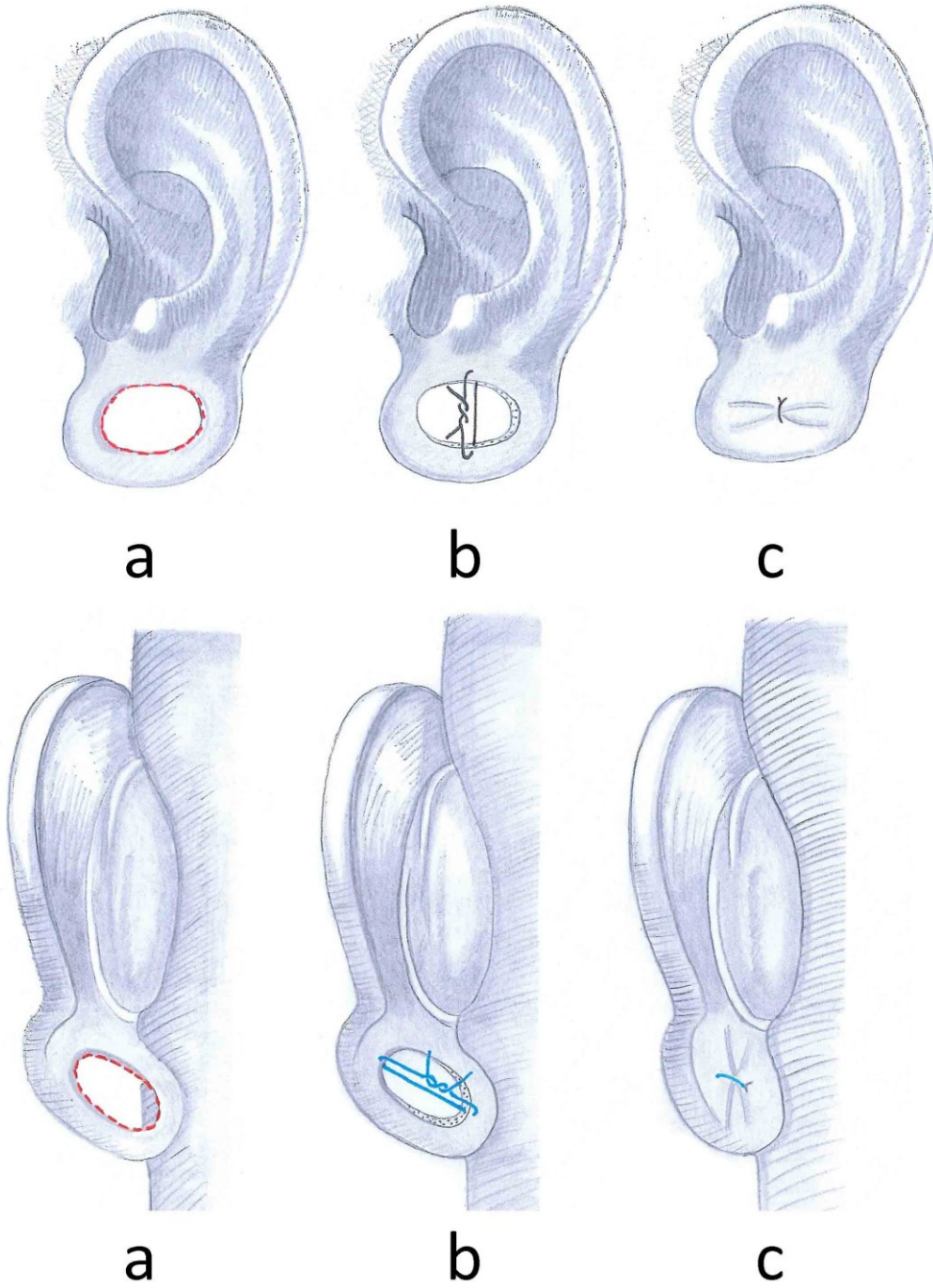


Figure 20: Method by Zeiderman et al.

XIII. Split earlobe repair

Pardue described the split earlobe repair method in 1973 (35). It allows immediate reconstruction of a split earlobe deformity with simultaneous reconstruction of the once pierced tunnel. Such a defect may be closed as shown in Figure 14 above requiring the ear to be re-pierced or the tunnel can be reconstructed if the individual wishes. As shown in Figure 21a small flap needs to be raised either from the anterior or posterior aspect of the split lobe. The flap is then curled superiorly (Figure 21b) and sutured into place to reconstruct the former tunnel (Figure 21c).

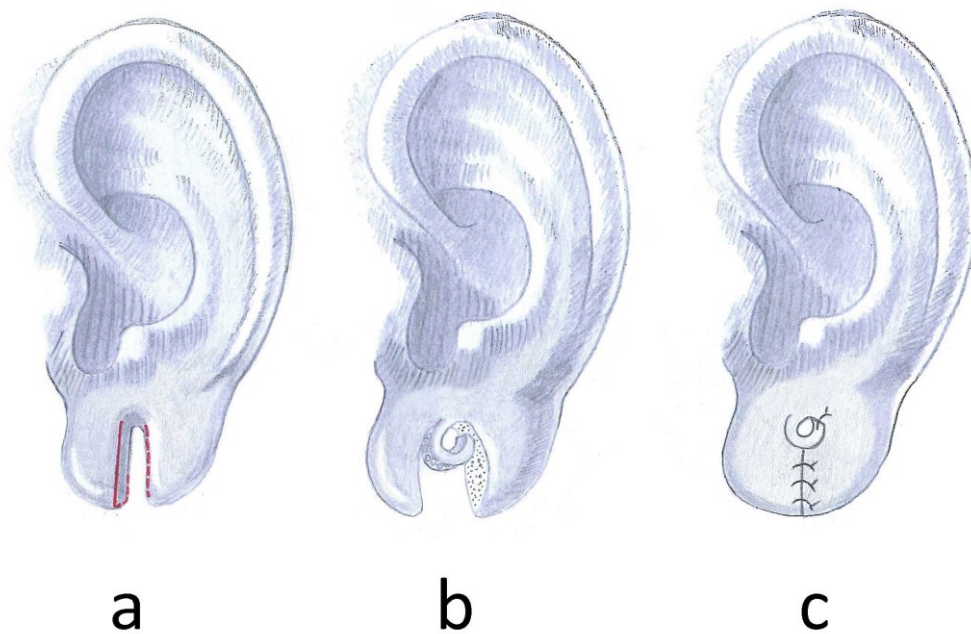


Figure 21: Split earlobe repair

The rest of the defect can then be closed in a linear way or with a small Z-plasty as shown in Figure 22 to avoid a linear scar all the way to the rim.

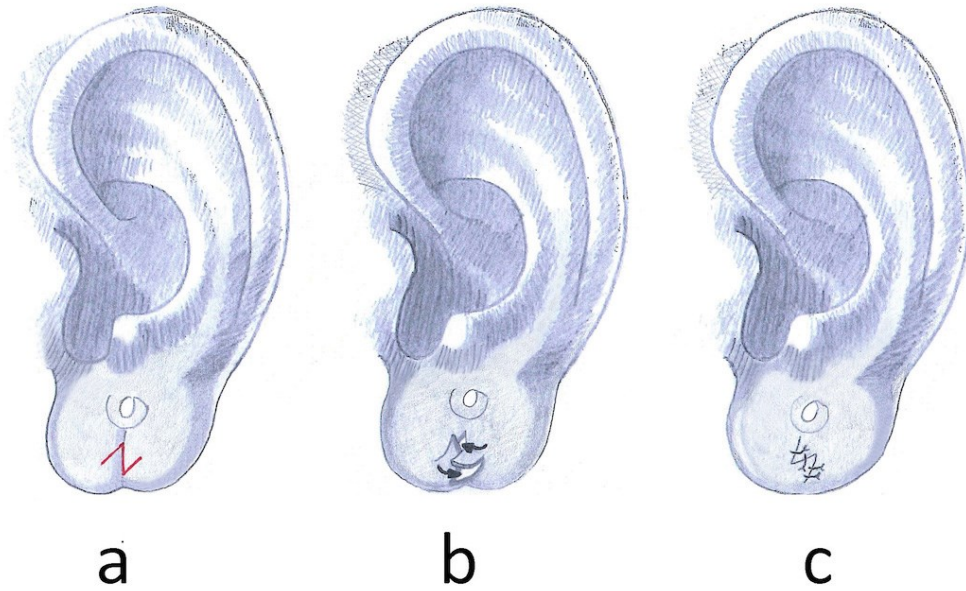


Figure 22: Small Z-plasty to avoid a linear scar

XIV. Method described by Collins

Collins et al. describe several methods for defect closure. For medium defects, reconstruction can be performed using a posterior-based advancement flap (36). This technique has the advantage of avoiding an incision across the outer border. Raising a posterior-superior based advancement flap follows the de-epithelialization (Figure 23a). The flap is then mobilized anteriorly and sutured into the defect (Figure 23b).

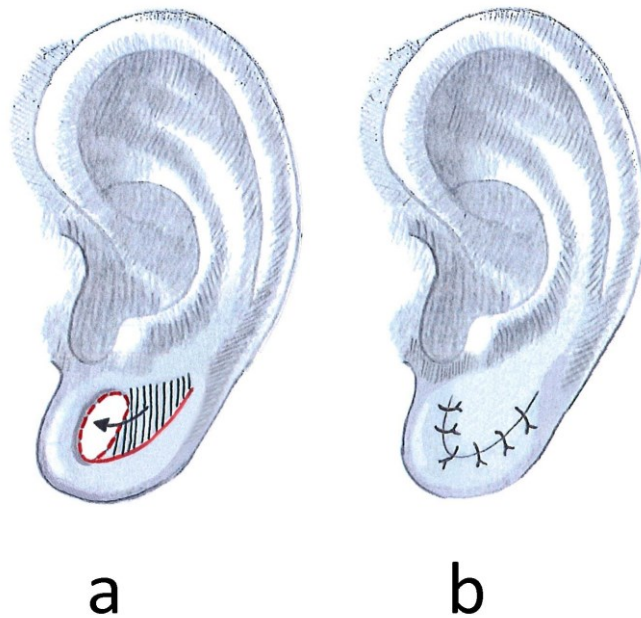


Figure 23: Method described by Collins

XV. Method described by Sharma

Sharma et al. describe a technique that involves a rotation flap lobuloplasty (37). Their method allows the patient to keep a pierced earlobe and spares the outer border of incisions. After marking the flap as shown in Figure 24a the triangular flap is lifted from the posterior margin of the defect of the lateral surface. (37) The remaining epithelium inside the stretched hole is then excised up to the superior margin of the defect as far as needed (Figure 24b). The flap is then elongated and rotated into itself until it reaches the intact margin (Figure 24c). This way future jewelry will not be in direct pressure contact with any scarred tissue that should be avoided under any circumstances. The rest of the defect can then be closed by primary closure (Figure 24d).

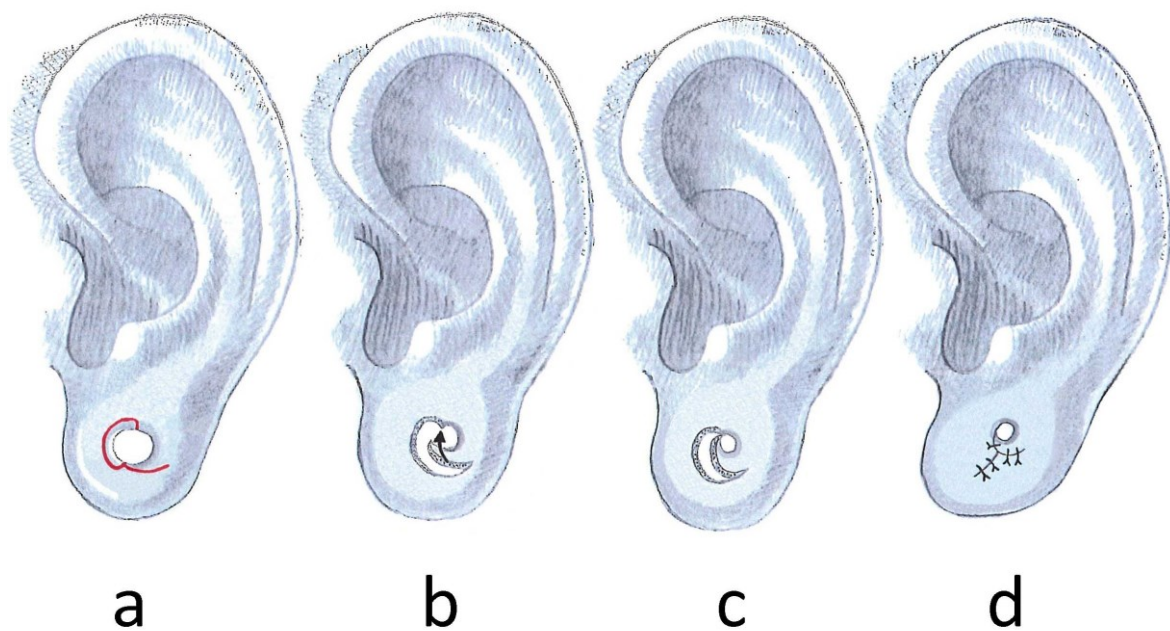


Figure 24: Method described by Sharma

XVI. Method for large defects described by Collins

Large defects as shown above, may require resection of redundant soft tissue that has been stretched inferiorly (36). The defect de-epithelialization is followed by two transverse incisions across the loop (Figure 25a). One incision is made across the posterior limb. This incision should correspond to the leading edge of the advancement flap to finally connect to the newly designed anterior limb. A further incision is then placed across the anterior rim at the adequate position for the inferior border of the earlobe (Figure 25a). The two created flaps are now raised. The posterior flap is raised as an advancement flap and finalized by a wedge excision as far as required (Figure 25b). The flap can then be advanced anteriorly to cover the superiorly defect of the previously stretched lobe. Wedge excision as well as the two transverse incisions can be performed in a graduated manner to avoid over resection of lobule tissue. Fine-tuning of the two flaps will be necessary to achieve a cosmetically pleasant result (Figure 25c).

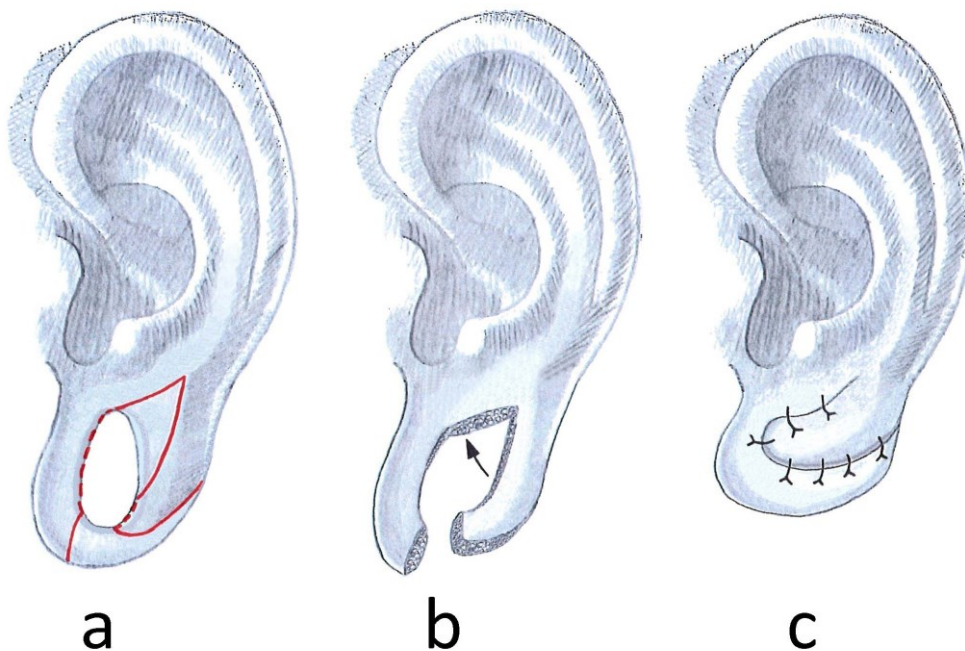


Figure 25: Method for large defects described by Collins

10. Discussion

Most defects can easily be corrected in an outpatient setting by application of one of the described methods. The use of punch biopsy without further modification may not lead to smooth and even edges, but leads to unpleasant scars as the margins of the wound will not adapt as smoothly as if one designs an elliptical shape for excision.

Long linear scars interfering with the margin of the lobule, especially in the medial inferior aspect of the lobule, should be avoided if possible. As shown in Figure 10 cosmetically unpleasant results may occur. The amount of scar-contraction may vary between individuals and needs to be considered. Z-plasty may be a useful technique to avoid problems such as the “heart shaped earlobe”. Placing any jewelry directly into a scar tissue should be avoided as it may lead to complications because cicatricial tissue is not refractory. Due to a lack of published cases including high patient numbers, it is unfeasible to determine a single method that leads to the best cosmetic results. The selection of the most adequate technique has to be made by the surgeon individually.

In summary, this review describes and outlines the surgical methods currently available for earlobe reconstruction and hopes to assist in preoperative decision-making.

11. References

1. Ferguson H. Body piercing. *BMJ*. 1999 Dec 18;319(7225):1627–9.
2. Featherstone M. *Body modification*. SAGE; 2000. 358 p.
3. Stirn A. Body piercing: medical consequences and psychological motivations. *Lancet*. 2003 Apr 5;361(9364):1205–15.
4. Stewart C. Body piercing; seductions and medical complications of a risky practice. *Med Aspects Hum Sex*. 2001;1(5):45–50.
5. Brennan M, O’Connell B, O’Sullivan M. Multiple dental fractures following tongue barbell placement: a case report. *Dent Traumatol Off Publ Int Assoc Dent Traumatol*. 2006 Feb;22(1):41–3.
6. Berenguer G, Forrest A, Horning GM, Towle HJ, Karpinia K. Localized periodontitis as a long-term effect of oral piercing: a case report. *Compend Contin Educ Dent Jamesburg NJ* 1995. 2006 Jan;27(1):24–7; quiz 28, 36.
7. Khalia N, Mehta D, Vemanaradhya G. Oral piercing: style statement or a state of disharmony? *Int J Oral Health Sci*. 2013;3(2):84.
8. Vale V, Juno A. *Modern Primitives: An investigation of contemporary adornment & ritual*. Re/Search Publications; 1989. 220 p.
9. Anderhuber F, Pera F, Streicher J. *Waldeyer Anatomie des Menschen*. 19th ed. Berlin/Boston: Walter de Gruyter GmbH & Co. KG; 2012. p. 748, 909-917.

10. Berghaus A., Rettinger G., Böhme G. Hals-Nasen-Ohren-Heilkunde. Stuttgart: Hippokrates Verlag; 1996. p. 24-27. (Duale Reihe).
11. Frotscher M., Kahle W. Taschenatlas Anatomie. Nervensystem und Sinnesorgane. 10th ed. Stuttgart: Georg Thieme Verlag; 2009. p. 366-368. vol 3.
12. Weerda H. Surgery of the auricle. Stuttgart: Georg Thieme Verlag; 2007.
13. Lüllmann-Rauch R. Taschenlehrbuch Histologie. 3rd ed. Stuttgart: Georg Thieme Verlag KG; 2009. p. 137-144, 559-560.
14. Drake RL, Vogl W, Mitchell AWM. Gray's Anatomie für Studenten. 1st ed. München: Elsevier GmbH; 2007. p. 888-891.
15. Siegert R, Magritz R. Reconstruction of the auricle. GMS Curr Top Otorhinolaryngol Head Neck Surg. 2007;6:Doc02.
16. Sadler TW. Medizinische Embryologie. 11th ed. Stuttgart: Georg Thieme Verlag KG; 2008. p.431-442.
17. Leiber B. Ohrmuscheldystopie, Ohrmuscheldysplasie und Ohrmuschelmißbildung – klinische Wertung und Bedeutung als Symptom. Arch Otorhinolaryngol. 1972;202:51-84.
18. Davis J. Aesthetic and reconstructive otoplasty. Berlin: Springer; 1997.
19. Vogt PM. Praxis der Plastischen Chirurgie. Berlin Heidelberg: Springer-Verlag GmbH; 2011. p. 133-138.

20. Cabral AR, Alonso N, Brinca A, Vieira R, Figueiredo A. Earlobe reconstruction by the gavello technique and bilobed flap. *An Bras Dermatol*. 2013 Mar-Apr;88(2):272-275.
21. Smith C, Glaser DA. Surgical pearl: repair of split or deformed ear lobe with a tongue depressor blade for stabilization during surgery. *J Am Acad Dermatol*. 1998 Jun;38(6 Pt 1):990–1.
22. Bastazini I, Bastazini I, de Melo MCC, Peres CS, da Silva Biscarde EF. Surgical pearl: dermabrasion for the correction of incomplete cleft earlobe. *J Am Acad Dermatol*. 2005 Apr;52(4):688–9.
23. Niamtu J. Eleven pearls for cosmetic earlobe repair. *Dermatol Surg Off Publ Am Soc Dermatol Surg Al*. 2002 Feb;28(2):180–5.
24. Benvenuti H, Benvenuti D. Repair of massive earlobe piercing and plugs (gauging). *Plast Reconstr Surg Glob Open*. 2014 Oct;2(10):e225.
25. Tan EC. Punch technique: an alternative approach to the repair of pierced earlobe deformities. *J Dermatol Surg Oncol*. 1989 Mar;15(3):270–2.
26. AlGhamdi KM, AlEnazi MM. Versatile punch surgery. *J Cutan Med Surg*. 2011 Mar 1;15(2):87–96.
27. Vujevich J, Obagi S. Repair of partial earlobe cleft using a “purse-string” repair. *Dermatol Surg Off Publ Am Soc Dermatol Surg Al*. 2006 Jul;32(7):969–71.
28. De la Sotta P, Paredes N, Lasalle MA. Repair of dilated earlobe due to plug piercing. *Dermatol Surg Off Publ Am Soc Dermatol Surg Al*. 2010 Oct;36(10):1621–3.

29. Henderson J, Malata CM. Surgical correction of the expanded earlobe after ear gauging. *Aesthetic Plast Surg*. 2010 Oct;34(5):632–3.
30. Bastazini I, Pianaro C. New approach to repair of expanded earlobe. *Dermatol Surg Off Publ Am Soc Dermatol Surg Al*. 2013 Jul;39(7):1127–9.
31. Williams AM, Majumder S. Earlobe reconstruction following plug and tunnel piercing. *J Plast Reconstr Aesthetic Surg JPRAS*. 2010 Mar;63(3):e294–5.
32. Arasaratnam RBS, Patel SK, Pramechander D, Ramotar H, Daodu KA. Repair of large holes in stretched earlobes. *Clin Otolaryngol Off J ENT-UK Off J Neth Soc Oto-Rhino- Laryngol Cervico-Facial Surg*. 2011 Dec;36(6):597–8.
33. Snell BJ, Caplash Y. A novel way to repair the earlobe after ear-gauging. *J Plast Reconstr Aesthetic Surg JPRAS*. 2013 Jan;66(1):140–1.
34. Zeiderman MR, Kelishadi SS, Tutela JP, Chowdry S, Wilhelmi BJ. Double opposing perpendicular linear repair of gauge ear-piercing deformity: a new technique and literature review. *Eplasty*. 2014;14:e31.
35. Pardue AM. Repair of torn earlobe with preservation of the perforation for an earring. *Plast Reconstr Surg*. 1973 Apr;51(4):472–3.
36. Collins J, Harvey J, Hilinski JM. Reconstructing the gauge earlobe defect. *JAMA Facial Plast Surg*. 2015 Mar 1;17(2):144–8.

37. Sharma R, Krishnan S, Kumar S, Verma M. Rotation flap lobuloplasty: technique and experience with 24 partially torn earlobes. *Int J Oral Maxillofac Surg.* 2014 Oct;43(10):1206– 10.