

Diploma Thesis - Diplomarbeit



**Expression of the Vascular Endothelial Growth Factor (VEGF)
in a Drill Hole Lesion of the Growth Plate**

submitted by

Maximilian Seles

Matrikelnummer: 0311803

attaining the academic degree

Doktor der gesamten Heilkunde

Dr. med. univ.

at the

Medical University of Graz

conducted at the

Department of Paediatric and Adolescent Surgery

under the supervision of

PD Dr. med. Annelie – Martina Weinberg

Dr. med Eva-Elisa Widni

Declaration of Authorship

I certify that the work presented here is, to the best of my knowledge and belief, original and the result of my own investigations, except as acknowledged, and has not been submitted, either in part or whole, for a degree at this or any other university.

June, 4 2010

Maximilian Seles

Graz

Eidesstattliche Erklärung

Ich erkläre ehrenwörtlich, dass ich die vorliegende Arbeit selbstständig und ohne fremde Hilfe verfasst habe, andere als die angegebenen Quellen nicht verwende habe und die den benutzten Quellen wörtlich oder inhaltlich entnommenen Stellen als solche kenntlich gemacht habe.

Graz, am 4.Juni 2010

Maximilian Seles

Table of Contents

Declaration of Authorship	2
Eidesstattliche Erklärung	2
Table of Contents	3
Abbreviations	7
Figures	8
Tables	10
Abstract (English)	11
Abstract (Deutsch)	13
Acknowledgement	15
1 Introduction	16
1.1 The Growth Plate	16
1.1.1 Introduction.....	16
1.1.2 Gross Anatomy	16
1.1.3 Bone and Growth Plate Development	17
1.1.3.1 Direct (Intramembranous) Ossification	17
1.1.3.2 Indirect (Chondral) Ossification	18
1.1.3.3 Molecular Details.....	20
1.1.4 Microscopic Anatomy.....	21
1.1.4.1 Growth Plate.....	21
1.1.4.1.1 Resting Zone	22
1.1.4.1.2 Proliferative Zone	22
1.1.4.1.3 Hypertrophic Zone	22
1.1.4.1.4 Degeneration/Mineralisation Zone	23
1.1.4.1.5 Primary Spongiosa Zone	23
1.1.4.2 Bone Tissue.....	23
1.1.5 Regulation	24
1.1.5.1 Systemic Factors	24
1.1.5.1.1 Growth Factor – Insulin like Growth Factor – Axis	24
1.1.5.1.2 Thyroid Hormones	25

1.1.5.1.3	Glucocorticoids	25
1.1.5.1.4	Oestrogen	25
1.1.5.1.5	Androgens.....	25
1.1.5.2	Local Factors	26
1.1.5.2.1	Indian Hedgehog.....	26
1.1.5.2.2	Parathormone-related Peptide (PTHrP)	26
1.1.5.2.3	Fibroblast Growth Factors (FGF).....	27
1.1.5.2.4	Bone Morphogenetic Proteins (BMPs)	27
1.1.5.2.5	Vascular Endothelial Growth Factor (VEGF)	27
1.1.5.3	Closure of the Growth Plate	28
1.1.6	Fracture Healing of Bones	29
1.1.6.1	Normal Fracture Healing in Children	29
1.1.7	Injuries of the Growth Plate	29
1.1.7.1	Fractures.....	30
1.1.7.1.1	Classification	30
1.1.7.2	ACL Reconstruction.....	32
1.2	Vascular Endothelial Growth Factor (VEGF)	33
1.2.1	Introduction.....	33
1.2.1.1	Historical Background.....	33
1.2.2	Gene	33
1.2.3	Isoforms.....	34
1.2.4	Protein Structure	35
1.2.5	Cellular Activation Pathway	36
1.2.5.1	VEGF related Proteins.....	37
1.2.6	Regulation	37
1.2.6.1	Oxygen tension	38
1.2.6.2	Core binding factor 1 (Cbfa1)	39
1.2.6.3	Bone Morphogenetic Proteins (BMPs)	39
1.2.6.4	Connective Tissue Growth Factor (CTGF)	40
1.2.6.5	Matrix Metalloproteinase 9 (MMP 9)/Gelatinase B	40
1.2.6.6	Transforming Growth Factor - Beta 1 (TGF - Beta 1)	40
1.2.6.7	Hormones & Growth Factors.....	41
1.2.6.8	Oncogens.....	41
1.2.6.9	Cytokines	41
1.2.7	VEGF Receptors	42
1.2.7.1	VEGF Receptor 1 (KDR, Flt-1).....	42

1.2.7.2	VEGF Receptor 2 (Flk-1)	43
1.2.7.3	VEGF Receptor 3	43
1.2.7.4	Neuropillins	43
1.2.7.5	Heparan Sulfate Proteoglycans	43
1.2.7.6	Heparin	44
1.2.8	Function	44
1.2.8.1	Endothelial Cells	44
1.2.8.2	Osteoblasts	45
1.2.8.3	Mesenchymal Stem Cells	45
1.2.8.4	Chondroblasts	45
1.2.8.5	Osteoclasts	46
1.2.8.6	Haematopoietic System	46
1.2.8.7	Other cells	46
1.2.9	Role of VEGF in physiological Conditions	47
1.2.9.1	Embryonic and Postnatal Development	47
1.2.9.1.1	Embryonic development	47
1.2.9.1.2	Postnatal Development	48
1.2.9.2	VEGF in Enchondral Bone Formation & Skeletal Growth	48
1.2.9.3	Ovarian Angiogenesis	48
1.2.10	Role of VEGF in pathological Conditions	48
1.2.10.1	Solid Tumours	49
1.2.10.2	Hematologic Malignancies	49
1.2.10.3	Pathological Neovascularisation	49
1.2.11	VEGF and the Growth Plate	50
1.2.11.1	Localisation and Expression	50
2	Materials and Methods	51
2.1	Overview	51
2.2	Authorization	51
2.3	Animals	51
2.3.1	Sprague Dawley Rats	51
2.3.2	Housing	52
2.3.3	Groups	52
2.4	Surgery	53
2.4.1	Anaesthesia and Preparation	53
2.4.1.1	Drugs	54
2.4.2	Operation	55

2.4.3	Recovering and post-operative Surveillance.....	58
2.4.4	Tissue Harvest	59
2.4.4.1	Chemical Products	59
2.4.4.2	Extraction.....	60
2.4.4.3	Fixation	61
2.4.4.4	Decalcification	61
2.4.4.5	Puffing.....	61
2.4.4.6	Cutting of the blocks.....	61
2.5	Immunohistochemical Staining	62
2.5.1	Basic principle.....	62
2.5.2	Staining Procedure	63
2.5.2.1	Preparation of the chemicals.....	63
2.5.2.2	Preparation	64
2.5.2.3	ABC - based indirect Immunohistochemistry	65
2.5.2.4	Antibody application	67
2.5.2.5	ABC complex & AEC Application.....	67
2.5.2.6	Counterstaining, Blueing & Mounting	68
2.5.2.7	Pictures	68
3	Results	69
3.1	Analysis of VEGF Labelling	69
3.2	Day 1	70
3.3	Day 3	72
3.4	Day 7	73
3.5	Day 14.....	75
3.6	Day 28.....	76
3.7	Day 82.....	77
3.8	Negative Controls.....	79
4	Discussion	81
5	References	84
6	Attachments.....	101
6.1	VEGF Immunohistochemistry Staining Protocol.....	101
6.2	Oral Presentation	103
6.3	Poster Presentation.....	104

Abbreviations

AB	Antibody
ABC	Avidin Biotin Complex
ACL	Anterior Cruciate Ligament
AEC	3 – Amino – 9 Ethylcarbazole
BW	Body Weight
Cbfa1	Core Binding Factor 1
ECM	Extra Cellular Matrix
EDTA	Ethylenediamine Tetraacetic Acid
g	Grams
HSC	Hematopoietic Stem Cells
kDa	kilo Dalton
L	Litre
mg	milligrams
mL	millilitres
µL	microlitres
mRNA	Messenger Ribonucleic Acid
NSAID	Non Steroidal Anti Inflammatory Drug
PLGF	Platelet Derived Growth Factor
sec	seconds
TNF alpha	Tumor Necrosis Factor alpha
VEGF	Vascular Endothelial Growth Factor
VEGF - R1	Vascular Endothelial Growth Factor Receptor 1
VEGF – R2	Vascular Endothelial Growth Factor Receptor 2

Figures

Figure 1: Anatomy of Long Bones (modified and translated from (3))	17
Figure 2: Enchondral Ossification (translated from (3))	19
Figure 3: Histological Image of the Growth Plate. Masson-Trichom Staining. Magnification: 20x	19
Figure 4: Salter Harris I Fracture(3)	30
Figure 5: Salter Harris II Fracture(3)	31
Figure 6: Salter Harris III Fracture(3)	31
Figure 7: Salter Harris IV Fracture(3)	32
Figure 8: 3D Image of the human VEGF protein (Image taken from NCBI Protein Database)	34
Figure 9: Activation Pathways of VEGF	35
Figure 10: Organigram of the Factors that influence the Expression of VEGF	36
Figure 11: VEGF Activation Pathway	39
Figure 12 Figure 13	56
Figure 14: Drilling of the hole with an electric drill	57
Figure 15: Mode of Operation of ABC-based Immunohistochemistry.(139)	66
Figure 16: Microscopic picture of the growth plate with a lesion. BM = Bone Marrow, L = Lesion, GP = Growth Plate. Anti VEGF Immunohistochemical Staining, Magnification 10x.	69
Figure 17: Microscopic Picture of the Growth Plate with a Lesion on Day 1. Anti VEGF Immunohistochemical Staining, Magnification 4x.	70
Figure 18: Microscopic Picture of the Growth Plate with a Lesion on Day 1. Anti VEGF Immunohistochemical Staining, Magnification 10x.	71
Figure 19: Microscopic Picture of the Growth Plate with a Lesion on Day 1.The Focus was set on the 4 adjoining columns of chondroblasts. Anti VEGF Immunohistochemical Staining, Magnification 20x.	71
Figure 20: Microscopic Picture of the Growth Plate with a Lesion on Day 3. Anti VEGF Immunohistochemical Staining, Magnification 4x.	72
Figure 21: Microscopic Picture of the Growth Plate with a Lesion on Day 3. Anti VEGF Immunohistochemical Staining, Magnification 20x.	72
Figure 22: Microscopic Picture of the Growth Plate with a Lesion on Day 7. Anti VEGF Immunohistochemical Staining, Magnification 4x.	73
Figure 23: Microscopic Picture of the Growth Plate with a Lesion on Day 7 Anti VEGF Immunohistochemical Staining, Magnification 20x.	73
Figure 24: Microscopic Picture of the Growth Plate with a Lesion on Day 14. Anti VEGF Immunohistochemical Staining, Magnification 4x.	75
Figure 25: Microscopic Picture of the Growth Plate with a Lesion on Day 14. Anti VEGF Immunohistochemical Staining, Magnification 10x.	75

Figure 26: Microscopic Picture of the Growth Plate with a Lesion on Day 28. Anti VEGF Immunohistochemical Staining, Magnification 10x.	76
Figure 27: Microscopic Picture of the Growth Plate with a Lesion on Day 28. Anti VEGF Immunohistochemical Staining, Magnification 20x.	76
Figure 28: Microscopic Picture of the Growth Plate with a Lesion on Day 82. Anti VEGF Immunohistochemical Staining, Magnification 4x.	77
Figure 29: Microscopic Picture of the bone bridge on Day 82 Anti VEGF Immunohistochemical Staining, Magnification 40x.	78
Figure 30: Microscopic Picture of the Growth Plate with no Lesion on Day 28. Negative Control Staining Staining, Magnification 4x.	79
Figure 31: Microscopic Picture of the Growth Plate with no Lesion on Day 28. Negative Control Staining Staining, Magnification 20x.	79
Figure 32: Microscopic Picture of the Growth Plate with no Lesion on Day 82. Negative Control Staining Staining, Magnification 20x	80

Tables

Table 1: Classification of Epiphyseal Fractures (modified after (51))	30
Table 2: List of Examples of diverse Functions of VEGF	47
Table 3: List of Rats organized in Groups	52
Table 4: List of drugs used in animal surgery	54
Table 5: List of Chemicals	60
Table 6: Preparation of the Chemicals	63

Abstract (English)

Introduction

Injuries to the growth plate may occur either as a result of trauma or as the consequence of the treatment of physeal fractures. These injuries can initiate the formation of bone bridges resulting in bone length discrepancy, axis deviation or joint deformity.

In this context, **V**ascular **E**ndothelial **G**rowth **F**actor (VEGF) is one important factor as it is one of the key players in angiogenesis, fracture healing and bone growth.

Aim

The aim was to investigate if VEGF is involved in the formation of a bone bridge after a trauma to the growth plate. After this was proven, the focus was set on the localization and the expression of VEGF in the fracture gap, its content and the chondroblasts of the growth plate at different points of time.

Materials and Methods

35 male Sprague Dawley rats at an average age of 4 weeks and a weight of 100g (+/-5g) were anaesthetized and an axial hole was drilled through the proximal growth plate of the tibia.

The animals were euthanized on days 1, 3, 7, 14, 28 and 82 and their left and right tibiae were extracted. Sections of the growth plate at the level of the lesion were stained with anti-VEGF antibodies using immunohistochemical methods. Sections of the growth plate of the other leg were used as controls and were stained and examined the same way. All sections were analysed under the microscope.

Results

On days 1 and 3, VEGF was strongly expressed in the fracture haematoma. The displaced bone bruise showed VEGF expression from day 1 until their remodelling on day 14. Thereafter, the trabeculae crossing the growth plate as well as the following bone-bridge also expressed VEGF, although this was limited to the surface of the trabeculae of the bone-bridge.

VEGF was not expressed in the first 2 to 4 columns of chondroblasts of the growth plate adjoining the lesion on day 1 and day 3.

Discussion

This study clearly documents that VEGF is involved in post-traumatic bone bridge formation of the growth plate.

Vascular Endothelial Growth Factor may be an important and even crucial factor for the healing of growth plate defects. Further investigation should be done on this topic, as it may be a target of therapy to prevent the formation of bone bridge bridges and its side effects in our already injured young patients.

Abstract (Deutsch)

Einleitung

Verletzungen der Wachstumsfuge können entweder als Resultat eines Traumas oder als Konsequenz der Behandlung von ebensolchen entstehen. Diese Verletzungen können die Bildung von Knochenbrücken initiieren, die Längenunterschiede, Achsenabweichungen oder Geleksdeformitäten nach sich ziehen können.

In diesem Zusammenhang spielt der **V**ascular **E**ndothelial **G**rowth **F**actor (VEGF) eine Schlüsselrolle in Angiogenese, Frakturheilung und Knochenwachstum.

Ziel

Das Ziel war es zu untersuchen, ob VEGF an der Bildung einer posttraumatischen Knochenbrücke beteiligt ist. Als der Beweis dafür erbracht war, wurde das Hauptaugenmerk auf die Lokalisation und die Entwicklung der Expression an den verschiedenen Zeitpunkten gelegt.

Material und Methoden

35 männliche Sprague – Dawley Ratten mit einem durchschnittlichen Alter von 4 Wochen und einem durchschnittlichen Gewicht von 100g (+/- 5g) wurden in Narkose versetzt und eine axiale Läsion in die proximale Epiphysenfuge der Tibia gesetzt.

Die Tiere wurden an den Tagen 1, 3, 7, 14, 28 und 82 euthanasiert und beide Tibiae wurden entnommen. Schnitte der Wachstumsfuge auf Höhe der Läsion wurden immunhistochemisch mittel Anti – VEGF Antikörpern gefärbt und unter dem Mikroskop analysiert. Schnitte der Wachstumfuge des anderen Beins dienten als Kontrolle und wurde auf die gleiche Art gefärbt und ausgewertet.

Resultate

VEGF wurde stark an den Tagen 1 und 3 im Frakturspalt exprimiert. Knochenfragmente zeigten ab Tag 1 bis zu ihrem Umbau/Abbau an Tag 14 ebenfalls starke VEGF Expression. Die folgenden Knochentrabeculae sowie die sich daraus entwickelnde Knochenbrücke zeigte ebenfalls VEGF Färbung; allerdings war diese auf die Oberfläche beschränkt.

An den Tagen 1 und 3 wurde VEGF nicht in den 2 bis 4 angrenzenden Knorpelsäulen der Wachstumsfuge exprimiert

Diskussion

Diese Studie zeigt klar, dass VEGF eine Rolle in der posttraumatischen Knochenbrückenbildung der Wachstumsfuge spielt.

VEGF könnte somit ein wichtiger und vielleicht sogar ausschlaggebender Faktor für die Heilung von Wachstumsfugendefekten sein. Weitere Untersuchungen dieser Problematik sollten durchgeführt werden, da dies ein möglicher Angriffspunkt einer Therapie zur Verhinderung von solchen Knochenbrücken und ihren Begleiterscheinungen bei unseren kleinen, bereits verunfallten, Patienten sein könnte.

Acknowledgement

To begin with, I want to thank everybody who was involved and who helped me in this big project of which my diploma thesis was only a small part.

Furthermore, I want to thank my family for supporting me during my studies.

Finally, I would especially like to thank my fiancée for always being my advisor, mentor, companion and partner – We have the whole world at our feet...

1 Introduction

1.1 The Growth Plate

1.1.1 Introduction

This chapter contains information on several aspects of the growth plate. Topics such as development, anatomy, physiology, injuries and healing processes will be discussed. Furthermore, molecular details and pathways of many functions of the growth plate will be provided.

1.1.2 Gross Anatomy

The physis, also known as epiphyseal plate or growth plate, is part of the epiphysis of long bone (Figure 1). It can be found at both ends with the diaphysis and the metaphysis lying in between. The diaphysis is made of a strong cortical bone that surrounds the bone marrow cavity containing trabecular bone and bone marrow cells. The physis itself is surrounded by a thin perichondral sheet.(2)

Other types are short bones, flat bones, sesamoid bones and irregular bones.(2)

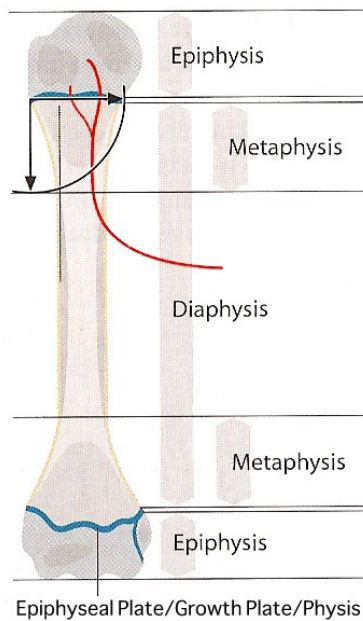


Figure 1: Anatomy of Long Bones (modified and translated from(3))

1.1.3 Bone and Growth Plate Development

Bone development begins with the condensation of mesenchymal cells. These mesenchymal precursor cells originate from the cranial neural crest, the paraxial mesoderm and the lateral plate mesoderm and gather at the same site. (4, 5)

Further bone development is done via two different pathways: Direct (intramembranous) or indirect (Enchondral) ossification(6-8)

1.1.3.1 Direct (Intramembranous) Ossification

Only a few bones of the human body originate from intramembranous ossification (e.g. the skull and the collarbone).

Mesenchymal cells transform directly into osteoblasts, which keep in touch with each other. They deposit osteoid while osteoclasts start to resorb needless tissue.

The end product of this process is called “woven bone”. During childhood, woven bone is replaced by lamellar bone.(8)

1.1.3.2 Indirect (Chondral) Ossification

Most of the bones of the human body are built via this process. The main principle is the transformation of a cartilage template into bone tissue.

- *Perichondral Ossification:*

Perichondral ossification takes place around the diaphysis of a cartilage template. Similar to intramembranous ossification, around the diaphysis a bone collar is directly formed by osteoblasts to protect the cartilage tissue. It represents the future layer of compact bone of mature long bones. (8)

- *Enchondral Ossification:*

This process starts in embryonic week 5-6 where mesenchymal cells condensate in the area of the future diaphysis (9) to transform into cartilage cells. The bone collar around the cartilage tissue is already built in embryonic week 8 creating thereby the primary centre of ossification, which initiates enchondral ossification. (8)

Enchondral ossification (Figure 2) is structurally organized in 5 zones:(6, 8)

- Zone of resting cartilage: Almost inactive hyaline cartilage
- Zone of proliferation: Chondrocytes with a high proliferation rate are arranged in columns to gain length
- Zone of maturation/hypertrophy: Cells enlarge and start to synthesize Collagen Type X
- Zone of mineralization: Cartilage cells undergo apoptosis and are removed by chondroclasts. Mineralization starts.
- Primary spongiosa zone: Vessel start to grow inward and attracted osteoblasts deposit osteoid which when calcified, forms trabecular bone

This process is done in both directions away from the diaphysis to gain length and to form a bone marrow cavity.

In the epiphysis, secondary centres of ossification appear, most of them after birth.

The growth plate is formed after formation of a secondary ossification centre at the epiphysis.

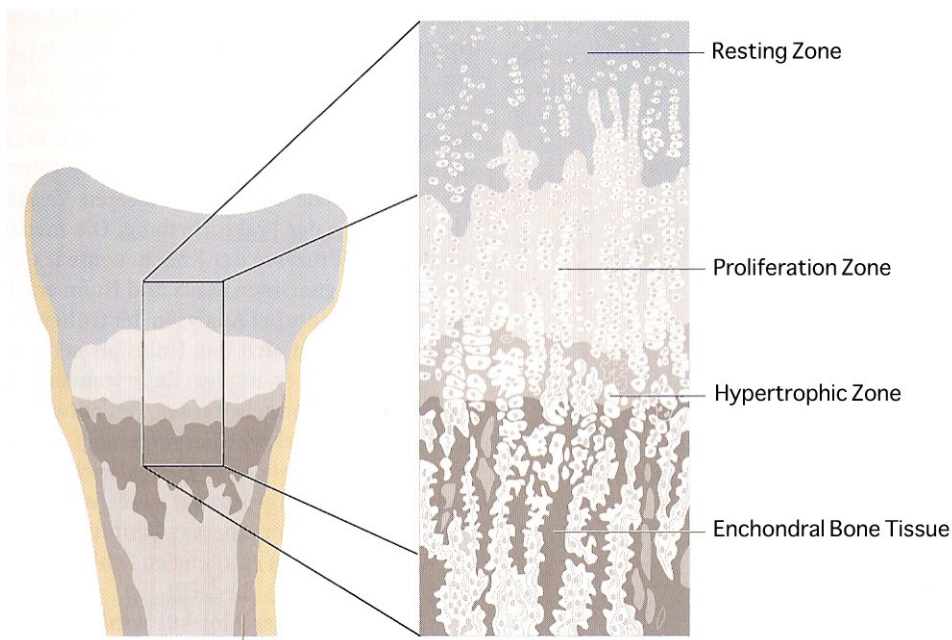


Figure 2: Enchondral Ossification (translated from(3))

1.1.3.3 Molecular Details

The cells of the growth plate run through 4 major stages of chondrocyte differentiation: mesenchymal precursor cells (MPCs), prechondrocytes, early chondroblasts and terminally differentiated chondroblasts (also referred to as chondrocytes).(10)

They are divided into 2 groups:

Firstly, the cells that are meant to participate in enchondral ossification turn on the runx2 transcription factor and start producing collagen, osteonectin, osteopontin and high loads of BMP-6. Secondly, MPCs that are designed to construct the growth plate, express great amounts of Sox family genes, especially of Sox9, that regulate the synthesis of Collagen type II, IX and XI. (11, 12)

Due to Sox9, the cells become rounder (=prechondrocytes) and all mesenchymal cell markers are turned off to prevent over-proliferation. (4)

In the next stage, prechondrocytes flatten in shape and start organizing in longitudinal columns. They proliferate rapidly, but then start to hypertrophy and undergo apoptosis. All steps are controlled, respectively influenced, by several factors (for details see Page 24, Chapter 1.1.5: Regulation) including Indian Hedgehog, Runx2, Runx3 and the Vascular Endothelial Growth Factor (VEGF).(13)

1.1.4 Microscopic Anatomy

1.1.4.1 Growth Plate

The growth plate or physis is a horizontal multilayer structure that is located between the epiphysis and the metaphysis of long bones (Figure 3). It is based on a simple principle: Chondrocytes proliferate as fast as that they are replaced by bone tissue resulting in length gain. As soon as the chondroblasts stop dividing, the growth plate ossifies and length growth is stopped.

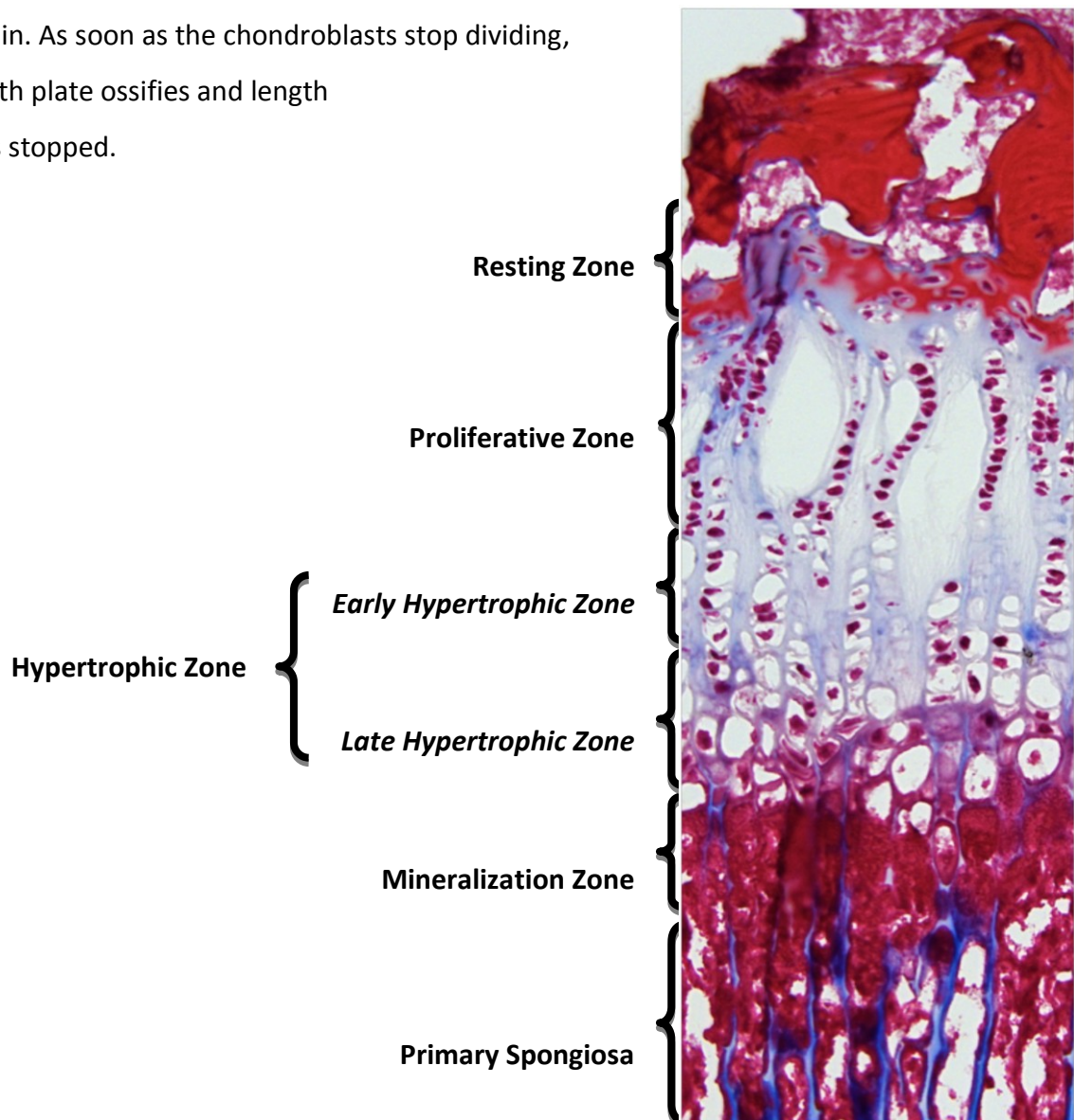


Figure 3: Histological Image of the Growth Plate. Masson-Trichom Staining. Magnification: 20x

The Growth Plate can be divided into 5 main horizontal layers (Figure 3):(8, 10)

- Resting Zone:
- Proliferative Zone
- Hypertrophic Zone (early and late Hypertrophic)
- Mineralization Zone
- Primary Spongiosa

In the following chapters all zones are discussed in details.

1.1.4.1.1 Resting Zone

The ratio of ECM to cells is relatively high in this zone. The cells are small, uniform and occur solitarily or in pairs. They are rich in lipid and cytoplasmatic vacuoles. These cells are almost inactive regarding mitosis and serve as a rescue pool for the proliferation zone(8, 10).

The ECM mostly consists of collagens, proteoglycans, non-collagenous proteins and water. The predominant form of collagens is Collagen type II. However, Collagen Type IX and XI are also found. Here, Aggrecan is the main proteoglycan and it is responsible for the osmotic resistance to withstand high compressive loads. Decorin and Biglycan are two smaller proteoglycans (e.g. Decorin serves as a regulator of collagen synthesis). Cartilage - oligomeric - protein is a calcium-binding non-collagenous protein and is an important part of the ECM.(14)

1.1.4.1.2 Proliferative Zone

In this zone, chondroblasts appear to be flat and organized in columns with high mitotic activity.(10) This is the zone where chondroblasts mature and prepare to enlarge.(8) Components of the ECM are almost the same as in the resting zone; only the expression of Collagen type II and XI is increased. (14)

1.1.4.1.3 Hypertrophic Zone

The hypertrophic zone is characterised by a massive increase in volume of the chondrocytes but with diminished proliferation rate.(13) They start to produce alkaline phosphatase, which is

responsible for the increase in crystalline hydroxylapatite molecules that are needed for the mineralization process. In the ECM, Collagen type II switches to short-chain Collagen type X.(15)

1.1.4.1.4 Degeneration/Mineralisation Zone

In this zone, Chondroblasts undergo apoptosis and macrophages are attracted.(8) This is where the process of mineralization takes place. It is initiated by excreted matrix vesicles, which contain Annexin V. It is activated by Collagen X to open a calcium channel to deposit calcium for mineralization.(14) They also contain different MMPs, which are responsible for the turnover of the cartilage matrix into a bone matrix. It induces the removal of Collagen type II by collagenases.(16) MMP-9 further attracts blood vessels through activation of VEGF which is also expressed by hypertrophic chondrocytes.(17) This is a crucial step for further development of bone tissue as sufficient blood supply is needed.

1.1.4.1.5 Primary Spongiosa Zone

Primary Spongiosa resembles the lower mineralization area.(10) Anyway, osteoprogenitor cells are present to build osteoid which will be transformed to lamellar bone as the growth process continues.(8)

1.1.4.2 Bone Tissue

Bone tissue is a type of connective tissue and therefore consists of the following 3 components: Cells, fibres and ECM.

ECM mainly contains hydroxylapatite crystals and Collagen I fibres whereas cells are multifaceted in their origin and function. Osteoblasts and osteocytes (=resting osteoblasts) are the tissue-constructing cells while osteoclasts that are derived from the mononuclear phagocytic system, are responsible for bone resorption.

In immature bone, collagen fibres are haphazardly woven ("woven bone") while in mature bone tissue they are arranged in sheets ("lamellar bone").

Macroscopically, 2 different forms of bone tissue can be differentiated: Trabecular and compact bone. In both cases, we deal with lamellar bone but in compact bone, the sheets are

arranged in concentric layers (“osteons”) while in trabecular bone, they are organized in of rod- and plate-like elements. (8)

1.1.5 Regulation

Two different systems that influence the function of the growth plate can be distinguished: Systemic and local factors.

Systemic factors comprise the Growth Factor (GF), Insulin-like Growth Factor (IGF) I & II, thyroid hormones T_3 and T_4 , glucocorticoids (GC) and sex hormones such as Oestrogen and the group of androgens.

Local factors are numerous, but only the most important ones will be discussed. Here, details will be given on Indian Hedgehog (Ihh), Parathormone-related Peptide (PTHrP), Fibroblast Growth Factor (FGF), the Bone Morphogenetic Protein-Family (BMPs), Vascular Endothelial Growth Factor (VEGF) and their interaction.

1.1.5.1 Systemic Factors

1.1.5.1.1 Growth Factor – Insulin like Growth Factor – Axis

Insulin-Like Growth Factors (IGF) I & II are said to be the key regulators of growth before birth. After birth, Growth Hormone (GH) together with IGF-I seem to have taken over this function. Overexpression of GH, as in case of pituitary adenomas, leads to gigantism or acromegaly.

In chondroblasts of the growth plate, GH acts on resting zone chondroblasts and is responsible for local IGF-I production, which stimulates the differentiation of proliferating chondroblasts. (18)

Mohan and colleagues(19) elegantly showed that “GH/IGF-I but not IGF-II was critical for puberty-induced bone growth. In addition, it was demonstrated that during pre-puberty the effect of IGF-I on bone accretion was mediated via GH-dependent mechanisms, whereas during puberty IGF-I exerts both GH-dependent and independent effects on bone accretion.” (20)

1.1.5.1.2 Thyroid Hormones

T₃ and its precursor T₄ are essential mediators of normal bone maturation. For example, in hyperthyroidism children grow faster and their growth plate fuses earlier whereas in hypothyroidism, growth is decelerated. (20)

T₃ and T₄ are able to stimulate the recruitment of resting zone cells and to ease the differentiation of growth plate chondrocytes. (21, 22) Furthermore, T₄ is able to induce the expression of Collagen Type II and X, alkaline phosphatase and to induce the hypertrophy of chondrocytes.(23)

Moreover, T₄ is able to restore disturbed growth plate architecture and to induce vascular invasion in hypothyroid rats.(24)

Both hormones also interact with the GH-IGF-System.(20)

1.1.5.1.3 Glucocorticoids

Numerous clinical conditions require glucocorticoid therapy in infants and juvenile which can lead to growth retardation.(25) This is consistent with observations that familial glucocorticoid deficiency leads to increased height.(26)

The direct effects on chondrocytes of the growth plate include inhibition of proliferation and matrix synthesis, increased rate of apoptosis of terminal hypertrophic chondrocytes, which leads to a decreased height of the growth plate.(27, 28)

Glucocorticoids also interact with the GF-IGF-System and the thyroid hormones T₃ and T₄.(20)

1.1.5.1.4 Oestrogen

Oestrogen is the most important hormone during puberty and is responsible for the closure of the growth plate (For further details, see Page 28, Chapter 1.1.5.3: Closure of the Growth Plate).

1.1.5.1.5 Androgens

The main effect of androgens, especially Testosterone, lies in modulation of pubertal growth and stimulation of length growth without alteration of bone age.(29) However, it is difficult to

distinguish between androgens and Oestrogen effects as the enzyme aromatase converts androgens to Oestrogen and therefore, masks its effects.

1.1.5.2 Local Factors

1.1.5.2.1 Indian Hedgehog

Indian Hedgehog belongs to the family of Hedgehog proteins which play an important role during embryonic development.(20) Here, Indian hedgehog is responsible for the pace of chondroblast proliferation and differentiation as well as osteoblast development.(20, 30)

„Ihh positively regulates PTHrP, which is sufficient to prevent chondrocyte hypertrophy and maintain a normal domain of cells competent to undergo proliferation. In contrast, Ihh is necessary for normal chondrocyte proliferation in a pathway that can not be rescued by PTHrP signalling.“ (31)

1.1.5.2.2 Parathormone-related Peptide (PTHrP)

PTHrP and its receptor (PTHrP-Receptor) play a crucial role in embryonic bone formation and longitudinal growth. Absence of PTHrP leads to accelerated chondroblast differentiation, which results in dwarfism. Accordingly, overexpression of PTHrP leads to inhibition of chondroblast differentiation also leading to shorter bones.

There is a model about how Ihh, PTHrP, FGF and BMP influence each other regarding the differentiation of chondroblasts from the stage of proliferation to the stage of hypertrophy.

Vortkamp and co-workers(32) and Lanske and co-workers(33) propose a model for a locally acting growth-restraining feedback loop, which controls the level of PTHrP in the growth plate.

In this model, “Ihh is expressed by chondrocytes making the transition from a proliferating into a hypertrophic phenotype. Ihh activates adjacent chondrocytes and diffuses toward the lateral perichondrium, where it can bind to its receptor Ptc. Via an as yet unknown mechanism, PTHrP production is stimulated in the peri-articular perichondrium. Then, PTHrP diffuses towards the pre-hypertrophic zone, which expresses high levels of PTH/PTHrP receptors and inhibits differentiation of proliferating chondrocytes to cells capable of synthesizing Ihh. Because Ihh and PTHrP are not expressed in close proximity to each other and the ECM surrounding

chondrocytes allows only limited diffusion of growth factors, intermediates may play a role between Ihh and PTHrP signalling and vice versa.” (20)

1.1.5.2.3 Fibroblast Growth Factors (FGF)

The Fibroblast Growth Factor family comprises 18 ligands that can dock to an overall amount of 5 receptors. They are secreted glycoproteins and major regulators of the embryonic bone development. (34)

As this family is very large, members fulfill different functions regarding bone growth that range from induction of ossification over to the expression of osteogenic markers and to the deceleration of the proliferation of chondroblasts.(20, 35)

1.1.5.2.4 Bone Morphogenetic Proteins (BMPs)

The BMP Family consists of 15 ligands and are part of the Transforming Growth Factor Family.(35)“BMPs have multiple important roles during later stages of cartilage development. BMP2, -3, -4, -5 and -7 are expressed in perichondrium, BMP2 and -6 are expressed in hypertrophic chondrocytes, and BMP7 is expressed in proliferating chondrocytes. “(35)

“BMP signalling increases the expression of Ihh by pre-hypertrophic chondrocytes, and so can increase both the proliferation of chondrocytes and the length of proliferating columns of chondrocytes. In both of these actions BMPs oppose the effects of FGF signalling to decrease chondrocyte proliferation and to decrease Ihh expression. Because BMPs and FGFs also have opposite effects on terminal hypertrophic chondrocyte differentiation, these pathways can be considered as antagonizing each other on several levels.”(35-37)

1.1.5.2.5 Vascular Endothelial Growth Factor (VEGF)

Enchondral bone formation is the essential step for the longitudinal growth of long bones and VEGF plays a crucial role in this process. The hypertrophic chondrocytes express VEGF that implicating that these chondrocytes induce blood vessel growth.(38, 39) Cartilage, that is avascular, depends on the supply by vascular/endothelial cell arcades, which are affiliated to the metaphyseal blood vessels.(40)

Blockade of VEGF does alter the process of ossification and longitudinal growth. The hypertrophic chondrocyte zone expands, the blood vessel growth is suppressed to almost undetectable levels leading to impaired bone formation. Though, the chondrocytes themselves appear to be normal in regards of differentiation, proliferation and maturation.

However, recruitment of chondroclasts expressing MMP9 is inhibited which prevents the resorption of chondroblasts. Additionally, apoptosis and mineralization of chondrocytes are diminished. Termination of the treatment restores the normal architecture within a short time.

(40)

In vitro, VEGF mRNA expression in osteoblasts is stimulated by administration of BMPs (Bone Morphogenetic Proteins) suggesting that osteoblasts also induces angiogenesis. (41)

Contrariwise, VEGF induces BMP-2 expression in endothelial cells. (43)

These results stand to reason that not only VEGF regulates the invasion of blood vessels into the growth plate but it also influences its appearance and remodelling. (14)

1.1.5.3 Closure of the Growth Plate

The maximum rate of longitudinal growth in humans can be found at med-gestational age. The rate constantly decreases until its cessation only interrupted by a brief so-called "growth spurt".(42) With age, a decrease in height of the growth plate with especially a decrease in number of proliferative and hypertrophic chondroblasts can be observed until the growth plate fuses.(42) There are hints that this process does not happen, as commonly thought, by means of apoptosis but rather by necrosis. (43)

Oestrogen is the key hormone that induces epiphyseal plate fusion (44). Its absence prevents fusion (45) whereas conditions marked by elevated Oestrogen levels cause premature closing. Recent research results suggest that Oestrogen does not induce ossification but rather accelerates the cell cycle of chondroblasts to finally reach the limited capacity of cycles. Hints for a predetermined number of cycles are given by growth plate transplantation where the growth rate depends on the age of the donor, not on the age of the recipient.(46)

1.1.6 Fracture Healing of Bones

1.1.6.1 Normal Fracture Healing in Children

Normal fracture healing in children involves the following 3 phases: (47)

1. *Inflammatory Phase*

The bone has lost its original structure and a haematoma containing large amounts of fibrin can be found in the fracture gap. Collagen synthesis as well as the production of cytokines that stimulate the differentiation of mesenchymal stem cells into chondroblasts, osteoblasts etc. is induced

2. *Reparative Phase*

New bone tissue is formed via intramembranous or enchondral ossification. Either method is meant to fill the gap until high quality bone tissue is formed.

3. *Remodelling Phase*

During this phase, the “placeholder” is replaced by high quality bone that can withstand physical forces. This process can take months or even years.

1.1.7 Injuries of the Growth Plate

Many different mechanisms can damage the growth plate, but only a few are common and will be discussed here: Fractures occurring during childhood that affect the growth plate, and surgical reconstruction of the anterior cruciate ligament (ACL), which resembles most the drilling procedure of this study.

1.1.7.1 Fractures

Fractures that affect the growth plate are generally classified according to either Aitken (48) or Salter-Harris(3):

Table 1: Classification of Epiphyseal Fractures (modified after (49))

Classification					
Salter Harris	I	II	III	IV	V
Aitken	-	1	2	3	4
	Lysis		Epiphyseal Fracture		

1.1.7.1.1 Classification

Salter-Harris I Injuries

=Complete dislocation of the epiphysis and the metaphysis. The fracture separates the hypertrophic from the mineralization zone(3) (Figure 4)

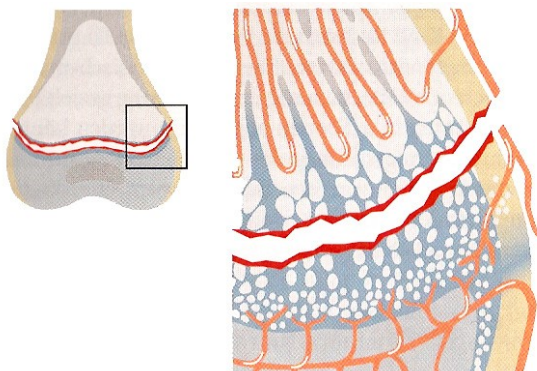


Figure 4: Salter Harris I Fracture(3)

Salter-Harris II Injuries

= Salter Harris I Fracture + Wedge of the metaphysis(3) (Figure 5)

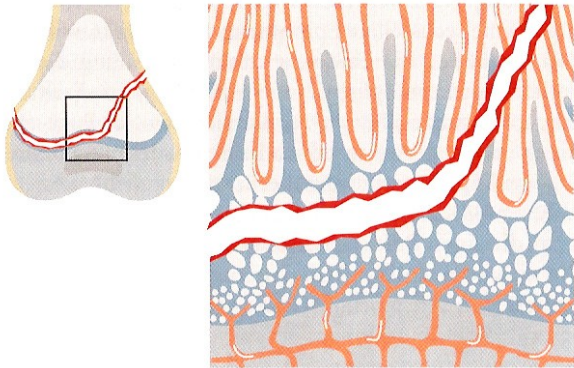


Figure 5: Salter Harris II Fracture(3)

Salter-Harris III Injuries

= Fracture in rectangular angle to the physis that involves the proliferation zone(3) (Figure 6)

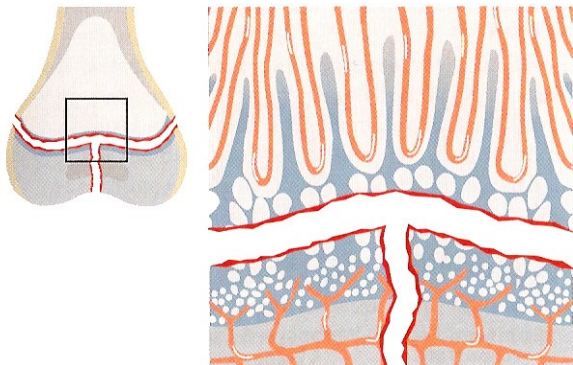


Figure 6: Salter Harris III Fracture(3)

Salter-Harris IV Injuries

= Fracture of the metaphysis, the physis and the epiphysis as well as the articular surface. This fracture involves the proliferating as well as the mineralizing zone.(3) (Figure 7)

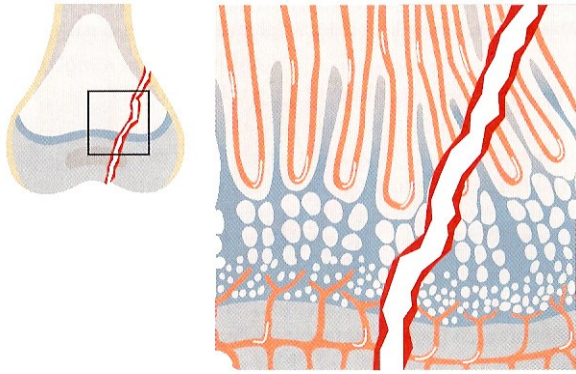


Figure 7: Salter Harris IV Fracture(3)

Salter-Harris-V Injuries

= Crush – Lesion caused by compression

It has only been proven to exist in animal experiments and is well discussed among experts.(3)

1.1.7.2 ACL Reconstruction

As a special case of injuries of the growth plate, the reconstruction of ruptured anterior cruciate ligaments will be discussed in this chapter. In some cases, the drilling of a hole through the growth plate is needed during this procedure to insert a graft to replace the ruptured ligament. From a clinical point of view, this is the procedure that resembles most the approach of the experiments of this diploma thesis to an injury of the physis.

In juvenile athletes with open physis, rupture of the anterior cruciate ligament occurs rather frequently.(50) In cases where stability of the knee cannot be reached by measurements of physical therapy, ACL reconstructive surgery is needed.(51)

There are certain techniques, which involve drilling through the growth plate. Complications of these procedures involve valgus deformity, length discrepancy and fusion of the growth plate leading to growth arrest.

Several animal models have been created to investigate the consequences of this procedure.(52-59)

1.2 Vascular Endothelial Growth Factor (VEGF)

1.2.1 Introduction

The Vascular Endothelial Growth Factor (VEGF) is one of the key players in angiogenesis and vasculogenesis. Many factors such as the Fibroblast Growth Factors (FGF) and Angiopoetins are involved in this process but no other than VEGF has the capability to induce blood vessel formation of this kind. Intensive research has been going on for decades to improve knowledge on this substance.(1)

1.2.1.1 Historical Background

Until 1981, several authors had been postulating that a tumor-derived factor that induces blood vessel growth must exist. (60) In the same year, Ferrara and co-workers discovered a mitogen in bovine pituitary follicular cells which they named "Vascular Endothelial Growth Factor" as its main target was the endothelial cell.(61)

A period of intensive research on VEGF began and several research groups have focused on further investigations on this topic since then.(60)

1.2.2 Gene

The gene coding for VEGF is located on the short arm of chromosome 6. (Chromosome 6p.21.3).(62)

It consists of 14kb (14 kilobases or 14.000 bases) (63) and which can be separated into introns and exons like any other gene.(64) In this case, 8 exons and 7 introns can be found. Different exons code for different isoforms of VEGF, e.g. VEGF₁₆₅ misses the exon 6. (63)

1.2.3 Isoforms

Alternative splicing of the pre-mRNA generates different isoforms of VEGF with also different functions. Currently, 7 isoforms are known which differ each other by length and function(63) which explains the origin of the nomenclature (e.g. VEGF₁₆₅, the most common isoform, consists of 165 amino acids).

This is a list of all 7 isoforms:(63, 65),(66)

- ✓ VEGF₁₂₁
- ✓ VEGF₁₄₅ (rare)
- ✓ VEGF₁₆₅ (most common form)
- ✓ VEGF₁₈₃ (rare)
- ✓ VEGF₁₈₉
- ✓ VEGF₂₀₆

Different isoforms exist in different forms in and outside the cells (e.g. VEGF₁₂₁ is secreted and freely soluble whereas VEGF₁₈₉ is bound to cell membranes and ECM (extra cellular matrix)).(67)

1.2.4 Protein Structure

A protein is a 3 dimensional molecular structure of more than 120 amino acids linked by peptide binding. Its natural alignment is called tertiary structure and can be seen in Figure 8. (64)

VEGF₁₆₅, the most common form of VEGF, is a homodimeric protein of 65kDa. The monomers are covalently linked by disulphide bonds at the end of a four stranded beta sheet to stabilize the dimeric protein.(68)

Receptor sites are located at the loops to facilitate the transphosphorylation of the receptor and this consequently enhances the signalling process (69). Loop I is the binding site for VEGF Receptor 1 while VEGF receptor 2 attaches to Loop III. (69)

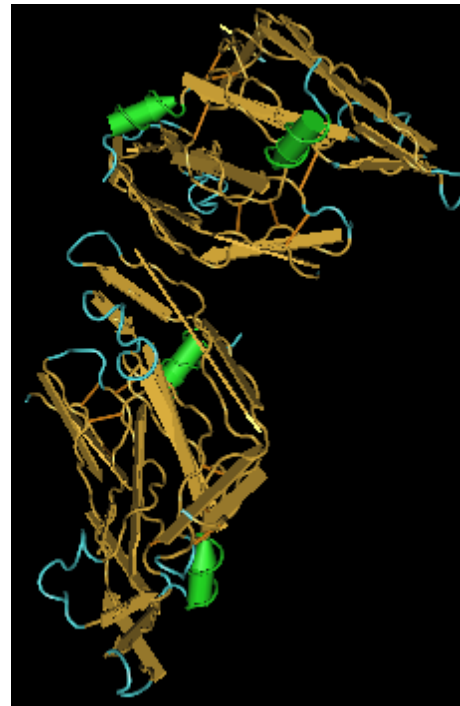

Figure 8: 3D Image of the human VEGF protein (Image taken from NCBI Protein Database)

1.2.5 Cellular Activation Pathway

Figure 9 shows the activation of the cell through binding of VEGF at the VEGF Receptor 2 receptor, which is said to be the primary signalling receptor for VEGF. It includes activation of the mitogen-activated-protein-kinase (MAPK), the phosphatidylinositol-3-kinase (PI3K), protein-kinase-C (PKC), which leads to increased endothelial proliferation, migration, survival and cell membrane permeability.(1, 70)

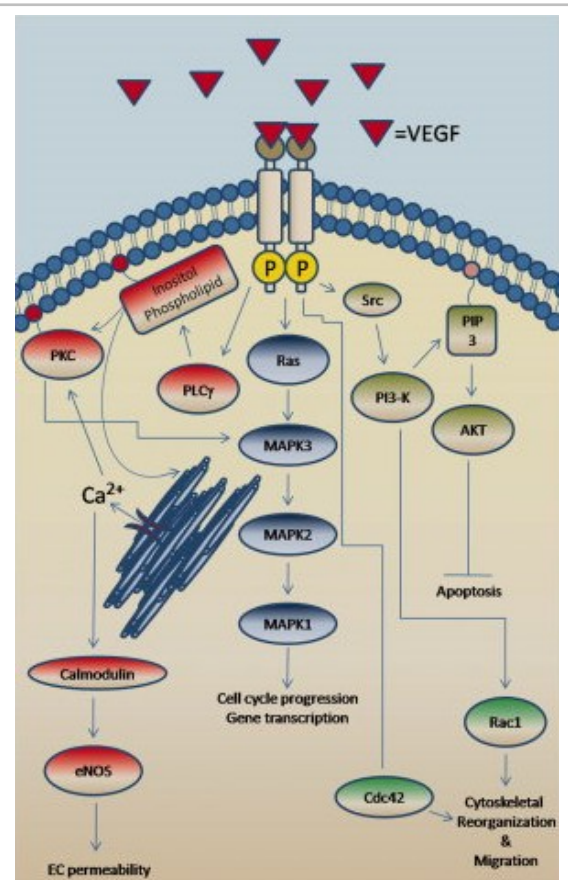


Figure 9: Activation Pathways of VEGF

via VEGF Receptor 2

(image taken from (1) with kind authorization of John Wiley and Sons)

1.2.5.1 VEGF related Proteins

VEGF-related proteins are substances which share parts of their primary structure, function or ability to bind to VEGF Receptors with the original VEGF-A also referred to as VEGF (e.g. PDGF (Platelet-Derived Growth Factor) shares 20% of its amino acid chain with the original VEGF protein(71)).

Here is a shortlist of VEGF-related proteins, but they are not discussed any further and are only touched briefly for the sake of completeness.(71)

- ✓ PDGF
- ✓ PlGF
- ✓ VEGF-B
- ✓ VEGF-C
- ✓ VEGF-D
- ✓ VEGF-E

1.2.6 Regulation

The expression of VEGF is regulated by various factors shown in Figure 10.

Some factors are explained separately in the following chapters.

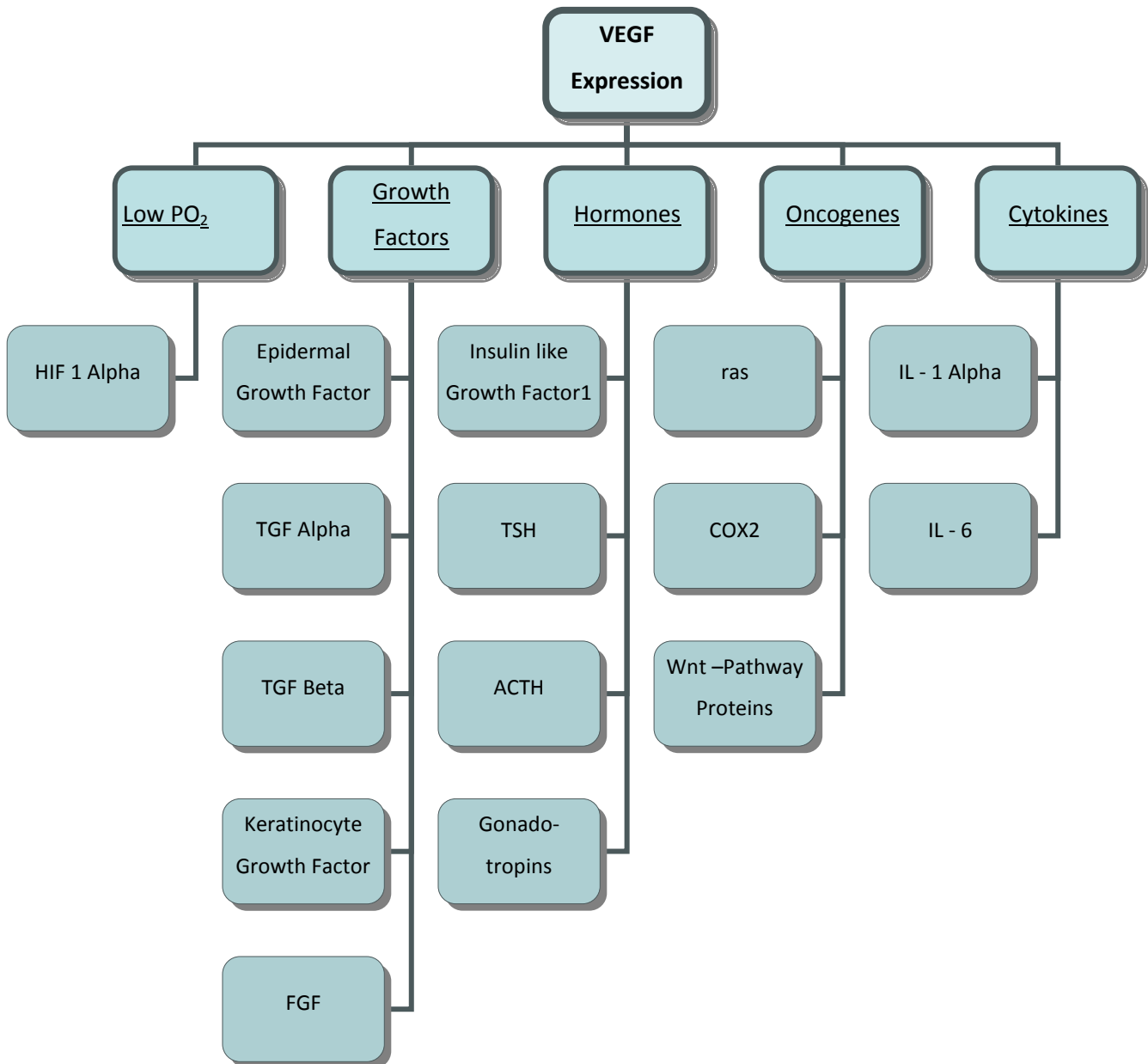


Figure 10: Organigram of the Factors that influence the Expression of VEGF

1.2.6.1 Oxygen tension

Oxygen tension plays a key role in the regulation of the VEGF mRNA expression. Low partial pressure of O₂ induces the production HIF 1 (Hypoxia Inducible Factor 1) that binds to specific enhancer elements which results in increased transcription of the VEGF gene.(72) The binding sequence shows a high degree similarity to the EPO gene (73) which is responsible for the

production of Erythropoietin, the hormone in the human body that regulates the amount of red blood cells in the human blood via continuous “measuring” of the partial pressure of O₂. (64) Thus, low partial pressure, which indicates an insufficient supply of oxygen and/or blood, is a signal to the body to increase the number of blood vessels or their diameter within this underserved region. This process is induced and maintained by, amongst other substances, VEGF via HIF as shown below.

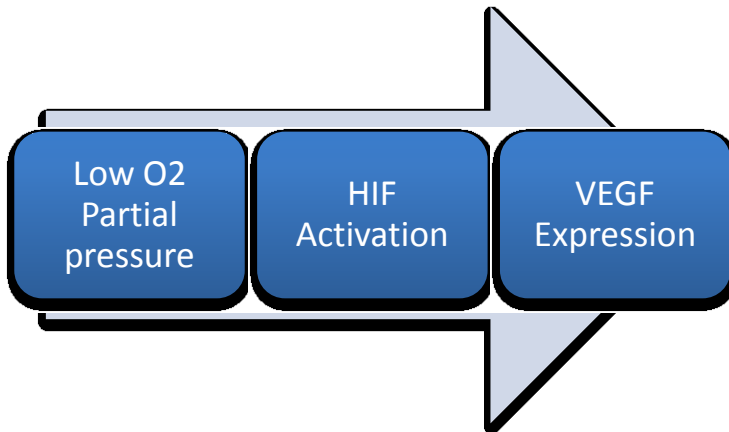


Figure 11: VEGF Activation Pathway

1.2.6.2 Core binding factor 1 (Cbfa1)

Cbfa1 (=Core binding factor 1; also called runx2 or Osf2 or AML3) is a transcription factor that regulates the expression of VEGF. It is needed by during enchondral bone formation where the invasion of blood vessels is needed for the absorption of hypertrophic chondroblasts. Up - regulation of Cbfa1 leads to increased expression of VEGF mRNA (76)

1.2.6.3 Bone Morphogenetic Proteins (BMPs)

„Bone Morphogenetic Proteins (BMPs) are multi – functional growth factors that belong to the TGF-Beta superfamily.“ (74) They are able to influence VEGF and its expression depending on the subtype and dose.

BMP -2, -4 and -6 leads to an increase of VEGFA in murine osteoblast – like cells. (75). Additionally, BMP – 2 is capable of transforming undifferentiated mesenchymal stem cells into chondrocytes and osteoblasts, which then can produce VEGF-A, VEGF-B and VEGF-C. The auxiliary up – regulation of VEGF Receptor 2 is yet another step to create a favourable environment for vascularisation. (76)

BMP – 7 augments the VEGF mRNA expression of osteoblasts by about three times and induces cell differentiation. (77)

1.2.6.4 Connective Tissue Growth Factor (CTGF)

CTGF is an essential regulator of the extracellular matrix of cartilage tissue. (78) In CTGF - deficient mice enchondral ossification is disturbed, which leads to dysmorphism of the skeletal bones. In such mice, a decreased level of VEGF mRNA is found in hypertrophic cartilage of the growth plate of long bones. This is where VEGF plays an important role in ossification and longitudinal growth, but Cbfa1 that normally controls the expression of VEGF in the hypertrophic cartilage at normal levels. This indicates that CTGF acts simultaneously or downstream of Cbfa1 in the activation cascade of VEGF.(79)

1.2.6.5 Matrix Metalloproteinase 9 (MMP 9)/Gelatinase B

„Homozygous mice with a null mutation in the MMP-9/gelatinase B gene exhibit an abnormal pattern of skeletal growth plate vascularisation and ossification.“ Although hypertrophic chondrocytes develop normally, apoptosis, vascularisation, and ossification are delayed, resulting in progressive lengthening of the growth plate to about eight times normal. After 3 weeks postnatal, aberrant apoptosis, vascularisation, and ossification compensate to remodel the enlarged growth plate and ultimately produce an axial skeleton of normal appearance. Transplantation of wild-type bone marrow cells rescues vascularisation and ossification in gelatinase B-null growth plates, indicating that these processes are mediated by gelatinase B-expressing cells of bone marrow origin, designated chondroclasts.“ (17)

1.2.6.6 Transforming Growth Factor - Beta 1 (TGF - Beta 1)

The capability of TGF - Beta 1 to induce the production of VEGF is known, but it has yet been understood to a minor degree only.(80) It is said to be involved in osteogenic activities but further details are to be investigated.

1.2.6.7 Hormones & Growth Factors

Several hormones and growth factors (for details see Figure 10) induce the expression of VEGF. All details on the role of VEGF in each of the pathways have not been not fully understood yet.

1.2.6.8 Oncogens

Mutations or specific transformation of several proteins (e.g. ras, COX2, proteins of the Wnt - Pathway) may lead to increase or decrease of the expression of VEGF. These facts are very important for the implication of VEGF in tumor growth, but no further information about its role in the cellular regulation of normal bone tissue can be given.(60)

1.2.6.9 Cytokines

Involvement of TNF alpha (Tumor necrosis factor alpha)(81), IL – 1 alpha and IL – 6 (65) suggest that VEGF plays a certain role in acute inflammation processes that has not been fully understood yet.

1.2.7 VEGF Receptors

Structures VEGF can attach to are found on different kinds of cells of the human body.

It mainly binds to two structures, VEGF-R1 (VEGF Receptor 1) and VEGF-R2 (VEGF Receptor 2) to which VEGF has a high affinity.

These two receptors are so-called tyrosine kinases. Each of them consists of “seven Ig - like domains in the extracellular domain, a single transmembrane region, and a consensus tyrosine kinase sequence that is interrupted by a kinase-insert domain.”(60)

Another member of this so-called “flt – Superfamily” is VEGF-R3 (VEGF Receptor 3) but VEGF does not bind to it.

Neuropilins serve as co-receptors for the main VEGF Receptors 1 and 2, as well as all members of the group of heparins.

1.2.7.1 VEGF Receptor 1 (KDR, Flt-1)

Two different forms of the VEGF-Receptor 1 exist: a cellular-membrane bound and a soluble form.(82) Both of them are regulated via the HIF 1 pathway that depends on hypoxia.(83) This is almost identical way VEGF is regulated. That this means the VEGF R1 gene shows similarities to a high degree to the VEGF gene in respect of the “docking region” of HIF 1.

VEGF receptor 1 is responsible for several functions of VEGF: When it is disabled such as in VEGF-R1 – deficient mice, they die on embryonic days 8-9 because blood vessels proliferate without limitation.(84)

In regard of angiogenesis, VEGF-R1 is now seen as a decoy receptor, which means that the functions of VEGF-R2 are minimized due to the fact that less VEGF is available.(65) Recycling or degradation of VEGF Receptor 1 allows greater activation of the signal processes of VEGF – Receptor 2. (85)

Both facts suggest that VEGF-R1 is a negative regulator of angiogenesis; however there are hints that VEGF-R1 also induces blood vessel growth but to a minor extent and not by direct influence on endothelial cells but rather by paracrine release of growth and/or survival factors.(86)

1.2.7.2 VEGF Receptor 2 (Flk-1)

VEGF Receptor 2 is a 230kDa glycoprotein (87) that plays the central role in the regulation of endothelial cells. It is the major mediator of the mitogenic, angiogenic and permeability-influencing effects of VEGF.(65)

It binds to all isoform of VEGF-A, to VEGF-C, VEGF-D and VEGF-F but not to VEGF-B and PLGF.(74)

VEGF Receptor 2 - deficient mice fail to develop blood vessels and also blood islands, which show the importance of VEGf-R2 in haematopoiesis.

1.2.7.3 VEGF Receptor 3

VEGF Receptor 3 is also a tyrosine kinase and a member of the flt - Superfamily, such as VEGF-R1 and VEGf-R2.

VEGF-C and VEGF-D but not VEGF-A are ligands to this receptor. It is expressed on lymphatic endothelial cells only. (88) So there is no effect on endothelial cells of blood vessels – thus, no implication in angiogenesis.

1.2.7.4 Neuropillins

Neuropillin 1 is an isoform - specific VEGF receptor, which, when it is co-expressed along with VEGF-R2, boosts the binding of VEGF to VEGF-R2 by enhancing the presentation of VEGF to the receptor. Furthermore, it augments the mitogenic activity of VEGF₁₆₅. (89)

1.2.7.5 Heparan Sulfate Proteoglycans

Heparan Sulfate Proteoglycans (HSPGs) are built of covalently linked heparan sulfate chains.(74) They influence a large number of secreted signalling molecules.(67) In case of VEGF, it serves as a co-receptor, respectively as an amplifier of the signal. It stimulates the VEGF – Receptor 2 turnover and increases the duration and amplitude of the VEGF Receptor signal.(90)

1.2.7.6 Heparin

Heparin is a sulfated glycosaminoglycane that is known for the ability to reduce blood coagulation.(91) Heparin is not a direct receptor to VEGF but it inhibits the binding between VEGF₁₆₅ and VEGF Receptor 2 and its autophosphorylation process. This effect is limited to VEGF₁₆₅. In experiments with VEGF₁₂₁ no such observation could be made. (92)

1.2.8 Function

VEGF is mainly known for its effects on endothelial cells, also called angiogenesis respectively vasculogenesis. Though, VEGF has multiple effects on different kinds of other cells of the body such as osteoblasts, chondroblasts, osteoclasts, chondroclasts, the mononuclear phagocytic system, dendric cells, HSCs and many more.

1.2.8.1 Endothelial Cells

VEGF affects endothelial cells in different ways. It influences growth, survival, vascular leakage as well as processes within the vessels.

VEGF induces growth in different kinds of endothelial cells. It's not only the endothelial cells of blood vessels, but also those of lymphatic vessels, which are stimulated to grow.(65, 93)

Furthermore, it promotes the survival of endothelial cells and it prevents apoptosis by inducing the expression of several proteins that prevent apoptosis.(94) When VEGF is blocked, endothelial cells cease to exist or at least, are diminished in number and diameter.(95)

VEGF induces vascular leakage, which plays an important role in inflammation processes.(96)

Moreover, VEGF has the ability to dilate blood vessels. This is not directly accomplished but NO (Nitrous Oxide) is needed to increase the diameter of the blood vessels, which increases the blood supply for the tissue beyond.(97)

In endothelial cells VEGF plays an important role in the activation of blood clotting and its inhibition. Beside other factors, it induces the plasma plasminogen activators and plasminogen activator inhibitor-1.(98). It can also "induce the expression of the only metalloproteinases that

can initiate degradation of interstitial collagen types I-III under normal physiological conditions.”(99)

1.2.8.2 Osteoblasts

The effects of VEGF on osteoblasts are diverse and of a complex nature.

VEGF is produced by osteoblasts as a result of stimulation by different substances, e.g. Insulin like Growth Factor I.(100) Additionally, VEGF has diverse direct effect on osteoblasts: It induces chemotaxis in primary human osteoblasts.(101) Moreover, it stimulates osteoblasts to differentiate and proliferate.(75) It can also initiate bone formation in organ cultures.(102)

Inhibition of VEGF by blockade with soluble VEGF Receptor 1 leads to decreased differentiation and diminished overall bone growth.(102)

1.2.8.3 Mesenchymal Stem Cells

Human mesenchymal stem cells derived from trabecular bone produce and react on stimulation of VEGF. They secrete VEGF in a differentiation manner during osteogenesis, whereas stimulation by VEGF induces mineralisation. Blocking of VEGF results in reduced mineralization suggesting that VEGF acts as autocrine and paracrine mediator for mesenchymal stem cells.(103)

1.2.8.4 Chondroblasts

VEGF has been implicated in cartilage maturation and resorption, shown several times by different authors.(40, 102, 104)

Inhibition of VEGF by soluble VEGF Receptor 1 leads to decreased cartilage formation and delayed chondrocyte resorption, but it is not certain if the results were be the same if Bone Morphogenetic Protein 4 was not present.(104)

However, in growing mice, VEGF inhibition leads to delay or inhibition of chondrocyte death without affecting its growth or maturation.(40)

1.2.8.5 Osteoclasts

Osteoclasts, which are responsible for the resorption of bone, are responsive to VEGF and express VEGF Receptor 1.(105) Osteoclasts are major cells required for normal resorption of bony tissue during enchondral ossification in embryologic development of long bones and in fracture repair.(106) Blockade of VEGF by soluble VEGF receptor 1 shows no or at least diminished resorption.(106, 107) It also enhances the activity of osteoclasts and keeps them alive. (108)

1.2.8.6 Haematopoietic System

Concerning monocytes and macrophages, VEGF acts similarly to its role in osteoclasts. In monocytes, it induces activation and migration.(109) Subsequently, it has interesting effects on the hematopoietic system: It is capable of initiating the formation of colonies of granulocyte/monocyte/macrophages - progenitor cells.(113)

Hematopoietic stem cells lacking the VEGF gene fail to repopulate irradiated hosts, which leads to the hypothesis that without VEGF, no repopulation of the bone marrow is possible.(110)

1.2.8.7 Other cells

Effects on other cells that are neither present in bone tissue nor in cartilage are multifaceted, but this is not surprising. VEGF plays an important role in many other tissues of the body due to its angiogenic capabilities. Though, many functions have not been discovered.

The following table (Table 2) provides a list of examples of functions of VEGF in other cells:

Table 2: List of Examples of diverse Functions of VEGF

Cell Type	Function	Author	Comment
Alveolar Cells Type II	Production of Surfactant	Compernelle et al, 2002 (111)	---
Dendric Cells©	Dendric Cell Development	Gabrilovic et al 1996(112)	---
HSCs	Production of B Cells	Hattori et al, 2001(113)	---
Schwann Cells	Invasion of Schwann Cells, mitogenic Effect	Sondell et al., 1999 (114, 115)	----

1.2.9 Role of VEGF in physiological Conditions

1.2.9.1 Embryonic and Postnatal Development

VEGF seems to be one of the key players in embryonic and early postnatal angiogenesis.(65, 116)

1.2.9.1.1 Embryonic development

Inactivation of a single VEGF allele results in death of the embryo between embryonic days 11 and 12.5. The embryos show several severe developmental defects that are incompatible with life (e.g. defective vascularisation of several organs or reduced nucleated blood cells.(117, 118))

Inactivation of the VEGF Receptor 1 - gene results in normal-shaped but unorganized endothelial cells with the consequent death of mouse embryos at mid-somite age.(119)

1.2.9.1.2 Postnatal Development

Partial inhibition of VEGF by targeting a single gene results in increased mortality, defective development of several organs and crippled bodies. Though, blockade of VEGF by soluble VEGF Receptor 1 achieves growth arrest and death due to kidney failure.(120)

In juvenile primates, VEGF blockade does not result in death or failure of organs but in growth arrest due to failed vascularisation of the growth plate of long bones.(121) For further details, see page 17, chapter 1.1.3: Bone and Growth Plate Development.

1.2.9.2 VEGF in Enchondral Bone Formation & Skeletal Growth

The topic has already been described on page 17, chapter 1.1.3: Bone and Growth Plate Development and it is mentioned here for the sake of completeness only.

1.2.9.3 Ovarian Angiogenesis

Growth of the Follicle and the Corpus luteum depend on sprouting of new vessels.(122) VEGF mRNA is temporarily and spatially related to the proliferation of new blood vessels in the ovary.(123) Blockade of VEGF results in delayed development of follicle and the corpus luteum.(124, 125)

1.2.10 Role of VEGF in pathological Conditions

This chapter only give a short overview about the implication of VEGF in tumor development and growth. A large number of researchers have dedicated their work to this topic. As tumors are not part of this diploma thesis it will only be touched briefly.

1.2.10.1 Solid Tumours

VEGF is present in almost every kind of tumorous tissue of the human body.(65) It is expressed in the tumor cells as well as in the stroma cells (60), and many tumor cells also secrete it.(126)

Clinical trials are going on with different kinds of inhibitors such as humanized monoclonal VEGF antibodies, a VEGF – Receptor 2 - antibody, small molecules inhibiting VEGF R2 signal transduction and soluble VEGF Receptors.(65)

1.2.10.2 Hematologic Malignancies

“VEGF is expressed in a wide variety of cell lines derived from various haematological malignancies, including T cell lymphoma, acute lymphoblastic leukemia, Burkitt’s lymphoma, acute lymphocytic leukaemia, histiocytic lymphoma, promyelocytic leukaemia, etc. (for review see Ref. 354). Expression of both VEGF - Receptors has been detected in some, but not all, leukemia cell lines, and VEGFR-1 was found to be more frequently expressed than VEGFR-2.”(60)

Treatment strategies that use VEGF or its receptors as a target are currently tested in clinical trials.(65)

1.2.10.3 Pathological Neovascularisation

Because of its nature the eye and especially its transparency is prone to be disturbed by newly built vessels. Affected region are the macula (age - related macula degeneration), the retina (retinopathy of the premature infant) and the vitreous body of the eye (Diabetic retinopathy with consequent neovascularisation of the vitreous body). Each of these medical conditions is linked to retinal ischemia, which increases the production of VEGF.

Therapeutic Anti VEGF - antibodies are commonly used in the treatment of macula degeneration in ophthalmology.(65, 127)

1.2.11 VEGF and the Growth Plate

1.2.11.1 Localisation and Expression

Details on the localisation and the expression of VEGF differ widely:

Petersen and colleagues and Carlevaro and colleagues claim VEGF to be expressed by hypertrophic chondrocytes only.(128, 129)

Garcia-Ramirez and colleagues, and Horner and colleagues and Evans and colleagues state that VEGF expression also extends to upper layers such as proliferative and resting zones.(130-132)

Also on the topic of VEGF mRNA expression opinions differ widely: Evans and colleagues purports that VEGF₁₂₁, VEGF₁₆₅ and VEGF₁₈₉ are expressed in the growth plate, whereas Petersen et al., 2002 could only identify VEGF₁₂₁ and VEGF₁₆₅.(128, 130)

Agreement has been reached on the localisation of VEGF – Receptor 2, which is found in hypertrophic chondrocytes only.(128-130)

2 Materials and Methods

2.1 Overview

The experimental part of this diploma thesis contains animal surgery, histological preparation of the samples and immunohistochemical staining of the Vascular Endothelial Growth Factor. In this chapter all procedures are explained in detail.

2.2 Authorization

The experiments were performed at the area of the Medical University of Graz, Austria. All actions were performed under the authorization of the Dean and of the Committee of Ethics of the Medical University of Graz under abidance of the Austrian animal protection laws (File Number: BMBWK-66.010/0054-BrGT/2006).

2.3 Animals

2.3.1 Sprague Dawley Rats

The Sprague Dawley rat is a breed of the albino rat commonly used as a laboratory animal in research.

An overall amount of 30 Sprague Dawley Rats at an average age of 4 weeks and an average weight of 100g (+/- 5g) were chosen as an animal model for the experiments. They were obtained from the "Institute of Laboratory Animal Knowledge and Genetics" („Institut für Labortierkunde und Labortiergenetik") in Himberg, Medical University of Vienna, Austria.

2.3.2 Housing

After the transport from Himberg to Graz, the animals were monitored by authorized staff of the 2 institutes mentioned below and they could acclimate for one week according to Austrian animal protection laws.

They were housed in special cages in 2 different places: Primarily, at the “Center for Medical Research” (Zentrum für medizinische Grundlagenforschung), Medical University of Graz (MUG), Stiftingtalstraße 24, 8010 Graz, Austria and secondarily, at the Institute of Biomedical Research (Institut für biomedizinische Forschung), Medical University of Graz (MUG), Hahnhof 48, 8036 Graz, Austria.

The rats were fed with normal tap water and special animal feeding pellets with free access to food and water during the whole period of time of the experiment.

2.3.3 Groups

The 35 rats were randomly divided in 6 groups. All animals of the same group (Table 3) were euthanized on the same day and housed in the same litter. Markings on the ears were set in order to be able to recognize the animals during and after surgery.

Table 3: List of Rats organized in Groups

Group Number	Number of Animals	Life Span (in days)	Left Tibia	Right Tibia
1	5	1	Lesion	Control
2	5	3	Lesion	Control
3	5	7	Lesion	Control
4	5	14	Lesion	Control
5	5	28	Lesion	Control
6	5	82	Lesion	Control

2.4 Surgery

2.4.1 Anaesthesia and Preparation

Firstly, the Sprague Dawley rats were moved to the operating theatre at the Institute of Biomedical Research, Hahnhof 48, 8036 Graz, Austria.

For anaesthesia, the animals were put into a mobile gas mixture unit connected to an oxygen supply and an adjustable vaporizer equipped with Isoflurane. Isoflurane is halogenated ether and is commonly used for inhalational anaesthesia(133). Isoflurane at a concentration of 2% was mixed with pure oxygen at a flow of 2 litres per minute to induce consciousness to facilitate the injection of anaesthetics, which were used to maintain this state.

A solution of Fentanyl Janssen©, (Fentanyl), Dormicum© (Midazolam) and Domidor© (Medetomidin) was injected subcutaneously (0.1ml per 100g of BW) to maintain anaesthesia and analgesia during the surgical procedure. As soon as a steady state of anaesthesia and analgesia was reached, the animals were put into the recovery position and the fur of the left leg was shaved completely using an electric shaver to minimize the risk of intra-operative infections.

2.4.1.1 Drugs

This list contains all drugs used in the experiments:

Table 4: List of drugs used in animal surgery

Trade name	Active Agent	Mechanism	Dose	Purpose
Domidor©	Medetomedine	α_2 -Adrenorezeptor-Agonism	0,05mg/100g of BW	Subcutaneous Anaesthesia
Dormicum©	Midazolame	Benzodiazepine	0,5mg/100g of BW	Subcutaneous Anaesthesia
Fentanyl©	Fentanyl	Opioid	2,5 μ g/100g of BW	Subcutaneous Analgesia
Furane©	Isoflurane	Halogenated ether	2% of inspirational air flow	Inhalational Anaesthesia

Antisedan©	Atipamazole	α_2 -Adrenorezeptor-Antagonism	0,25mg/100g of BW	Post operative Antigonisation of Anaesthesia and Analgesia
Annexate©	Flumazenile	Benzodiazepine Antagonism	0,05mg/100g of BW	
Narcanti©	Naloxone	Opioid Antagonism	0,12mg/100g of BW	

Novalgine Drops®	Metamizole	NSAID	10 gtt. per 100 mL of drinking water	Long term oral analgesia
Rimadyl®	Carprofene	COX 2 Inhibitor	1mg per rat	Post operative Analgesia
Betaisodona® Solution	Iodine Solution	Antiseptic Agent	---	Disinfection of operating field
NaCl-Fresenius®	0.9% Sodium Chloride Solution	Physiological Sodium Chloride Solution	---	Diluting agent

Trapanal ®	Thiopentale	Barbiturate	50mg per rat	Euthanasia

2.4.2 Operation

The narcotised animals were transferred to the operating table and handed over to the surgeon. First of all, the left leg was washed several times using a Betaisodona® Iodine solution to decrease the risk of infections.

After proper contact time of the disinfectant, the surgeon fixed the right leg. A longitudinal cut through the skin was performed with a scalpel at the level of the knee joint. Special attention was paid to the depth of the cut not to damage any tissue surrounding the knee joint. Further preparation of the tissue and opening of the knee joint was done using surgical scissors without destruction of the structures of the knee.

The thigh was brought into an upright position to facilitate the drilling process and the knee joint was bent to open the angle to allow the drill to be applied on the centre of the upper surface of the tibia plateau (Figure 12, Figure 13)

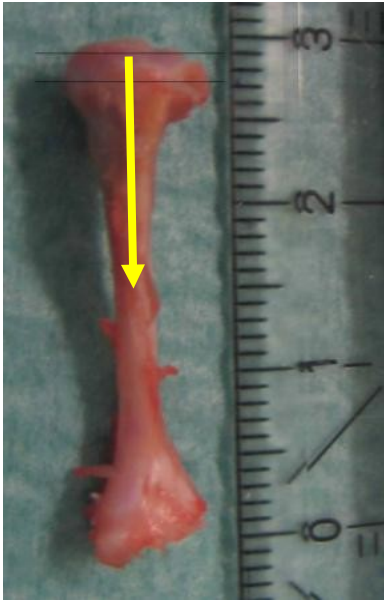

Figure 12

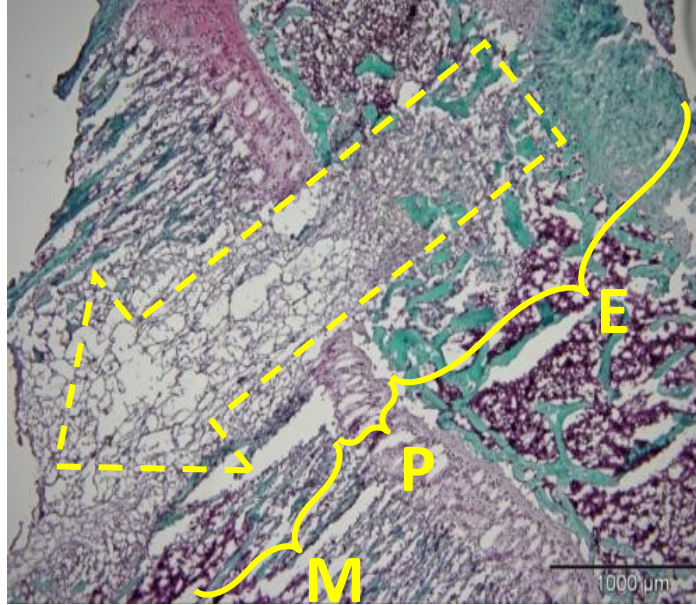


Figure 13

Figure 12: Photo of left tibial bone from a 4 week-old Sprague-Dawley rat. A physeal injury of the proximal tibial physis was caused through advancing a drill from proximal towards distal along the yellow arrow. The dotted line marks the borders of the growth plate.

Figure 13: Histological picture of the area around the growth plate including the central lesion(dotted yellow arrow) and the direction of the drilling (dotted yellow arrow). Physis marked by "E", Epiphysis marked by "E", and metaphysis marked by "M". Safranin O Staining, Magnification: 4x.

A drill with the diameter of 1.2mm was driven axially through the plateau of the left tibia, the epiphysis (E), the physis (P) and the metaphysis (M) until the bone marrow cavity was reached (Figure 12, Figure 13, Figure 14). As soon as the drill had been removed, exiting bone marrow could be observed. This was regarded as a proof that the advancement of the drill was accurate. Special attention was paid not to exit the bone marrow cavity at any other side or not to cause any unnecessary destruction of the growth plate by inadequate handling.

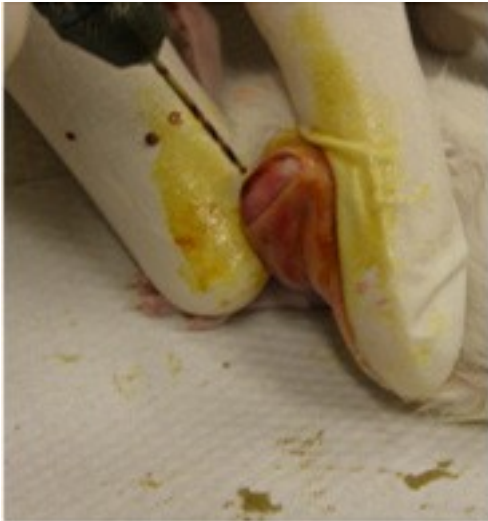

Figure 14: Drilling of the hole with an electric drill

The exiting bone marrow as well as blood of any kind was dabbed with a sterile swab and the operating field was disinfected again before suturing. The wound was closed in layers using non-absorbable Vicryl 5-0 with several simple interrupted sutures. Earlier experiments of our research group revealed that no bandage was necessary. Instead, a final Betaisodone© Iodine solution wash was performed.

2.4.3 Recovering and post-operative Surveillance

After the surgical procedures were finished, an antidote solution of Annexate© (Flumazenile), Narcanti© (Naloxone) and Antisedan© (Atipamazole) (dose can be obtained from Table 4) was injected into to peritoneal cavity to antagonize the anaesthetics.

As Naloxone blocks opioid - induced analgesia(133), 1mg of Rimadyl© (Carprofene©, NSAID) was injected into the subcutaneous tissue of the neck to grant post-operative analgesia for the next 24 hours. This procedure was repeated once a day for first post-operative week (see below).

The rats were put in recovery position and were placed on a heating plate not to suffer from hypothermia. The staff monitored them until their return to full consciousness. Then, they were put back into their litters and brought back to the animal housing unit.

Follow-up pain management was accomplished as follows:

- 1.) *First 7 Days:* Subcutaneous injection of
1mg of Rimadyl© (Carprofene) once a day
- 2.) *Following 14 days:* 100ml of drinking water enriched with
Novalgine© Drops containing 250mg Metamizole ad libitum
- 3.) *After 21 Days:* No pain medication necessary

2.4.4 Tissue Harvest

2.4.4.1 Chemical Products

This list contains all chemical products used in the experiments except for drugs (for drugs, see Table 4). It provides their common name, chemical compound, purpose and the manufacturer.

Chemical Product	Further information	Purpose	Manufacturer
PBS	Phosphate buffered Saline	Wash buffer	Own production
Tween	Non ionic detergent	Reduces hydrophobic and non specific interactions	Merck
H ₂ O ₂	Hydrogen Peroxide	Blocks endogenous peroxidase	Merck
Dako Antibody Diluent	Diluting medium	Dilutes concentrated Antibody solutions	Dako
Goat Serum	Blood serum of same species as secondary antibody	Decrease of cross reaction of primary antibody	ZMF
Anti VEGF Antibody	Primary Antibody ex chicken	Specific binding to VEGF	Abcam Corp.
Anti Chicken Antibody	Biotinylated anti chicken antibody ex goat	Specific binding to primary antibody	Vector Laboratories
ABC Complex	Avidin-Biotin Complex	Link between secondary antibody and chromogen	Vector Laboratories
AEC Solution	3 – amino –	Red Chromogen	Dako Corp.

	9 ethylcarbazole		
Mayer's Haemalum	Haemalum Solution	Counterstaining	ZMF
Ammonia Water	Ammonia + H ₂ O	Bleuing of counterstained slides	Own production
Kaiser's Glycerol Gelatine	Gelatine	Mounting medium	Dako
Distilled Water	Pure Water	Diluting medium	ZMF
EDTA	Ethylenediamine tetraacetic acid	Chelating agent	ZMF
Methanol (100%)	CH ₃ -OH	Fixation Medium	ZMF
PBS sucrose Solution (5%)	Puffing medium	Prevents freeze cracks of the tissue	Own production
Tissue freezing Medium		Embedding of the tissue prior to cutting process	ZMF

Table 5: List of Chemicals

For the preparation of any chemical see Table 6.

2.4.4.2 Extraction

According to the groups 1 to 6 (see Table 3) the animals were brought to the operating theatre on post-operative days 1, 3, 7, 14, 28 and 82.

. As soon as the animals had reached a steady state of anaesthesia, a previously prepared 2mL syringe with a 30 – gauge needle was inserted in the heart via a sub-xyphoidal access to the pericardium and the heart. As soon as the needle had entered one of the 2 ventricles of the heart, 2mL of blood were drawn with a syringe for the purpose of examination of serum IL-6 levels (not part of this diploma thesis).

After the withdrawal of the blood samples, 50mg of Trapanal (Thiopentale) dissolved in physiological Sodium Chloride solution (0.9%) were injected into the heart to cause painless cardiac arrest under general anaesthesia.

The two tibiae (left tibia with lesion, right tibia with no lesion=control) were extracted and all dissected soft tissue was removed from the bones with caution not to damage structure.

2.4.4.3 Fixation

The bones were quick-frozen with liquid nitrogen (Temperature: -196°C) to preserve the structure for future tests.

The frozen sample material was put into small glass container with methanol (100%) for 24 hours.

2.4.4.4 Decalcification

After 1 day all bones were wrapped in mull and stored in different containers with an EDTA (Ethylenediamine Tetraacetic Acid) Solution. EDTA is a water-soluble chelating agent and able to form complexes with metal ions such as Ca^{2+} .(138) As bone contains hydroxyl apatite ($\text{Ca}_{10}(\text{PO}_4)_6(\text{OH})_2$), EDTA is prone to extract the calcium ions from the bone, which turns a hard tissue into a soft tissue. This transformation into a sliceable tissue is an essential step towards cutting the bony tissue into slices of a thickness of 7.5µm.

The EDTA solution was changed every day for 2 weeks. Thereafter, the bones were again put in a container with Methanol 100% for another 12 hours.

2.4.4.5 Puffing

In order to get puffy cells in the cryo-sections and to be able to freeze the tissue without frost cracks, it was important to store the samples in PBS-Sucrose solution and to wash out the methanol. The samples were left in the PBS Sucrose 5% solution for 12h. Special attention was paid to bacterial or fungal growth which would have required a rewash in methanol and which would have diminished the quality of the staining, but no such thing occurred.

2.4.4.6 Cutting of the blocks

The still entirely conserved bones were removed from the PBS Sucrose Solution and dried for a short time. The bone was shaped at the level of the upper third of the diaphysis at a right angle

with a scalpel resulting in a bloc extending from the surface of the tibial plateau to the diaphysis. This bloc was placed in a tiny bowl containing tissue - freezing medium. The bowl was placed on a freezing plate at -18°C and orientated in a sagittal plane of the bone for later cutting of the sections. As soon as the medium was completely frozen, it was removed from the bowl and placed correctly in the cryo-microtome. Trimming of the tissue of the left tibiae was done until the correct level of the bloc was reached. The corrected level was defined as a plane cut through the growth plate with a central lesion and the extending drilling channel, which was confirmed under the microscope. From that time on, sections of a thickness of $7.5\mu\text{m}$ were cut and placed on glass slides. Always 2 sections were positioned one next to the other to ensure that the negative control section of the immunohistochemistry staining always corresponded. For the right tibiae, the correct plane was defined as the middle of tibia head in a frontal or sagittal plane.

All slides were labelled and organized in boxes according to their group and number within the group.

They were stored at -20°C in an upright freezer until their usage.

2.5 Immunohistochemical Staining

2.5.1 Basic principle

Immunohistochemistry is based on simple principle: An antibody binds specifically to a host antigen displaying the site of localisation (see in Figure 15)

An antibody is a protein produced by plasma cells in the blood(64), which has the ability to bind a special protein for which it was designed for, in our case VEGF in the tissue of the growth plate and the lesion. Antibodies are too small to be visible to the human eye, and additionally, they are transparent. Thus, the target structure needs a label to be seen by the viewer. So they are marked either directly (*direct method*) or it is bound by another antibody that has been specially designed to be marked by a chromogen (*indirect method*).⁽¹³⁴⁾

“The sensitivity of the indirect method is higher than a direct method because

1) the primary antibody is not labelled, retaining its activity and resulting in a strong signal and

2) the number of labels (e.g., peroxidase) per molecule of primary antibody is higher, increasing the intensity of reaction.

The result is the ability to detect smaller amounts of Ag or to increase the dilution of the primary antibody because at least two labelled antibodies can bind each primary Antibody molecule. “(135)

A chromogen is a chemical substance that is colourless unless it is oxidised, e.g. by a substance attached to the secondary antibody. Then it turns into a certain colour and can now be localised easily (135) under a microscope or even with the vision of the eyes only.

2.5.2 Staining Procedure

2.5.2.1 Preparation of the chemicals

All chemicals were exactly prepared as stated below. Before the first step of staining all chemicals were prepared not to exaggerate the time limits during the staining procedure (except for ABC Solution).

Table 6: Preparation of the Chemicals

Substance	Ingredients	Comment
PBS – Tween 20© Solution at pH 7.4	For 1L 1L of distilled water 0.32.g of monobasic sodiumphosphate 1.42g of dibasic sodiumphosphate 9g of Sodium Chloride 1mL of Tween 20©	Store at 4°C
PBS Sucrose Solution (5%)	For 1L 1000mL of PBS 50g of Sucrose	
H ₂ O ₂ Peroxidase blocking Solution (0.3%)	For 100mL: 100mL of PBS	

		1mL of 30% H ₂ O ₂	
Ammonia Water		For 1L: 1L of distilled water 1mL of 25% Ammonia Solution	
Goat Serum Solution		For 1 Slide/100μL: Dilution at 1:20 95mL of PBS – Tween – Solution 5μL of Goat Serum	
Primary Antibody Solution		For 1 Slide/100μL: Dilution at 1:100 99μL of Dako AB Diluent Solution 1μL of Primary Antibody Abcam 14078	Polyclonal anti VEGF antibody ex chicken
Secondary Antibody Solution		For 10 Slides/1mL: Dilution at 1:600 998,33μL of Dako AB Diluent solution 1,67μL of Secondary Antibody	Polyclonal anti chicken antibody ex goat
ABC Complex Kit Solution		For 10 Slides/1mL: 960μL of PBS - Tween 20 – Solution 20μL of Substance A of ABC Kit 20μL of Substance B of ABC Kit	Storage at 4°C for 30 min before application
Kaiser's Gelatine	Glycerol	For 1 glass: 40g of Gelatine 210 mL of distilled water 250 mL of Glycerole 5mL of Phenole	Preheating to 50°C before application
Ammonia Water		For 1L: 999ml of distilled water 1ml of 25% Ammonia Solution	

2.5.2.2 Preparation

At first, the slides were unfrozen at room temperature (20°C) for 60 min. They were organized in racks and covered with a lid to prevent them from dehydration.

Secondly, they were put into a container filled with PBS - Tween 20© Solution for 5 min for rehydration purpose. This was followed by a bath in H₂O₂ Peroxidase blocking Solution (0.3%)

to block endogenous peroxidase activity, which would cause uncontrolled oxidation of the chromogen.(134, 135) This unspecific colourisation of the tissue would have altered the result.

After 15min the blocking was ended and the racks were placed in PBS - Tween 20© Solution 3 times for 2min each to wash off the blocking solution.

A DakoPen©, a liquid repellent for slides, was used to draw circles around the section to limit the amount of antibody that had to be used. Additionally it prevented the fluids of the 2 sections from mixing up while they were transported or when it was impossible to store them horizontally.

The slides were placed in a special box and 100µL of Goat Serum was applied on each section with a pipette (Eppendorf, Vienna, Austria) for one hour at room temperature. Serum from the same species as the secondary antibody's host species is meant to intercept secondary antibodies that do not bind to primary antibodies which would have caused unspecific staining.(135)

Finally, the goat serum solution wasn't washed off the slides as all the other liquids. The slides were just knocked on the table to get rid of the excessive amount of fluid.

No antigen retrieval was necessary prior to the application of the antibody solutions as cryo technology was used to conserve the tissue – no substance, e.g. paraffin, blocked any epitopes.

2.5.2.3 ABC - based indirect Immunohistochemistry

In this case the indirect method of immunohistochemistry with the help of an avidin biotin complex system was chosen.

It binds specifically to an antigen (dark blue "V") that is located in the tissue you want to examine. As already mentioned you cannot observe it, so it has to be marked. In this case, a biotinized secondary antibody in combination with an Avidin Biotin complex system together with a chromogen (AEC, of red colour) was used to make it visible.

The ABC Complex System contains avidin (red "X"), biotin (the same substance the secondary antibody is connected to; light blue triangle) and horseradish peroxidase (purple circle). Avidin is a 68.000 molecular weight glycoprotein extracted from egg white with an extremely high

affinity for the vitamin “Biotin” at its 4 binding sites.(136) The strength of this affinity is over one million times higher than that of a normal antigen-antibody connection and additionally, it is irreversible. (136, 137)

The Vitamin Biotin has one binding site for Avidin, the others can be used for horseradish peroxidase. Horseradish Peroxidase, which is isolated from the horseradish root, has the ability to oxidize chromogens, which makes them visible. It can be conjugated to biotin via their amino group via a two-step method. (134)

AEC (3 – amino – 9 ethylcarbazole), the chromogen, is an electron donor which is invisible but when oxidized it turns red.(134) Oxidization process is done by the horseradish peroxidase as mentioned above.

This aspect provides the potential of a macromolecular system that connects primary antibodies to biotininated secondary antibodies, cross links biotininated secondary antibodies to avidin and other horseradish peroxidase coupled biotin molecules and at last, the chromogen.

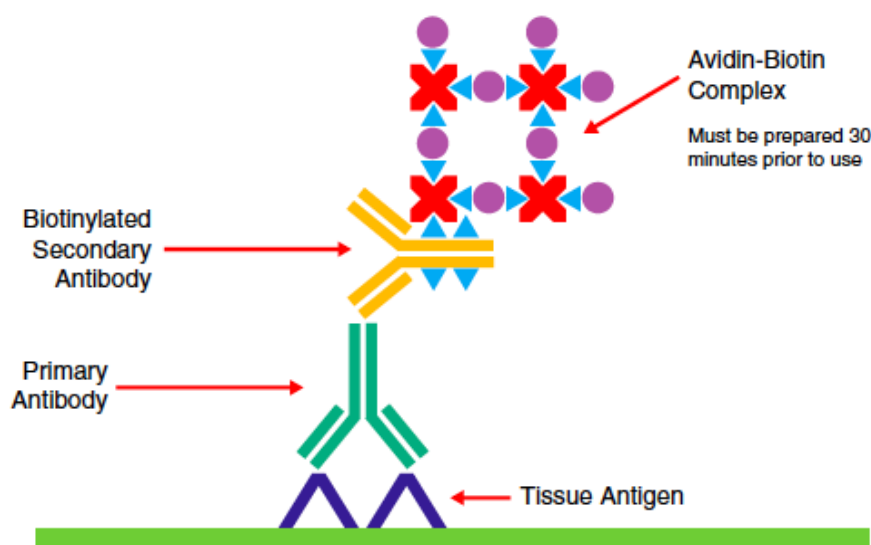


Figure 15: Mode of Operation of ABC-based Immunohistochemistry.(134)

Description of the Figure: Tissue Antigen=dark blue „V“, Primary Antibody= green „Y“, Secondary Antibody=yellow „Y“, light blue triangle=Biotin, Red „X“=Avidin, purple circle=Horseradish peroxidase.

2.5.2.4 Antibody application

The slides were organized in a special box with a lid to protect them from sunlight. 100µL of the primary antibody solution (for preparation see Table 6) were applied always on the left section of the slide.

The primary antibody solution contained a polyclonal chicken anti VEGF antibody dissolved in Dako Antibody Diluent© Solution at a dilution of 1:100. The anti-VEGF antibody binds specifically to the VEGF (=Antigen) that is present in the tissue.

The right section was treated with 100µL of PBS solution only to serve as control section. The box was shut with a lid and stored for 24 hours at 4°C in a refrigerator room.

After 24 hours, all slides were washed in PBS - Tween 20© Solution 3 times for 2min each to get rid of the primary antibody solution. The secondary antibody solution contained a biotinated polyclonal anti chicken antibody ex goat that was designed to bind antibodies that were bred in chickens (here: primary antibody ex chicken). It was dissolved in Dako Antibody Diluent© Solution at a dilution of 1:600 and it was applied on all sections and left there for 30 min at room temperature (+20°C).

2.5.2.5 ABC complex & AEC Application

As soon as the secondary antibody was applied, preparation for the ABC Solution started. For 10 sections 960mL of PBS – Tween 20 Solution, 20µL of Substance A of ABC Kit and 20µL of Substance B of ABC Kit were mixed and 100µL of the mixture were applied on each section. The slides were again stored in a box with a lid, which protected them from light at 4°C in a refrigerator.

After 30min all slides were washed in PBS - Tween 20© Solution 3 times for 2min each to get rid of ABC Complex Solution. Now 2 drops of AEC solution (=Chromogen) were admitted to each section with special attention neither to exceed the time limit of 2min 50 sec nor to expose it to light during this time.

After 2 min and 50 sec the reaction was stopped with the help of distilled water in a glass container. After 30 seconds the liquid was changed and the slides remained in the distilled water for another 3 minutes.

2.5.2.6 Counterstaining, Blueing & Mounting

After the reaction had been stopped in distilled water, the slides were dipped into Mayer's Haemalum Solution. After 15 sec, they were removed from the bath and put into a container filled with hand warm tap water. In order to ensure permanent removing of spare Mayer's Haemalum Solution, the water was changed continuously.

The rack was removed from the water and put on a towel to allow the excessive water to drip . Afterwards, the rack was placed in a container filled with Ammonia Solution for a few seconds to blue the counterstaining before it was put in distilled water again.

Now, the staining process was finished. To conserve the sections for further analysis, cover glasses were mounted using Kaiser's glycerol Gelatine that had been preheated to 50°C to liquefy it.

A non-alcoholic mounting medium was necessary as AEC was used as chromogen. If AEC is used in an alcoholic medium, the end product (here: the red colour on the sections) will disappear as it is alcohol – soluble.(134)

2.5.2.7 Pictures

The slides were analysed under the microscope using an Olympus BX51 microscope and a DP71 camera (Olympus Inc., Center Valley, PA).

3 Results

3.1 Analysis of VEGF Labelling

All slides were analysed under the microscope and then photographed. All areas than contain VEGF are coloured in red whereas all the other tissues such as the bone marrow, cell nucleus and bone tissue are coloured in blue

The focus of analysis was set on the lesion and the adjacent physis. The growth plate itself was examined, but due to the heterogeneous result of VEGF, it could not be analysed as exactly as the lesion and its content.

Some facts remain the same throughout all the images: The resting zone remains negative, whereas the hypertrophic and mineralizing zone are always positive for VEGF. Above the resting zone, a red boarder can be found. There is always the lesion in the middle, only the content changes with the different evaluated time points.

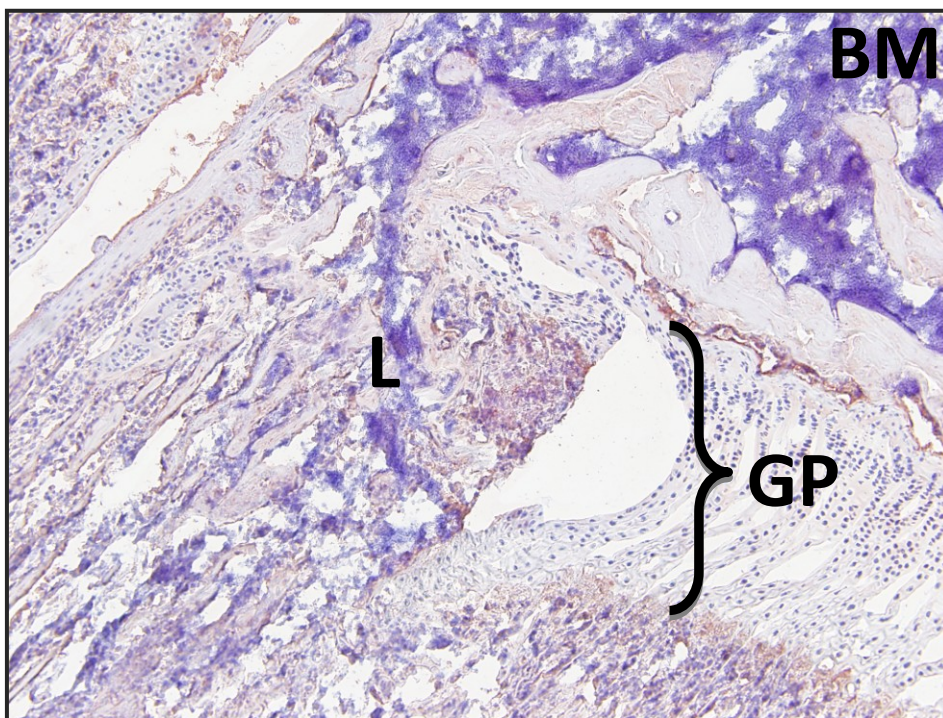


Figure 16: Microscopic picture of the growth plate with a lesion. BM = Bone Marrow, L = Lesion, GP = Growth Plate. Anti VEGF Immunohistochemical Staining, Magnification 10x.

3.2 Day 1

On day 1, a gap crossing the growth plate could be observed in all slides. This gap was filled with a fracture hematoma, bone bruise and a large number of mesenchymal cells. The fracture hematoma as well as the bone bruise stained highly positive for VEGF. (Figure 17, Figure 18, Figure 19)

Regarding the growth plate itself, the resting zone showed no staining whereas all the other layers showed positivity for VEGF. Two to four columns that adjoin the lesion showed no staining (see Figure 19).

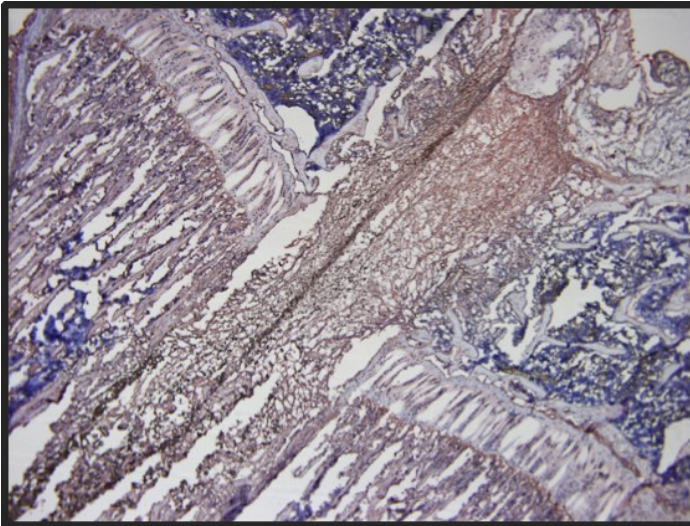


Figure 17: Microscopic Picture of the Growth Plate with a Lesion on Day 1. Anti VEGF Immunohistochemical Staining, Magnification 4x.

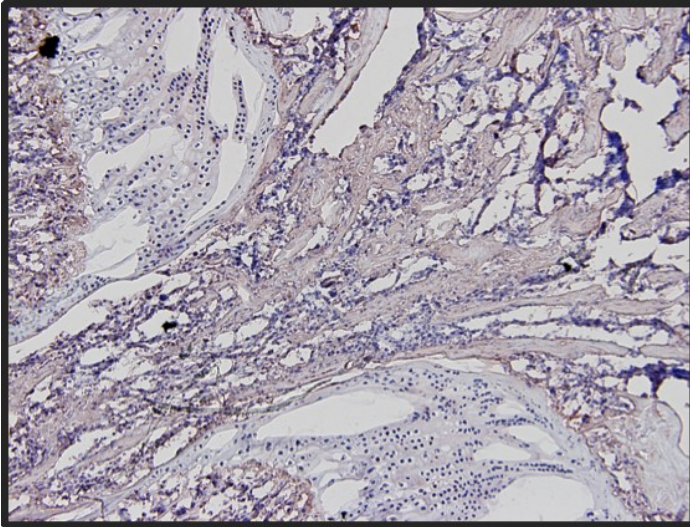


Figure 18: Microscopic Picture of the Growth Plate with a Lesion on Day 1. Anti VEGF Immunohistochemical Staining, Magnification 10x.

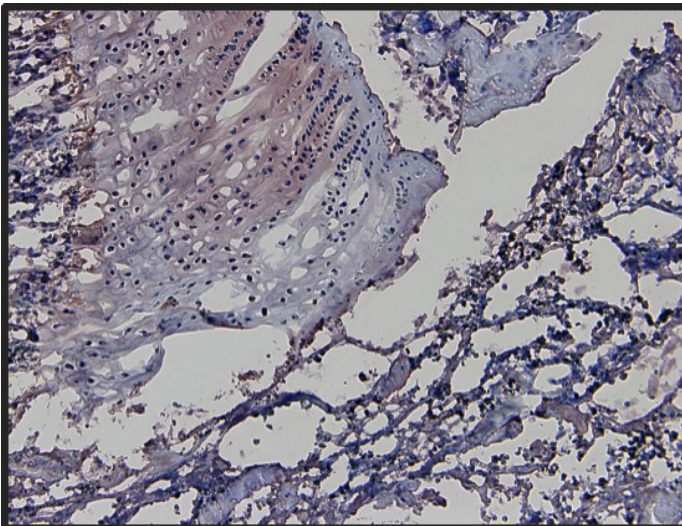


Figure 19: Microscopic Picture of the Growth Plate with a Lesion on Day 1. The Focus was set on the 4 adjoining columns of chondroblasts. Anti VEGF Immunohistochemical Staining, Magnification 20x.

3.3 Day 3

Not much difference between day 1 and day 3 could be observed. The fracture haematoma and the bone fragments that were positive for VEGF were still prominent (Figure 20, Figure 21) No reorganization of the fragments into a bone bridge had yet begun. The growth plate showed the same staining; also the adjoining columns were still negative for VEGF.

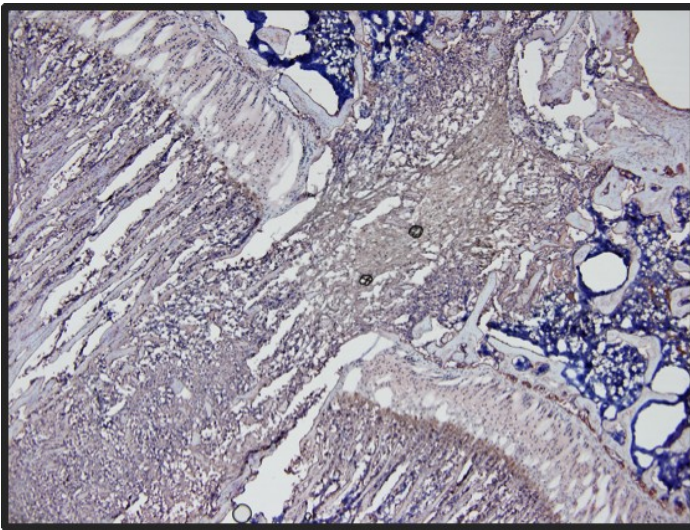


Figure 20: Microscopic Picture of the Growth Plate with a Lesion on Day 3. Anti VEGF Immunohistochemical Staining, Magnification 4x.

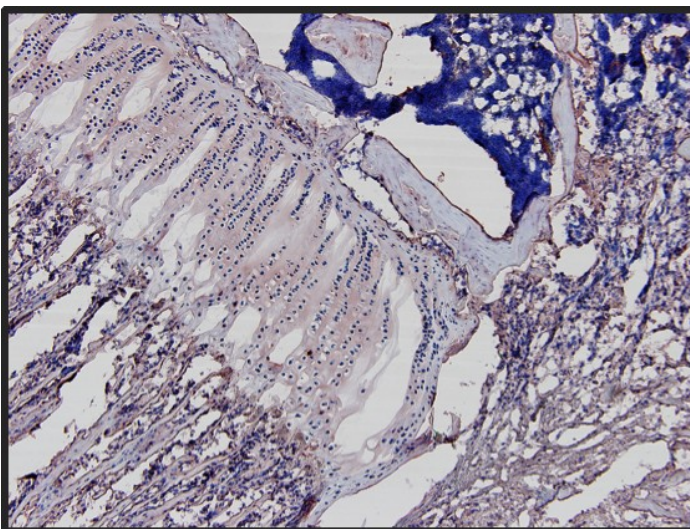


Figure 21: Microscopic Picture of the Growth Plate with a Lesion on Day 3. Anti VEGF Immunohistochemical Staining, Magnification 20x.

3.4 Day 7

On day 7, reorganization of the bone fragments was observed. The existence of a continuous bridge distending from the epiphysis to the metaphysis could not be proven, but still a large number of cells infiltrating the region was seen. The osseous structure stained clearly positive for VEGF (Figure 22, Figure 23)

The resting zone showed no staining whereas all the other layers of the physis showed positivity for VEGF.

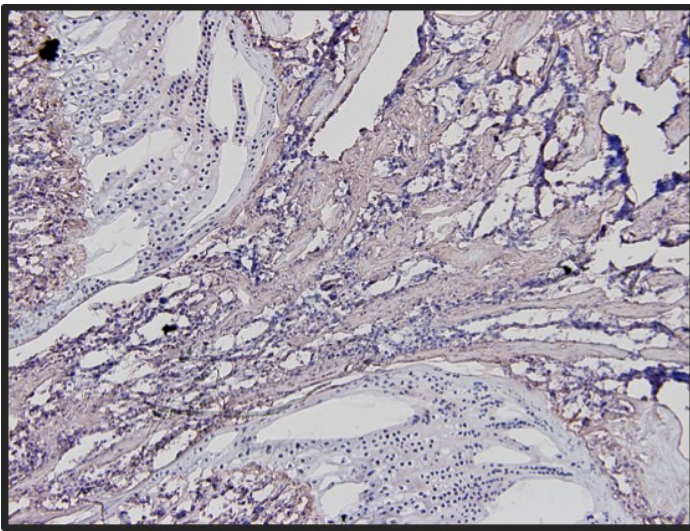


Figure 22: Microscopic Picture of the Growth Plate with a Lesion on Day 7. Anti VEGF Immunohistochemical Staining, Magnification 4x.

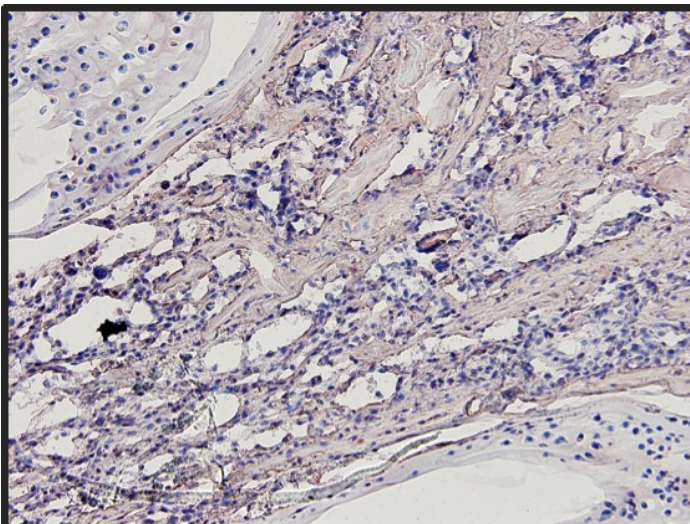


Figure 23: Microscopic Picture of the Growth Plate with a Lesion on Day 7 Anti VEGF Immunohistochemical Staining, Magnification 20x.

3.5 Day 14

The reorganization process continued on day 14, where a small continuous osseous structure was visible. It reached from the epiphysis to the metaphysis and its borders showed clear positivity for VEGF (Figure 24, Figure 25).

Concerning the growth plate, everything remained the same with no staining in the resting zone and positivity in the proliferating and hypertrophic as well as the mineralizing zone.

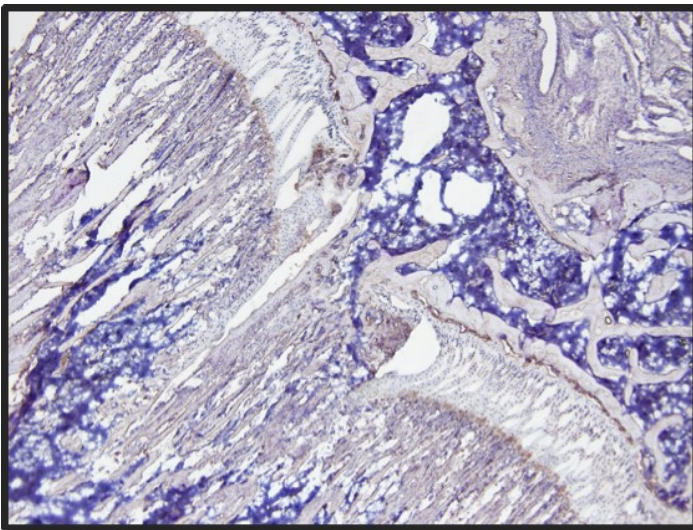


Figure 24: Microscopic Picture of the Growth Plate with a Lesion on Day 14. Anti VEGF Immunohistochemical Staining, Magnification 4x.

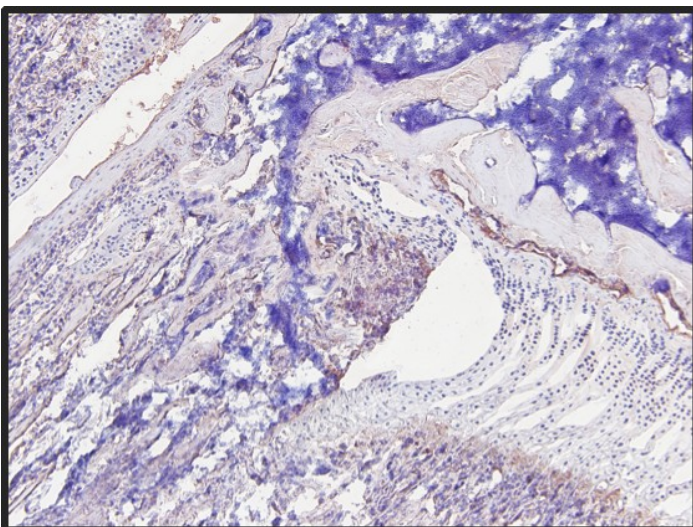


Figure 25: Microscopic Picture of the Growth Plate with a Lesion on Day 14. Anti VEGF Immunohistochemical Staining, Magnification 10x.

3.6 Day 28

On day 28, a bone bridge reaching from the epiphysis to the metaphysis can be observed. VEGF staining is still positive, but it is limited to the cells that surround the osseous structure (Figure 26, Figure 27).

VEGF staining of the growth plate remains the same, with positivity for VEGF in the hypertrophic in mineralizing region.

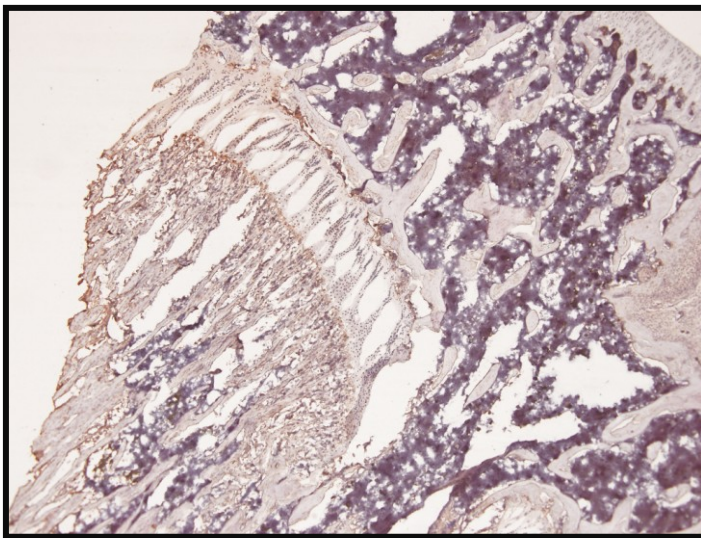


Figure 26: Microscopic Picture of the Growth Plate with a Lesion on Day 28. Anti VEGF Immunohistochemical Staining, Magnification 10x.

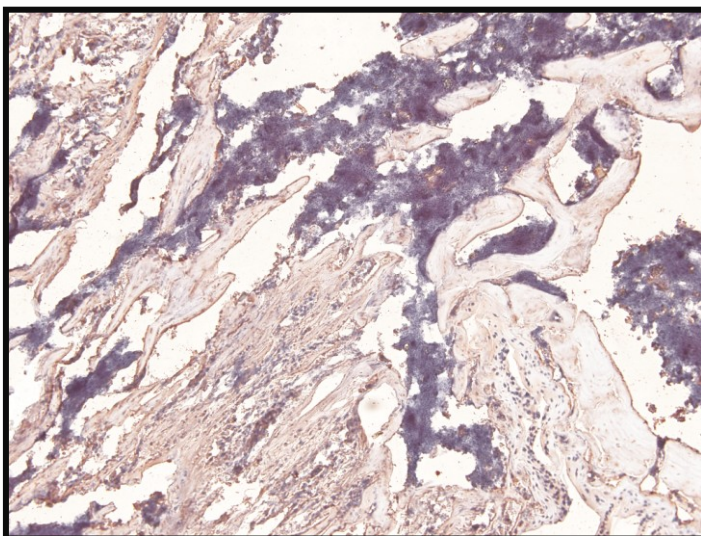


Figure 27: Microscopic Picture of the Growth Plate with a Lesion on Day 28. Anti VEGF Immunohistochemical Staining, Magnification 20x.

3.7 Day 82

On day 82, a fully developed osseous bridge between the epiphysis and the metaphysis/diaphysis (=bone bridge) could be observed. The VEGF staining of the osseous structures was limited to the surrounding cells (see Figure 28, Figure 29)

The height of the growth plate seemed to be diminished in comparison to earlier slides, but no exact measurements could be performed. The chondroblasts of the growth plate stained differently: No staining could be observed in the resting and the proliferative zone while the hypertrophic layer and the mineralizing zone were highly positive for VEGF.

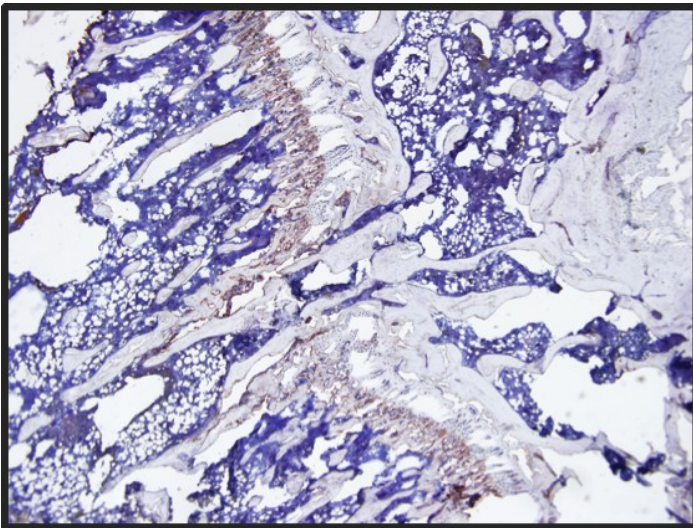


Figure 28: Microscopic Picture of the Growth Plate with a Lesion on Day 82. Anti VEGF Immunohistochemical Staining, Magnification 4x.

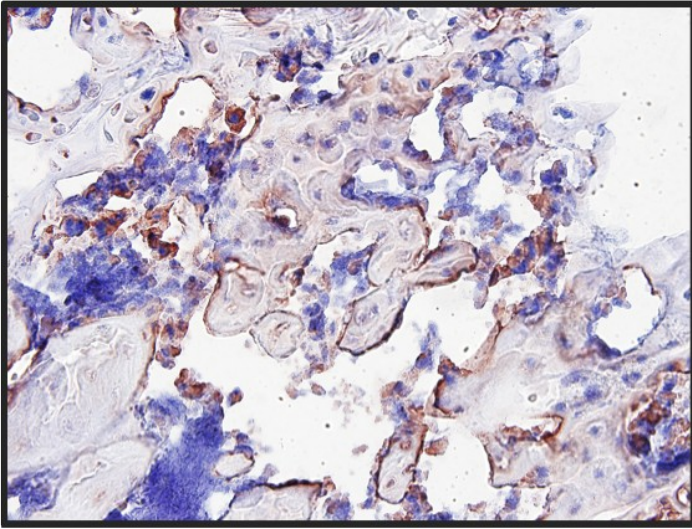


Figure 29: Microscopic Picture of the bone bridge on Day 82 Anti VEGF Immunohistochemical Staining, Magnification 40x.

3.8 Negative Controls

Negative Controls were done for each cycle of staining using 100 mL of PBS instead of the primary antibody against VEGF.

Negative controls showed no significant staining in any of the slides (Figure 30, Figure 31, Figure 32).

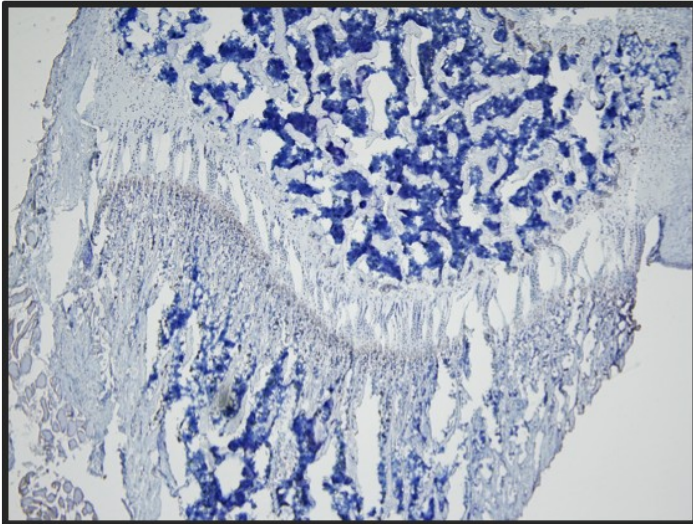


Figure 30: Microscopic Picture of the Growth Plate with no Lesion on Day 28. Negative Control Staining Staining, Magnification 4x.

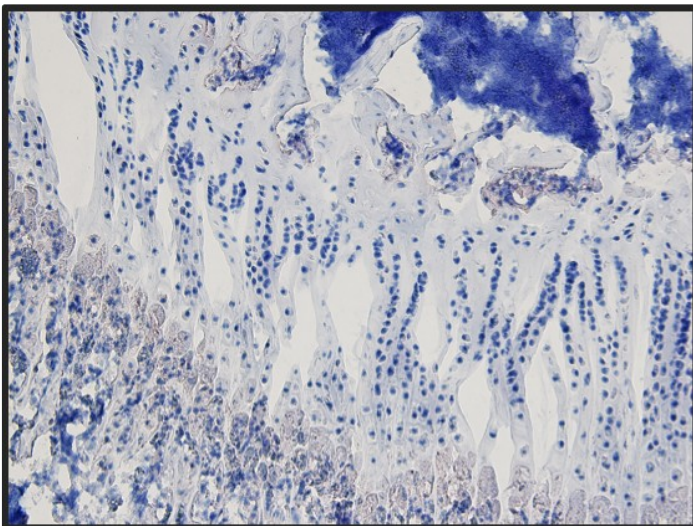


Figure 31: Microscopic Picture of the Growth Plate with no Lesion on Day 28. Negative Control Staining Staining, Magnification 20x.

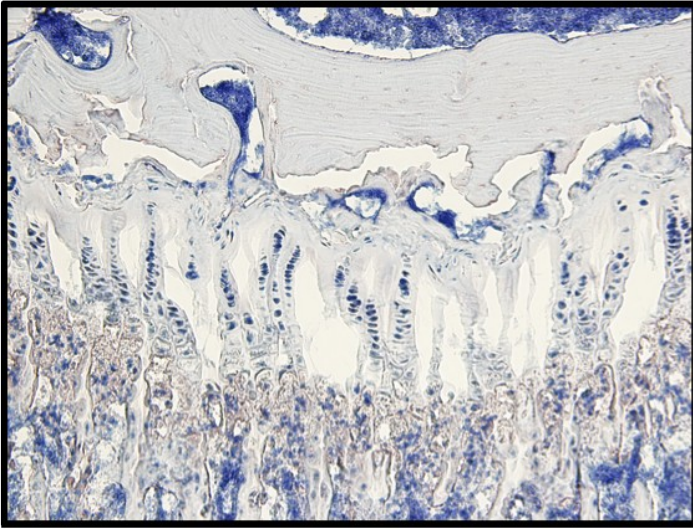


Figure 32: Microscopic Picture of the Growth Plate with no Lesion on Day 82. Negative Control Staining Staining, Magnification 20x

4 Discussion

Damage of the growth plate can lead to various phenomena including axis deviation and/or joint deformity. Slowdown or arrest of longitudinal growth, which leads to length discrepancy between two extremities, may also occur. All these problems decrease the quality of life of our young, still-growing patients. Many experiments have been done to investigate this phenomenon, but no one has set a focus on the expression of VEGF yet, which is one of the most important factors of fracture healing.

The setting of the experiments was based on the knowledge that had been made before by several others authors, who have worked on that topic.

The diameter of the drill was chosen according to Garces and colleagues (52) aiming to prevent early fusion of the growth plate. During our experiments, premature fusion occurred in none of the examined rats. Rats have a maximum lifespan of 3.6 months, fusion of the growth plate occurs in only 10% of the rats at the age of 3.9 months and in 90% at the age of 7.4 months. (138)

However, our main goal was to investigate the vascularisation patterns in the lesion and not the early fusion of the growth plate due to the fact that the rat may not be the ideal model for this purpose. For the same reason, detailed measurement and axis deviation analysis were not performed.

Further investigation could include different location of the drill hole, different diameters of the drill and different techniques to place the lesion (e.g. different materials, tools etc.). Janarv and co-workers(59) suggested that the area of the lesion has an influence on the fusion of the growth plate and length disturbances in rabbits. A similar trial for rats could be established.

Day 1 to 3 revealed a fracture hematoma including many small bone fragments. No literature could be found showing comparable results due to the fact that numerous studies did not examine the first week after transphyseal drilling. These solitary bone fragments are distributed randomly along the drilling site. The location and time of appearance suggest that they result from the destruction of the bone tissue of the epiphysis as well as the trabecular bone of the metaphysis by the drill. On day 7, reorganization of these fragments was observed prior to the development of small bony trabeculae crossing the physis by day 14. By day 28, a bone-bridge

consisting of prominent bone trabeculae at the physal injury site connecting the epiphysis with the metaphysis was visible which was still prominent on day 82. These findings concur with the results of Garces and co-workers(52).

Beside the setting and the development of the lesion, the focus was set on the Vascular Endothelial Growth Factor. It is implicated in enchondral bone formation where blocking results in growth arrest and alteration of the architecture of the growth plate.(40) Furthermore, it is an important factor in the early phase of normal fracture healing.(139, 140) Generally spoken, vascularisation and angiogenesis are crucial for bone healing and VEGF is seen as a key factor.(141)

In our study, on days 1 and 3, the fracture hematoma and the bone fragments expressed a high amount of VEGF. One explanation could be the hypoxic environment of the injury, which is caused by the interrupted blood supply. Low partial pressure of O₂ activates HIF-1, which induces the expression of genes of the VEGF-Family.(103, 142) This leads to high expression of VEGF, which could be proven immunohistochemically in our experiment. Pufe and co-workers showed that the expression of VEGF in a fracture gap increases until day 5 where it peaks, but then diminishes continuously and rapidly.(139)

Interestingly, on days 1 and 3, 2 to 4 columns of chondroblasts adjoining the lesion, did not stain for VEGF whereas the other columns showed positivity for VEGF. This may be due to the direct influence of the drilling procedure or the unfavourable conditions in the early phase of the healing.

VEGF expression has decreased by day 7, but the positivity of the bone fragments is still strong. They are completely covered with VEGF suggesting a high activity of those particles.

This high activity during the first 7 days may be due to the multifaceted nature of VEGF.

Firstly, it is directly involved in bone formation because blocking of VEGF results in impaired bone formation in the intramembranous as well as in the enchondral ossification pathway. Additionally, Street and co-workers showed that it improves vascularity and callus formation. (143) Apart from its direct effects on the whole process of bone formation, it also influences several cells that are involved in fracture healing. It enhances osteoclast survival and therefore

bone resorption.(108, 143) It attracts osteoblasts and augments their ability to differentiate and proliferate as well as their activity.(101, 143, 144) In human mesenchymal stem cells it enhances the mineralization and differentiation as well as its own production.(103) Furthermore, there is also a chemotactic effect on human mesenchymal progenitor cells.(145) All these facts may contribute to an explanation why VEGF is strongly expressed in the early phase of fracture healing in the growth plate. From day 14 onwards, the expression of VEGF decreased and was limited to the cells that border the bone trabeculae. Uchida and co-workers set up a similar experiment in rats where they drilled through the diaphysis of a long bone where similar results were found at similar time points from day 1 to day 14.(140)

We could clearly document that VEGF is involved in post-traumatic bone bridge formation of the growth plate.

Vascular Endothelial Growth Factor may be an important and even crucial factor for the healing of growth plate defects. Further investigation should be done on this topic, as it may be a target of therapy to prevent the formation of bone bridge bridges and its side effects in our already injured young patients.

5 References

1. Nieves BJ, D'Amore PA, Bryan BA. The function of vascular endothelial growth factor. *Biofactors*. 2009 Jul-Aug;35(4):332-7.
2. Waldeyer J. *Anatomie des Menschen*. 17th ed. Berlin, New York: Walter de Gruyter; 2003.
3. Weinberg AM, Tscherne H. *Tscherne Unfallchirurgie: Unfallchirurgie im Kindesalter (Allgemeiner Teil, Kopf, Obere Extremität, Wirbelsäule)*. 1st ed. Berlin, Heidelberg, New York: Springer Verlag; 2006.
4. Mau E, Whetstone H, Yu C, Hopyan S, Wunder JS, Alman BA. PTHrP regulates growth plate chondrocyte differentiation and proliferation in a Gli3 dependent manner utilizing hedgehog ligand dependent and independent mechanisms. *Dev Biol*. 2007 May 1;305(1):28-39.
5. DeLise AM, Fischer L, Tuan RS. Cellular interactions and signaling in cartilage development. *Osteoarthritis Cartilage*. 2000 Sep;8(5):309-34.
6. Bucher O, Wartenberg H. *Cytologie, Histologie und mikroskopische Anatomie des Menschen*. 12th ed. Bern: Verlag Hans Huber; 1997.
7. Kühnel W. *Taschenatlas Histologie*. 12th ed. Stuttgart, New York: Thieme; 2008.
8. Lüllmann-Rauch R. *Taschenlehrbuch Histologie*. 3rd ed. Stuttgart: Thieme; 2009.
9. Wezeman FH. Morphological foundations of precartilage development in mesenchyme. *Microsc Res Tech*. 1998 Oct 15;43(2):91-101.
10. Burdan F, Szumilo J, Korobowicz A, Farooquee R, Patel S, Patel A, et al. Morphology and physiology of the epiphyseal growth plate. *Folia Histochem Cytobiol*. 2009;47(1):5-16.

11. Huang W, Zhou X, Lefebvre V, de Crombrughe B. Phosphorylation of SOX9 by cyclic AMP-dependent protein kinase A enhances SOX9's ability to transactivate a Col2a1 chondrocyte-specific enhancer. *Mol Cell Biol*. 2000 Jun;20(11):4149-58.
12. Zhang P, Jimenez SA, Stokes DG. Regulation of human COL9A1 gene expression. Activation of the proximal promoter region by SOX9. *J Biol Chem*. 2003 Jan 3;278(1):117-23.
13. Lefebvre V, Smits P. Transcriptional control of chondrocyte fate and differentiation. *Birth Defects Res C Embryo Today*. 2005 Sep;75(3):200-12.
14. Ballock TR, O'Keefe RJ. Physiology and pathophysiology of the growth plate. *Birth Defects Research Part C: Embryo Today: Reviews*. 2003;69(2):123-43.
15. Melrose J, Smith SM, Smith MM, Little CB. The use of Histochoice for histological examination of articular and growth plate cartilages, intervertebral disc and meniscus. *Biotech Histochem*. 2008 Feb;83(1):47-53.
16. Mwale F, Billingham C, Wu W, Alini M, Webber C, Reiner A, et al. Selective assembly and remodelling of collagens II and IX associated with expression of the chondrocyte hypertrophic phenotype. *Dev Dyn*. 2000 Aug;218(4):648-62.
17. Vu TH, Shipley JM, Bergers G, Berger JE, Helms JA, Hanahan D, et al. MMP-9/gelatinase B is a key regulator of growth plate angiogenesis and apoptosis of hypertrophic chondrocytes. *Cell*. 1998 May 1;93(3):411-22.
18. Isaksson OG, Lindahl A, Nilsson A, Isgaard J. Mechanism of the stimulatory effect of growth hormone on longitudinal bone growth. *Endocr Rev*. 1987 Nov;8(4):426-38.
19. Mohan S, Richman C, Guo R, Amaar Y, Donahue LR, Wergedal J, et al. Insulin-like growth factor regulates peak bone mineral density in mice by both growth hormone-dependent and -independent mechanisms. *Endocrinology*. 2003 Mar;144(3):929-36.

20. van der Eerden BC, Karperien M, Wit JM. Systemic and local regulation of the growth plate. *Endocr Rev.* 2003 Dec;24(6):782-801.
21. Wakita R, Izumi T, Itoman M. Thyroid hormone-induced chondrocyte terminal differentiation in rat femur organ culture. *Cell Tissue Res.* 1998 Aug;293(2):357-64.
22. Burch WM, Van Wyk JJ. Triiodothyronine stimulates cartilage growth and maturation by different mechanisms. *Am J Physiol.* 1987 Feb;252(2 Pt 1):E176-82.
23. Okubo Y, Reddi AH. Thyroxine downregulates Sox9 and promotes chondrocyte hypertrophy. *Biochem Biophys Res Commun.* 2003 Jun 20;306(1):186-90.
24. Lewinson D, Harel Z, Shenzer P, Silbermann M, Hochberg Z. Effect of thyroid hormone and growth hormone on recovery from hypothyroidism of epiphyseal growth plate cartilage and its adjacent bone. *Endocrinology.* 1989 Feb;124(2):937-45.
25. Longui CA. Glucocorticoid therapy: minimizing side effects. *J Pediatr (Rio J).* 2007 Nov;83(5 Suppl):S163-77.
26. Elias LL, Huebner A, Metherell LA, Canas A, Warne GL, Bitti ML, et al. Tall stature in familial glucocorticoid deficiency. *Clin Endocrinol (Oxf).* 2000 Oct;53(4):423-30.
27. Silvestrini G, Ballanti P, Patacchioli FR, Mocetti P, Di Grezia R, Wedard BM, et al. Evaluation of apoptosis and the glucocorticoid receptor in the cartilage growth plate and metaphyseal bone cells of rats after high-dose treatment with corticosterone. *Bone.* 2000 Jan;26(1):33-42.
28. Annefeld M. Changes in rat epiphyseal cartilage after treatment with dexamethasone and glycosaminoglycan-peptide complex. *Pathol Res Pract.* 1992 Jun;188(4-5):649-52.
29. Zung A, Phillip M, Chalew SA, Palese T, Kowarski AA, Zadik Z. Testosterone effect on growth and growth mediators of the GH-IGF-I axis in the liver and epiphyseal growth plate of juvenile rats. *J Mol Endocrinol.* 1999 Oct;23(2):209-21.

30. St-Jacques B, Hammerschmidt M, McMahon AP. Indian hedgehog signaling regulates proliferation and differentiation of chondrocytes and is essential for bone formation. *Genes Dev.* 1999 Aug 15;13(16):2072-86.
31. Karp SJ, Schipani E, St-Jacques B, Hunzelman J, Kronenberg H, McMahon AP. Indian hedgehog coordinates endochondral bone growth and morphogenesis via parathyroid hormone related-protein-dependent and -independent pathways. *Development.* 2000 Feb;127(3):543-8.
32. Vortkamp A, Lee K, Lanske B, Segre GV, Kronenberg HM, Tabin CJ. Regulation of rate of cartilage differentiation by Indian hedgehog and PTH-related protein. *Science.* 1996 Aug 2;273(5275):613-22.
33. Lanske B, Karaplis AC, Lee K, Luz A, Vortkamp A, Pirro A, et al. PTH/PTHrP receptor in early development and Indian hedgehog-regulated bone growth. *Science.* 1996 Aug 2;273(5275):663-6.
34. Turner N, Grose R. Fibroblast growth factor signalling: from development to cancer. *Nat Rev Cancer.* 2010 Feb;10(2):116-29.
35. Kronenberg HM. Developmental regulation of the growth plate. *Nature.* 2003 May 15;423(6937):332-6.
36. Minina E, Wenzel HM, Kreschel C, Karp S, Gaffield W, McMahon AP, et al. BMP and Ihh/PTHrP signaling interact to coordinate chondrocyte proliferation and differentiation. *Development.* 2001 Nov;128(22):4523-34.
37. Minina E, Kreschel C, Naski MC, Ornitz DM, Vortkamp A. Interaction of FGF, Ihh/Pthlh, and BMP signaling integrates chondrocyte proliferation and hypertrophic differentiation. *Dev Cell.* 2002 Sep;3(3):439-49.

38. Bluteau G, Julien M, Magne D, Mallein-Gerin F, Weiss P, Daculsi G, et al. VEGF and VEGF receptors are differentially expressed in chondrocytes. *Bone*. 2007;40(3):568-76.
39. Wedge SR, Ogilvie DJ, Dukes M, Kendrew J, Curwen JO, Hennequin LF, et al. ZD4190: an orally active inhibitor of vascular endothelial growth factor signaling with broad-spectrum antitumor efficacy. *Cancer Res*. 2000 Feb 15;60(4):970-5.
40. Gerber H-P, Vu TH, Ryan AM, Kowalski J, Werb Z, Ferrara N. VEGF couples hypertrophic cartilage remodeling, ossification and angiogenesis during endochondral bone formation. *Nat Med*. 1999;5(6):623-8.
41. Deckers MML, van Bezooijen RL, van der Horst G, Hoogendam J, van der Bent C, Papapoulos SE, et al. Bone Morphogenetic Proteins Stimulate Angiogenesis through Osteoblast-Derived Vascular Endothelial Growth Factor A. *Endocrinology*. 2002 April 1, 2002;143(4):1545-53.
42. Nilsson O, Baron J. Impact of growth plate senescence on catch-up growth and epiphyseal fusion. *Pediatr Nephrol*. 2005 Mar;20(3):319-22.
43. Emons J, Chagin AS, Hultenby K, Zhivotovsky B, Wit JM, Karperien M, et al. Epiphyseal fusion in the human growth plate does not involve classical apoptosis. *Pediatr Res*. 2009 Dec;66(6):654-9.
44. Grumbach MM, Auchus RJ. Estrogen: consequences and implications of human mutations in synthesis and action. *J Clin Endocrinol Metab*. 1999 Dec;84(12):4677-94.
45. Morishima A, Grumbach MM, Simpson ER, Fisher C, Qin K. Aromatase deficiency in male and female siblings caused by a novel mutation and the physiological role of estrogens. *J Clin Endocrinol Metab*. 1995 Dec;80(12):3689-98.
46. Stevens DG, Boyer MI, Bowen CV. Transplantation of epiphyseal plate allografts between animals of different ages. *J Pediatr Orthop*. 1999 May-Jun;19(3):398-403.

47. Wilkins KE. Principles of fracture remodeling in children. *Injury*. 2005;36(Supplement 1):S3-S11.
48. Aitken AP. Fractures of the epiphyses. *Clin Orthop Relat Res*. 1965 Jul-Aug;41:19-23.
49. Jungbluth KH, Dallek M, Meenen NM. [Injuries to the growth plates]. *Unfallchirurg*. 1997 Jul;100(7):571-86.
50. Caine D, DiFiori J, Maffulli N. Physeal injuries in children's and youth sports: reasons for concern? *Br J Sports Med*. 2006 Sep;40(9):749-60.
51. Larsen MW, Garrett WE, Jr., Delee JC, Moorman CT, 3rd. Surgical management of anterior cruciate ligament injuries in patients with open physes. *J Am Acad Orthop Surg*. 2006 Dec;14(13):736-44.
52. Garces GL, Mugica-Garay I, Lopez-Gonzalez Coviella N, Guerado E. Growth-plate modifications after drilling. *J Pediatr Orthop*. 1994 Mar-Apr;14(2):225-8.
53. Seil R, Pape D, Kohn D. The Risk of Growth Changes During Transphyseal Drilling in Sheep With Open Physes. *Arthroscopy: The Journal of Arthroscopic & Related Surgery*. 2008;24(7):824-33.
54. Futami T, Foster BK, Morris LL, LeQuesne GW. Magnetic resonance imaging of growth plate injuries: the efficacy and indications for surgical procedures. *Archives of Orthopaedic and Trauma Surgery*. 2000;120(7):390-6.
55. Makela E, Vainionpaa S, Vihtonen K, Mero M, Rokkanen P. The effect of trauma to the lower femoral epiphyseal plate. An experimental study in rabbits. *J Bone Joint Surg Br*. 1988 March 1, 1988;70-B(2):187-91.
56. Langenskiold A. AN OPERATION FOR PARTIAL CLOSURE OF AN EPIPHYSIAL PLATE IN CHILDREN, AND ITS EXPERIMENTAL BASIS. *J Bone Joint Surg Br*. 1975 August 1, 1975;57-B(3):325-30.

57. Stadelmaier DM, Arnoczky SP, Dodds J, Ross H. The effect of drilling and soft tissue grafting across open growth plates. A histologic study. *Am J Sports Med.* 1995 Jul-Aug;23(4):431-5.
58. Guzzanti V, Falciglia F, Gigante A, Fabbriani C. The effect of intra-articular ACL reconstruction on the growth plates of rabbits. *J Bone Joint Surg Br.* 1994 November 1, 1994;76-B(6):960-3.
59. Janarv PM, Wikstrom B, Hirsch G. The influence of transphyseal drilling and tendon grafting on bone growth: an experimental study in the rabbit. *J Pediatr Orthop.* 1998 Mar-Apr;18(2):149-54.
60. Ferrara N. Vascular endothelial growth factor: basic science and clinical progress. *Endocr Rev.* 2004 Aug;25(4):581-611.
61. Ferrara N, Henzel WJ. Pituitary follicular cells secrete a novel heparin-binding growth factor specific for vascular endothelial cells. *Biochem Biophys Res Commun.* 1989 Jun 15;161(2):851-8.
62. Vincenti V, Cassano C, Rocchi M, Persico G. Assignment of the vascular endothelial growth factor gene to human chromosome 6p21.3. *Circulation.* 1996 Apr 15;93(8):1493-5.
63. Tischer E, Mitchell R, Hartman T, Silva M, Gospodarowicz D, Fiddes JC, et al. The human gene for vascular endothelial growth factor. Multiple protein forms are encoded through alternative exon splicing. *J Biol Chem.* 1991 Jun 25;266(18):11947-54.
64. Horn F. *Biochemie des Menschen: Das Lehrbuch für das Medizinstudium.* 3rd ed. Stuttgart: Thieme; 2005.
65. Ferrara N, Gerber HP, LeCouter J. The biology of VEGF and its receptors. *Nat Med.* 2003 Jun;9(6):669-76.

66. Lei J, Jiang A, Pei D. Identification and characterization of a new splicing variant of vascular endothelial growth factor: VEGF183. *Biochim Biophys Acta*. 1998 Dec 22;1443(3):400-6.
67. Houck KA, Leung DW, Rowland AM, Winer J, Ferrara N. Dual regulation of vascular endothelial growth factor bioavailability by genetic and proteolytic mechanisms. *J Biol Chem*. 1992 Dec 25;267(36):26031-7.
68. Potgens AJ, Lubsen NH, van Altena MC, Vermeulen R, Bakker A, Schoenmakers JG, et al. Covalent dimerization of vascular permeability factor/vascular endothelial growth factor is essential for its biological activity. Evidence from Cys to Ser mutations. *J Biol Chem*. 1994 Dec 30;269(52):32879-85.
69. Siemeister G, Marme D, Martiny-Baron G. The alpha-helical domain near the amino terminus is essential for dimerization of vascular endothelial growth factor. *J Biol Chem*. 1998 May 1;273(18):11115-20.
70. Gerber HP, McMurtrey A, Kowalski J, Yan M, Keyt BA, Dixit V, et al. Vascular endothelial growth factor regulates endothelial cell survival through the phosphatidylinositol 3'-kinase/Akt signal transduction pathway. Requirement for Flk-1/KDR activation. *J Biol Chem*. 1998 Nov 13;273(46):30336-43.
71. Robinson CJ, Stringer SE. The splice variants of vascular endothelial growth factor (VEGF) and their receptors. *J Cell Sci*. 2001 Mar;114(Pt 5):853-65.
72. Liu Y, Cox SR, Morita T, Kourembanas S. Hypoxia regulates vascular endothelial growth factor gene expression in endothelial cells. Identification of a 5' enhancer. *Circ Res*. 1995 Sep;77(3):638-43.
73. Madan A, Curtin PT. A 24-base-pair sequence 3' to the human erythropoietin gene contains a hypoxia-responsive transcriptional enhancer. *Proc Natl Acad Sci U S A*. 1993 May 1;90(9):3928-32.

74. Dai J, Rabie AB. VEGF: an essential mediator of both angiogenesis and endochondral ossification. *J Dent Res.* 2007 Oct;86(10):937-50.
75. Deckers MML, Karperien M, van der Bent C, Yamashita T, Papapoulos SE, Lowik CWGM. Expression of Vascular Endothelial Growth Factors and Their Receptors during Osteoblast Differentiation. *Endocrinology.* 2000 May 1, 2000;141(5):1667-74.
76. Kakudo N, Kusumoto K, Wang YB, Iguchi Y, Ogawa Y. Immunolocalization of vascular endothelial growth factor on intramuscular ectopic osteoinduction by bone morphogenetic protein-2. *Life Sci.* 2006 Oct 4;79(19):1847-55.
77. Yeh LC, Lee JC. Osteogenic protein-1 increases gene expression of vascular endothelial growth factor in primary cultures of fetal rat calvaria cells. *Mol Cell Endocrinol.* 1999 Jul 20;153(1-2):113-24.
78. Perbal B. CCN proteins: multifunctional signalling regulators. *Lancet.* 2004 Jan 3;363(9402):62-4.
79. Ivkovic S, Yoon BS, Popoff SN, Safadi FF, Libuda DE, Stephenson RC, et al. Connective tissue growth factor coordinates chondrogenesis and angiogenesis during skeletal development. *Development.* 2003 Jun;130(12):2779-91.
80. Chang SC, Chuang HL, Chen YR, Chen JK, Chung HY, Lu YL, et al. Ex vivo gene therapy in autologous bone marrow stromal stem cells for tissue-engineered maxillofacial bone regeneration. *Gene Ther.* 2003 Nov;10(24):2013-9.
81. Wise GE, Yao S. Expression of vascular endothelial growth factor in the dental follicle. *Crit Rev Eukaryot Gene Expr.* 2003;13(2-4):173-80.
82. Kendall RL, Thomas KA. Inhibition of vascular endothelial cell growth factor activity by an endogenously encoded soluble receptor. *Proc Natl Acad Sci U S A.* 1993 Nov 15;90(22):10705-9.

83. Gerber HP, Condorelli F, Park J, Ferrara N. Differential transcriptional regulation of the two vascular endothelial growth factor receptor genes. Flt-1, but not Flk-1/KDR, is up-regulated by hypoxia. *J Biol Chem*. 1997 Sep 19;272(38):23659-67.
84. Fong GH, Zhang L, Bryce DM, Peng J. Increased hemangioblast commitment, not vascular disorganization, is the primary defect in flt-1 knock-out mice. *Development*. 1999 Jul;126(13):3015-25.
85. Bruns AF, Bao L, Walker JH, Ponnambalam S. VEGF-A-stimulated signalling in endothelial cells via a dual receptor tyrosine kinase system is dependent on co-ordinated trafficking and proteolysis. *Biochem Soc Trans*. 2009 Dec;37(Pt 6):1193-7.
86. LeCouter J, Moritz DR, Li B, Phillips GL, Liang XH, Gerber HP, et al. Angiogenesis-independent endothelial protection of liver: role of VEGFR-1. *Science*. 2003 Feb 7;299(5608):890-3.
87. Neufeld G, Cohen T, Gengrinovitch S, Poltorak Z. Vascular endothelial growth factor (VEGF) and its receptors. *FASEB J*. 1999 Jan;13(1):9-22.
88. Pajusola K, Aprelikova O, Korhonen J, Kaipainen A, Pertovaara L, Alitalo R, et al. FLT4 receptor tyrosine kinase contains seven immunoglobulin-like loops and is expressed in multiple human tissues and cell lines. *Cancer Res*. 1992 Oct 15;52(20):5738-43.
89. Soker S, Takashima S, Miao HQ, Neufeld G, Klagsbrun M. Neuropilin-1 is expressed by endothelial and tumor cells as an isoform-specific receptor for vascular endothelial growth factor. *Cell*. 1998 Mar 20;92(6):735-45.
90. Selleck SB. Signaling from across the way: transactivation of VEGF receptors by HSPGs. *Mol Cell*. 2006 May 19;22(4):431-2.
91. Pschyrembel W. *Pschyrembel Klinisches Wörterbuch* 261 ed. Berlin, New York: de Gruyter; 2007.

92. Tessler S, Rockwell P, Hicklin D, Cohen T, Levi BZ, Witte L, et al. Heparin modulates the interaction of VEGF165 with soluble and cell associated flk-1 receptors. *J Biol Chem.* 1994 Apr 29;269(17):12456-61.
93. Nagy JA, Vasile E, Feng D, Sundberg C, Brown LF, Detmar MJ, et al. Vascular permeability factor/vascular endothelial growth factor induces lymphangiogenesis as well as angiogenesis. *J Exp Med.* 2002 Dec 2;196(11):1497-506.
94. Gerber HP, Dixit V, Ferrara N. Vascular endothelial growth factor induces expression of the antiapoptotic proteins Bcl-2 and A1 in vascular endothelial cells. *J Biol Chem.* 1998 May 22;273(21):13313-6.
95. Yuan F, Chen Y, Dellian M, Safabakhsh N, Ferrara N, Jain RK. Time-dependent vascular regression and permeability changes in established human tumor xenografts induced by an anti-vascular endothelial growth factor/vascular permeability factor antibody. *Proc Natl Acad Sci U S A.* 1996 Dec 10;93(25):14765-70.
96. Dvorak HF, Brown LF, Detmar M, Dvorak AM. Vascular permeability factor/vascular endothelial growth factor, microvascular hyperpermeability, and angiogenesis. *Am J Pathol.* 1995 May;146(5):1029-39.
97. Ku DD, Zaleski JK, Liu S, Brock TA. Vascular endothelial growth factor induces EDRF-dependent relaxation in coronary arteries. *Am J Physiol.* 1993 Aug;265(2 Pt 2):H586-92.
98. Pepper MS, Ferrara N, Orci L, Montesano R. Vascular endothelial growth factor (VEGF) induces plasminogen activators and plasminogen activator inhibitor-1 in microvascular endothelial cells. *Biochem Biophys Res Commun.* 1991 Dec 16;181(2):902-6.
99. Unemori EN, Ferrara N, Bauer EA, Amento EP. Vascular endothelial growth factor induces interstitial collagenase expression in human endothelial cells. *J Cell Physiol.* 1992 Dec;153(3):557-62.

100. Goad DL, Rubin J, Wang H, Tashjian AH, Jr., Patterson C. Enhanced expression of vascular endothelial growth factor in human SaOS-2 osteoblast-like cells and murine osteoblasts induced by insulin-like growth factor I. *Endocrinology*. 1996 Jun;137(6):2262-8.
101. Mayr-Wohlfart U, Waltenberger J, Hausser H, Kessler S, Günther KP, Dehio C, et al. Vascular endothelial growth factor stimulates chemotactic migration of primary human osteoblasts. *Bone*. 2002;30(3):472-7.
102. Zelzer E, McLean W, Ng YS, Fukai N, Reginato AM, Lovejoy S, et al. Skeletal defects in VEGF(120/120) mice reveal multiple roles for VEGF in skeletogenesis. *Development*. 2002 Apr;129(8):1893-904.
103. Mayer H, Bertram H, Lindenmaier W, Korff T, Weber H, Weich H. Vascular endothelial growth factor (VEGF-A) expression in human mesenchymal stem cells: autocrine and paracrine role on osteoblastic and endothelial differentiation. *J Cell Biochem*. 2005 Jul 1;95(4):827-39.
104. Peng H, Wright V, Usas A, Gearhart B, Shen HC, Cummins J, et al. Synergistic enhancement of bone formation and healing by stem cell-expressed VEGF and bone morphogenetic protein-4. *J Clin Invest*. 2002 Sep;110(6):751-9.
105. Niida S, Kondo T, Hiratsuka S, Hayashi S, Amizuka N, Noda T, et al. VEGF receptor 1 signaling is essential for osteoclast development and bone marrow formation in colony-stimulating factor 1-deficient mice. *Proc Natl Acad Sci U S A*. 2005 Sep 27;102(39):14016-21.
106. Engsig MT, Chen QJ, Vu TH, Pedersen AC, Therkidsen B, Lund LR, et al. Matrix metalloproteinase 9 and vascular endothelial growth factor are essential for osteoclast recruitment into developing long bones. *J Cell Biol*. 2000 Nov 13;151(4):879-89.
107. Niida S, Kaku M, Amano H, Yoshida H, Kataoka H, Nishikawa S, et al. Vascular endothelial growth factor can substitute for macrophage colony-stimulating factor in the support of osteoclastic bone resorption. *J Exp Med*. 1999 Jul 19;190(2):293-8.

108. Nakagawa M, Kaneda T, Arakawa T, Morita S, Sato T, Yomada T, et al. Vascular endothelial growth factor (VEGF) directly enhances osteoclastic bone resorption and survival of mature osteoclasts. *FEBS Lett.* 2000 May 12;473(2):161-4.
109. Clauss M, Gerlach M, Gerlach H, Brett J, Wang F, Familletti PC, et al. Vascular permeability factor: a tumor-derived polypeptide that induces endothelial cell and monocyte procoagulant activity, and promotes monocyte migration. *J Exp Med.* 1990 Dec 1;172(6):1535-45.
110. Gerber HP, Malik AK, Solar GP, Sherman D, Liang XH, Meng G, et al. VEGF regulates haematopoietic stem cell survival by an internal autocrine loop mechanism. *Nature.* 2002 Jun 27;417(6892):954-8.
111. Compornolle V, Brusselmans K, Acker T, Hoet P, Tjwa M, Beck H, et al. Loss of HIF-2alpha and inhibition of VEGF impair fetal lung maturation, whereas treatment with VEGF prevents fatal respiratory distress in premature mice. *Nat Med.* 2002 Jul;8(7):702-10.
112. Gabrilovich DI, Chen HL, Girgis KR, Cunningham HT, Meny GM, Nadaf S, et al. Production of vascular endothelial growth factor by human tumors inhibits the functional maturation of dendritic cells. *Nat Med.* 1996 Oct;2(10):1096-103.
113. Hattori K, Dias S, Heissig B, Hackett NR, Lyden D, Tateno M, et al. Vascular endothelial growth factor and angiopoietin-1 stimulate postnatal hematopoiesis by recruitment of vasculogenic and hematopoietic stem cells. *J Exp Med.* 2001 May 7;193(9):1005-14.
114. Sondell M, Lundborg G, Kanje M. Vascular endothelial growth factor stimulates Schwann cell invasion and neovascularization of acellular nerve grafts. *Brain Res.* 1999 Nov 6;846(2):219-28.
115. Sondell M, Lundborg G, Kanje M. Vascular endothelial growth factor has neurotrophic activity and stimulates axonal outgrowth, enhancing cell survival and Schwann cell proliferation in the peripheral nervous system. *J Neurosci.* 1999 Jul 15;19(14):5731-40.

116. Ferrara N. Role of vascular endothelial growth factor in regulation of physiological angiogenesis. *Am J Physiol Cell Physiol*. 2001 Jun;280(6):C1358-66.
117. Carmeliet P, Ferreira V, Breier G, Pollefeyt S, Kieckens L, Gertsenstein M, et al. Abnormal blood vessel development and lethality in embryos lacking a single VEGF allele. *Nature*. 1996 Apr 4;380(6573):435-9.
118. Ferrara N, Carver-Moore K, Chen H, Dowd M, Lu L, O'Shea KS, et al. Heterozygous embryonic lethality induced by targeted inactivation of the VEGF gene. *Nature*. 1996 Apr 4;380(6573):439-42.
119. Fong GH, Rossant J, Gertsenstein M, Breitman ML. Role of the Flt-1 receptor tyrosine kinase in regulating the assembly of vascular endothelium. *Nature*. 1995 Jul 6;376(6535):66-70.
120. Gerber HP, Hillan KJ, Ryan AM, Kowalski J, Keller GA, Rangell L, et al. VEGF is required for growth and survival in neonatal mice. *Development*. 1999 Mar;126(6):1149-59.
121. Ryan AM, Eppler DB, Hagler KE, Bruner RH, Thomford PJ, Hall RL, et al. Preclinical safety evaluation of rhuMAbVEGF, an antiangiogenic humanized monoclonal antibody. *Toxicol Pathol*. 1999 Jan-Feb;27(1):78-86.
122. Phillips HS, Hains J, Leung DW, Ferrara N. Vascular endothelial growth factor is expressed in rat corpus luteum. *Endocrinology*. 1990 Aug;127(2):965-7.
123. Ferrara N, Chen H, Davis-Smyth T, Gerber HP, Nguyen TN, Peers D, et al. Vascular endothelial growth factor is essential for corpus luteum angiogenesis. *Nat Med*. 1998 Mar;4(3):336-40.
124. Fraser HM, Dickson SE, Lunn SF, Wulff C, Morris KD, Carroll VA, et al. Suppression of luteal angiogenesis in the primate after neutralization of vascular endothelial growth factor. *Endocrinology*. 2000 Mar;141(3):995-1000.

125. Zimmermann RC, Xiao E, Husami N, Sauer MV, Lobo R, Kitajewski J, et al. Short-term administration of anti-vascular endothelial growth factor antibody in the late follicular phase delays follicular development in the rhesus monkey. *J Clin Endocrinol Metab.* 2001 Feb;86(2):768-72.
126. Ferrara N, Houck K, Jakeman L, Leung DW. Molecular and biological properties of the vascular endothelial growth factor family of proteins. *Endocr Rev.* 1992 Feb;13(1):18-32.
127. Aiello LP, Avery RL, Arrigg PG, Keyt BA, Jampel HD, Shah ST, et al. Vascular endothelial growth factor in ocular fluid of patients with diabetic retinopathy and other retinal disorders. *N Engl J Med.* 1994 Dec 1;331(22):1480-7.
128. Petersen W, Tsokos M, Pufe T. Expression of VEGF121 and VEGF165 in hypertrophic chondrocytes of the human growth plate and epiphyseal cartilage. *Journal of Anatomy.* 2002;201(2):153-7.
129. Carlevaro M, Cermelli S, Cancedda R, Descalzi Cancedda F. Vascular endothelial growth factor (VEGF) in cartilage neovascularization and chondrocyte differentiation: auto-paracrine role during endochondral bone formation. *J Cell Sci.* 2000 January 1, 2000;113(1):59-69.
130. Evans KD, Oberbauer AM. Spatiotemporal Localization of VEGF-A Isoforms in the Mouse Postnatal Growth Plate. *The Anatomical Record: Advances in Integrative Anatomy and Evolutionary Biology.* 2008;291(1):6-13.
131. Horner A, Bishop NJ, Bord S, Beeton C, Kelsall AW, Coleman N, et al. Immunolocalisation of vascular endothelial growth factor (VEGF) in human neonatal growth plate cartilage. *J Anat.* 1999 May;194 (Pt 4):519-24.
132. Garcia-Ramirez M, Toran N, Andaluz P, Carrascosa A, Audi L. Vascular endothelial growth factor is expressed in human fetal growth cartilage. *J Bone Miner Res.* 2000 Mar;15(3):534-40.

133. Lüllmann H, Mohr K, Hein L. Pharmakologie und Toxikologie. Stuttgart: Thieme Verlag; 2006.
134. Kumar GL, Rudbeck L. Educational Guide: Immunohistochemical Staining methods [Guide]. Carpinteria: Dako North America; 2009 [cited 2009 10/12]. Available from: http://pri.dako.com/08002_ihc_staining_methods_5ed.pdf.
135. Ramos-Vara JA. Technical aspects of immunohistochemistry. Vet Pathol. 2005 Jul;42(4):405-26.
136. Hsu SM, Raine L, Fanger H. Use of avidin-biotin-peroxidase complex (ABC) in immunoperoxidase techniques: a comparison between ABC and unlabeled antibody (PAP) procedures. J Histochem Cytochem. 1981 Apr;29(4):577-80.
137. Guesdon J, Ternynck T, Avrameas S. The use of avidin-biotin interaction in immunoenzymatic techniques. J Histochem Cytochem. 1979 August 1, 1979;27(8):1131-9.
138. Martin EA, Ritman EL, Turner RT. Time course of epiphyseal growth plate fusion in rat tibiae. Bone. 2003 Mar;32(3):261-7.
139. Pufe T, Wildemann B, Petersen W, Mentlein R, Raschke M, Schmidmaier G. Quantitative measurement of the splice variants 120 and 164 of the angiogenic peptide vascular endothelial growth factor in the time flow of fracture healing: a study in the rat. Cell Tissue Res. 2002 Sep;309(3):387-92.
140. Uchida S, Sakai A, Kudo H, Otomo H, Watanuki M, Tanaka M, et al. Vascular endothelial growth factor is expressed along with its receptors during the healing process of bone and bone marrow after drill-hole injury in rats. Bone. 2003;32(5):491-501.
141. Carano RAD, Filvaroff EH. Angiogenesis and bone repair. Drug Discovery Today. 2003;8(21):980-9.

142. Komatsu DE, Hadjiargyrou M. Activation of the transcription factor HIF-1 and its target genes, VEGF, HO-1, iNOS, during fracture repair. *Bone*. 2004 Apr;34(4):680-8.
143. Street J, Bao M, deGuzman L, Bunting S, Peale FV, Ferrara N, et al. Vascular endothelial growth factor stimulates bone repair by promoting angiogenesis and bone turnover. *Proceedings of the National Academy of Sciences of the United States of America*. 2002 July 23, 2002;99(15):9656-61.
144. Street J. Vascular endothelial growth factor regulates osteoblast survival – evidence for an autocrine feedback mechanism. *J Orthop Surg Res*. 2009;4(19).
145. Fiedler J, Leucht F, Waltenberger J, Dehio C, Brenner RE. VEGF-A and PlGF-1 stimulate chemotactic migration of human mesenchymal progenitor cells. *Biochemical and Biophysical Research Communications*. 2005;334(2):561-8.

6 Attachments


6.1 VEGF Immunohistochemistry Staining Protocol

60	description of the slides (Number and Primary Antibody with pencil, remember to take one control slide for each secondary antibody), unfreeze slides for 60mins
30	5 mins rehydration in PBS+Tween
	15 mins H2O2 bath (150ml PBS and 1,5ml 30% H2O2)
	wash 3x2 mins in PBS+Tween
	draw PERFECT circle around sections with Dako pen - hydrophobic
60	prepare <u>goat</u> serum <ul style="list-style-type: none"> - blocking with 1:20 goat serum (60mins, RT, diluted with PBS, 100µL, box with lid) - don't wash afterwards, just knock on the table
	application of the <u>primary</u> antibody (see above): overnight at 4°C, 100µl, box with lid <ul style="list-style-type: none"> - Chicken poly; VEGF; Dil. 1:100 in Ak Diluent - Control slide: application of PBS
50	wash 3x2mins in PBS+Tween
	application of the <u>secondary</u> antibody: 100µL per section, 30mins, RT, box with lid: <ul style="list-style-type: none"> - Anti-Chicken biot. (ex goat), Dil.1:600
	Prepare ABC Complex as soon as sec. antibody is admitted: <ul style="list-style-type: none"> - 100µL per section - 1ml PBS and 20µl ABC-A and 20µl ABC-B - Store at 4°C at least for 30mins but less than 1 hour
	wash 3x2mins in PBS+Tween
40	Application of ABC Complex (30mins, RT, box with lid)
	wash 3x2mins in PBS+Tween warm up glycerine solution

40	AEC application, 2min 50sec , incubate in the dark! <ul style="list-style-type: none"> - CAVE: Gloves!! - 2 drops per section
	Stop the reaction in aqua dest., 30 sec – change aqua dest. – 3 min – remove
	counterstaining with Hämalaun Solution for 15 sec, wash in tapped water until water is clear
	put slides in NH ₄ -H ₂ O for several seconds, change aqua dest., then into aqua dest. again
	application of glycerine solution on slides, cover with glas

6.2 Oral Presentation

European Student Conference: October 3, 2009, Berlin



Medical University of Graz

**Bone Bridge Formation & Vascularisation after
Transphyseal Drill Hole Lesion in Young Rat Tibiae**

Seles M¹, Manninger M¹, Widni EE¹,
Neun U¹, Wadl L¹, Kuess AM¹, Kraitsy K¹,
Höllwart ME¹, Weinberg AM¹

1 Department of Pediatric Surgery, Medical University of Graz, Austria

Medizinische Universität Graz, Universitätsplatz 3, A-8010 Graz, www.meduni-graz.at

S

Seles M, Manninger M, Widni EE, Neun U, Wadl L, Kuess AM, Kraitsy K, Weinberg AM. “Bone Bridge Formation and Vascularisation after Transphysial Drill Hole Lesion in Young Rat Tibiae”. European Student Conference, Charité University Hospital Berlin; Oct 4, 2009; Berlin, Germany.

6.3 Poster Presentation

ZMF Day, November 5, 2009, Graz


Does VEGF induce bone bridge formation at the injured growth plate?

Widni Elva Elina¹, Seles Maximilian¹, Manninger Martin¹, Neun Ursula¹, Wadl Elisabeth¹, Kraitsy Klara¹, Dolejschi Mare-Therese¹, Hutter Helmut¹, Milz Stefan¹, Weinberg Annette-Martina¹


¹Department of Paediatric and Adolescent Surgery, Medical University Graz, Austria; ²Institute of Cell Biology, Histology and Embryology, Medical University Graz, Austria; SAO Institute, Davos, Switzerland

Introduction, Background and Aims:
Physal injuries can initiate the formation of reversible bone-bridges resulting in bone length discrepancy, axis deviation or joint deformity. We hypothesized that vascular endothelial growth factor (VEGF) and its receptor R1 and R2 are involved in the vascularization process leading to bone bridge formation at the site of physal injury.

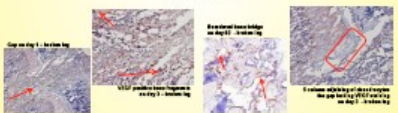
Material and Methods:
35 male Sprague Dawley rats (4 weeks old, weighing approximately 100g) were subjected to a unilateral drill injury through the proximal tibial physis. After euthanasia on days 1, 3, 7, 14, 28, 42 and 82 both tibiae were extracted. Tissue Samples of the growth plates were processed for immunohistochemical staining of VEGF and VEGFR1 and -R2 and hematoxyline and eosine staining according to standardized protocols. The contra-lateral intact growth plate samples served as controls.



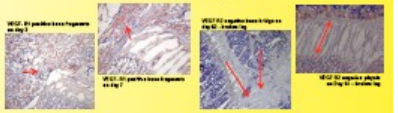
Safranin O Green



IHC - VEGF



IHC - VEGF-R



Results:
Histological staining displayed a hematoma on days 1 and 3 containing displaced bone fragments at the site of physal injury. On day 7, reorganization of these fragments was observed prior to bone bridge formation seen on day 14. By day 82, this bone bridge was replaced by lamellar bone. Immunohistochemical staining showed clear positivity for VEGF, VEGF-R1 and VEGF-R2 of the displaced bone fragments on days 1 to 7. Cells surrounding the bone bridge trabeculae were positive for VEGF while they were negative for VEGF-R1 and -R2. Physal chondrocytes adjacent to the lesion gap were initially negative for VEGF and positive from day 7 onwards. The physis remained VEGF-R2 negative throughout the days but was positive for VEGF-R1 with maximum levels on day 14.

Summary / Conclusion:
In conclusion, these data suggest that bone fragments from the physal injury are interacting with cells bordering the physal injury site and together initiate bone bridge formation via expression of the angiogenetic growth factor VEGF, and its receptors R1 and R2.

Seles M, Widni EE, Manninger M, Neun U, Wadl E, Kraitsy K, Dolejschi M, Hutter H, Milz S, Weinberg AM.

„Does VEGF induce bone bridge formation at the injured growth plate?“

Annual Research Meeting – Center for Medical Research, University Hospital of Graz; Nov 5, 2009; Graz, Austria. 2009.