

Master Thesis

Title

New insight in Dermoscopy of LM/LMM

submitted by

Dra. Keila Mitsunaga

for the academic degree

Master of Science (MSc)

at the

Medical University of Graz

executed as part of the

Master of Dermoscopy and Preventive Dermatoooncology

under the supervision of

Prof. Dra. Susana Puig

DECLARATION

I declare on my word of honor that I have written the present work independently, and without external assistance, I have not used sources other than those indicated, and that I have marked the passages taken from the sources used, either literally or in terms of content, as such.

Graz, July 18th, 2023.

Keila Mitsunaga

ÍNDEX

FOREWORD	4
INTRODUCTION	5
METHODS	7
RESULTS	9
DISCUSSION	11
CONCLUSION	13
BIBLIOGRAPHY	14
FIGURES AND CHARTS	16
TABLE	22
APPENDIX	27

FOREWORD

In March of 2021, a few months after my family and I moved from Brazil to Spain, I started as a dermatologist volunteer at the University Hospital 12 de Octubre (Madrid, Spain) on confocal microscopy as well as melanoma and lymphomas consultations. Usually, most of the cases we would receive from colleagues at confocal microscopy consultations were facial lesions. As the months passed by, I was drawn by the lentigo maligna cases, because a considerable part of them didn't match the typical Stolz dermoscopy criteria that I was taught on dermoscopy classes and courses.

I decided to review the topic and a closer look at Stolz classical article, published in 2000, revealed advanced lesions of lentigo maligna, the type of undoubtedly cases nowadays dermoscopy is a needless tool to perform the correct diagnosis. Along with the guidance of my mentor Prof. Dra. Susana Puig, I reviewed the cohort of lentigo maligna cases of Hospital Clinic in Barcelona and Hospital 12 de Octubre in Madrid with the aim to update the model proposed two decades ago based on real-life current cases.

This thesis is a result of lots amount of curiosity and a profound desire to clarify practical questions my colleagues and I have faced during our daily practice.

INTRODUCTION

The development of the term *lentigo maligna* invite us to go on a ride back to the past and take the journey former scientists have pathed in the last centuries until they've come up to this biological concept.

In 1891, the English doctor Sir Jonathan Hutchinson highlighted the appearance of skin cancer in senile freckles of older people, a type of transformation he named *Hutchinson's melanotic freckle*(2). This observation came in a period that the concepts of photobiology were still emerging and evidence that epitheliomas of the face, like solar lentigos were caused by sunlight began to appear. Few years late, the French dermatologist William Dubreuilh was the first writer to use the term *precancerous melanosis*, from which derived the eponym *Dubreuilh's melanosis*(3). Moreover, Dubreuilh observed what he described as a very rare phenomenon: precancerous melanosis could develop into melanomas.

Many eponyms associated with precursor melanoma lesions have been described on the literature: Hutchinson's melanotic freckle, Dubreuilh's melanosis, Allen's active junctional nevus, Kossard's lentiginous dysplastic nevus of the elderly. Some of what have been called senile patch are clearly lentigo maligna nowadays (Fig. 1).

In the 80s, Albert Bernard Ackerman challenged the idea of premalignant precursor lesions and popularized the theory of **melanoma in situ**(4). But it wasn't officially recognized until 1992, when the National Institutes of Health (NIH) Consensus finally adopted the concept of melanoma in situ(5). At that time, dermoscopy was evolving and relatively small melanomas started to be diagnosed with this in vivo technique. This remarkable progress was possible due to the important studies done by Pehamberger et al(6) who described dermoscopic parameters of pigmented skin lesions that are currently used today; Stolz et al(7) who introduced the ABCD rule of dermoscopy; Menzies et al(8) who provided a method for the diagnosis of invasive melanoma and Argenziano et al(9) who presented the 7-point checklist; just to name a few.

In 2000, Schiffner et al(10) from Stolz research group, published a seminal article determining four dermoscopic features (asymmetric pigmented follicular openings, dark rhomboidal structures, slate-gray dots, and slate-grey globules) that could detect lentigo maligna (LM) with high accuracy (96% of specificity and 89% of sensitivity). This study was based on 87 patients, who presented 37 malignant and 50 benign face lesions, all of them histologically proven. According to the results observed, the researchers developed a progression model of LM, that has been taught since then. This work was remarkable because

the dermoscopic criteria differed fundamentally from those Steiner, Pehamberger and Wolf(11) had postulated previously.

In 2012, after reviewing 125 cases of lentigo maligna, Pralong et al(12) presented four additional dermoscopic criteria (mainly vascular) to diagnosis LM: darkening at dermoscopic examination, target-like pattern, increased density of vascular network and red rhomboidal structures.

In the early 2010s, the advance of in vivo confocal microscopy (RCM) was a turning point on the diagnostic of LM. This technology enabled the visualization in vivo of the entire lesion with a cellular resolution, which allowed doctors to perform more accurate biopsies. Studies by Guitera et al(13) settled the RCM criteria to diagnose lentigo maligna, known as “LM score”. Those findings were echoed by Carvalho et al(1) who correlated RCM with dermoscopic patterns of 60 pigmented facial lesions.

There are different views about LM terminology. The English language literature use the term “Lentigo Maligna” for lentiginous melanomas in situ whereas “Lentigo Maligno Melanoma” to invasive lesions. Other authors(12) consider it two different stages of the same entity and refer as “Lentigo maligna melanoma” to all types of lentiginous melanomas on the face, regardless the Breslow thickness of the tumor. To better understanding, we will adopt the first classification, that distinguishes LM from LMM. Also, traditionally LM and LMM are lesions described on the face. For extrafacial LM and LMMs authors usually adopt the term “Lentigo Maligna Extrafacial” (LME), terminology we will adopt on this thesis.

After 20 years, we believe some others LM/LMM patterns could be described to reflect the current cases we are seeing on our daily practice. Therefore, we reviewed the cohort of lentigo maligna cases of two tertiary hospitals in Spain with the aim to update the model proposed two decades ago based on real-life current cases of the last 10 years.

METHODS

This retrospective study collected consecutive patients of 153 histologically proven lentigo maligna diagnosed between January 2011 and March 2023, from two tertiary referral centers (Melanoma Unit of Hospital Clinic, Barcelona, Spain and Department of Dermatology, Hospital 12 de Octubre, Madrid, Spain). Cases of recurrence were excluded.

Our cohort was built after reviewing all the LM/LMM cases of the Melanoma Unit at Hospital Clinic in Barcelona from the last 10 years. From the 470 LM/LMM facial and extrafacial cases, 277 cases were facial lesions and we found 133 cases that had dermoscopic images documentation (Fig 2). This gap of images occurs because Melanoma Unit of Hospital Clinic is a tertiary hospital and many melanomas' cases are sent to this center to be treated after a partially or excisional biopsy.

Also, not to be restricted to a single-center experience, I've reviewed the database and added all the LM cases from the University Hospital of 12 de Octubre in Madrid. Since it is a quite new database, I've founded 20 LM/LMM cases between January 2020 and April 2023.

Baseline and histopathological characteristics

We collected patient data regarding sex, race, phenotype, age at diagnosis, anatomic site of the tumor, histopathological type of LM/LMM and Breslow thickness.

Dermoscopic criteria

Twenty-eight dermoscopic criteria were analyzed (Table 1). Among those criteria we included:

- **Classical Stolz criteria**(10): hyperpigmented follicular opening, annular-granular pattern, short streaks, pigmented rhomboidal structures, obliterated hair follicles. Regarding hyperpigmented follicular opening, we've analyzed two subtypes, circle and double circle, and its type of distribution (regular or irregular).
- **Luc Thomas criteria**(12): darkening at dermoscopic examination, increased density of vascular network, red rhomboidal structures.
- **Perifollicular radial lines**: defined as radially arranged pigmented lines around a follicle, which correlates with the medusa head-like structures on confocal microscopy, recently described by Gamo et al(14).

- **Classical dermoscopic characteristics:** pseudonetwork, globules, dots, blotches and homogenous pigmentation. For each feature we've analyzed the presence of distinct colors: dark brown, light brown, black, blue, grey, red, white.
- **Regression:** peppering, hypopigmented areas, white scar-like areas, chrysalis/ white shine lines.
- **Vertical growth-phase:** ulceration, blue-white veil/ blue papular areas, polymorphic vessels.
- **Solar lentigo/ Flat seborrheic keratosis:** true pigmented network, parallel lines / fingerprinting, milia like-cysts, sharply demarcated border.
- **Actinic keratosis:** strawberry pattern, rosettes, superficial scales.

Clinical and Dermoscopic images

All clinical and dermoscopic images were retrospectively evaluated by a single author (K.M.) with supervision of a dermoscopy expert dermatologist (S.P.). Clinical photographs were taken by cameras with polarized light dermoscopy (Dermlite; 3Gen, San Juan Capistrano, CA, USA).

Objectives

Our primary aim is to describe the dermoscopic characteristics of LM/LMM from Barcelona and Madrid cohort.

Our secondary aim is to update the LM progression model proposed 20 years ago.

Ethics

This study was conducted in accordance with the Declaration of Helsinki and was approved by local ethics committees or institutional review boards (appendix 1).

Statistical analysis

The statistical analysis was performed with SPSS Statistics Version 29.0 (IBM Corp). Chi-square test and Fisher test were used for categorical variables and t-Student test for continuous variables; the level of significant was $p < 0.05$.

RESULTS

A total of 153 patients were included, 86 (56.2%) men and 67 (43.8%) women, mean age 72 years (range 31-97), all Caucasians. Regarding Fitzpatrick skin phototype, 9 (5.9%) were classified as type I, 93 (60.8%) as type II, 49 (32%) as type III, 2 (1.3%) as type IV.

Overall, there were 112 (73.2%) LM and 41 (26.8%) LMM. Female patients presented 51 (76.1%) LM and 16 (23.9%) LMM, while male patients had 61 (70.9%) LM and 25 (29.1%) LMM (Table 2). Among all LMM, median and mean Breslow thickness was 0.7mm and 2.1mm, respectively (range 0.2-25mm). Interestingly, female patients presented mean Breslow thickness of 0.75mm compared to 3.02mm of male counterpart. As Breslow thickness doesn't present a normal distribution, to calculate the statistical significance, we've converted this variable in a logarithmical distribution (Figure 3) and obtained a statistical significance of $p=0.013$ for logBreslow thickness.

The most affected anatomic site were cheeks and preauricular area in 67 cases (43.8%), followed by the frontal-temporal zone in 25 (16.3%), nose in 20 (13.1%), scalp in 17 (11.1%), ears in 14 (9.2%), lower face (perioral, mental, mandibular) in 6 (3.9%) and periocular/eyebrow in 4 (2.6%) (Table 3). The anatomic site distribution of LM/LMM cases varied according to gender: men had significant more affected the ear (13 vs 1 case; $p=0.004$) and the scalp (15 vs 2 cases; $p=0.005$) than women (Table 3). Also, more invasive lesions were presented on the ears ($p=0.047$) when compared to other anatomic sites.

Qualitative evaluation of LM/LMM clinical images

Analyzing all clinical images, we identified at least 4 different types of LM/LMM (Figure 4). The first type fulfills all the classical criteria of LM: a large macule, with multiple colors, ill-defined borders and geographical appearance. The second type appears as solar lentigo (SL)/ seborrheic keratosis (SK) like, with brown homogeneous color and very well-defined border. The third type mimics pigmented actinic keratosis (PAK) and lichen planus-like keratosis (LPLK) being clinically grey macules. The fourth type are small well defined dark pigmented lesions, that we consider clinically nevus-like. Finally, the fifth are amelanotic/hypomelanotic type, lesions that could be easily confused with actinic keratosis or Bowen disease.

Reviewing the clinical information, we detected that many of those lesions were misdiagnosed by different dermatologists for many years and treatments like cryotherapy and lasers were performed on these supposed benign lesions.

Dermoscopic findings

The most common dermoscopic findings were pseudonetwork irregularly distributed (129; 84.3%) and dots (119; 77.8%). Among Stolz criteria, hyperpigmented follicular opening was the most frequent feature (103; 67.3%), followed by short streaks (91; 59.5%), pigmented rhomboidal structures (72; 47.1%), annular-granular pattern (54; 35.3%) and obliterated hair follicles (43; 28.1%). Regarding Luc Thomas criteria, 80 (52.3%) cases presented increased density of vascular network, although red rhomboidal structures and darkening at dermoscopic examination had a low incidence (14; 9.2% and 6; 3.9%, respectively). Perifollicular radial lines were founded in 51 (33.3%) cases (Table 4).

Pseudonetwork presented an irregular distribution in 125 (81.7%) cases, with predominant brown and grey colors (77.1% and 48.4%; respectively). Dots were founded in 119 (77.8%) cases, prevailing grey and brown colors (58.2% and 50.3%; respectively). Additional classical dermoscopic pattern noticed were globules (57; 37.3%), homogeneous pigmentation (44; 28.8%) and blotches (36; 23.5%) (Table 5). Regression features were also observed: hypopigmented areas (66; 43.1%), white scar-like areas (49; 32.0%), peppering (26; 17.0%) and crysalids/ white-shine lines (18; 11.8%) (Table 4).

The presence of vertical growth-phase was related to blue-white veil/ blue papular areas in 10 (6.5%) cases, polymorphic vessels in 7 (4.6%) cases and ulceration in 3 (2%) cases. Benign dermoscopic pattern were also reported among our cohort: true pigmented network (21; 13.7%), superficial scales (14; 9.2%), rosettes (7; 4.6%), parallel lines/ fingerprinting (6; 3.9%) and strawberry pattern (6; 3.9%) (Table 4).

Dermoscopic findings correlated to invasive lesions

Comparison between LM and LMM revealed seven dermoscopic features significantly more frequently in LMM cases: increased density of vascular network ($p=0.0005$), blotches ($p=0.021$), ulceration ($p=0.004$), crysalids ($p<0.0000$), blue-white veil ($p=0.0001$), polymorphic vessels ($p<0.0000$) and superficial scales ($p=0.001$) (Table 6).

Not surprisingly, annular-granular pattern was more significantly associate with LM when compared LMM cases ($p=0.023$), as it is considered an early sign of LM.

DISCUSSION

This retrospective cohort study reviewed 153 cases of LM and LMM from two tertiary hospitals in Spain from the last 10 years. Overall, our cohort was most constituted by early-stage cases (73.2% LM versus 26.8% LMM). Interestingly, female patients presented a significant low mean Breslow thickness compared to male counterpart (0.75mm vs 3.02mm; respectively; $p=0.013$). These findings are echoed by many studies in the literature, which point out male gender having more risk of advanced melanomas.

The anatomic tumor location revealed important differences between male and female. Men had more frequently LM/LMM on the ears and on the scalp, while women had predominant lesions on the mid and lower face. These differences can be explained by biological differences: men tend to be more affected by hereditary hair loss than women, reason why the scalp and the ears may be more impacted by the effects of sunlight damage.

Our results confirm that the most frequent dermoscopic features presented were pseudonetwork (84.3%) and dots (77.8%), which are clearly not specific criteria for LM. Carvalho et al(13) also observed that pseudonetwork was the most common dermoscopic features both in benign and malignant lesions. These finding is echoed by Lallas et al(15) who suggested the “inverse approach” – which consist to biopsy all lesions that cannot be confident determined as solar lentigo/ seborrheic keratosis and actinic keratosis – to increase the sensitivity to diagnose a LM. His studies showed that the mean sensitivity for LM diagnosis after training on pattern analysis was 56.7% versus 83.6% after learning the inverse approach.

The most frequently Stolz criteria(10) founded was irregular hyperpigmented follicular opening (67.3%), followed by short streaks (59.5%), pigmented rhomboidal structures (47.1%), annular-granular pattern (35.3%) and obliterated hair follicles (28.1%).

Concerning Luc Thomas criteria, 80 (52.3%) cases presented increased density of vascular network, quite similar to the 58% founded on the original paper(12). However, red rhomboidal structures and darkening at dermoscopic examination had a lower incidence (9.2% and 3.9% respectively; versus 40% and 25%). Those differences may be explained by the higher number of advanced cases presented on their cohort (73% LMM versus 25% LMM in our study).

In 2022, Gamo et al(14) described perifollicular radial lines (PRL) as another LM criteria. It is defined as radially arranged pigmented lines around a follicle, which correlates with the medusa head-like structures on confocal microscopy. In our study, PRL were founded in 51 (33.3%) cases and we couldn't find other studies on the literature for comparison.

Not surprisingly, dermoscopic features related to invasive lesions were increased density of vascular network, blotches, ulceration, crystals or white shine lines, blue-white veil, polymorphic vessels and superficial scales. These characteristics have been already associated with advanced tumors.

Based on the qualitative evaluation of the clinical images, we described five different clinical patterns LM/LMM may appear: classic type, SL/ SK type, PAK/ LPLK type, nevus-like type, amelanotic/hypomelanotic type (Figure 4). Certainly, it demonstrates how challenge can be the clinical diagnosis of LM/LMM and reinforces the importance to apply the dermatoscope in all lesions, even when we can be quite sure of its diagnosis by clinical inspection. Clinical features that can lead to misdiagnose are patients with young age and lesions of small size, light brown color and well-defined borders. Although LM/LMM are typically associated with old patients, in our study the youngest patient presented 31 years old at the time of detection. Of note, our cohort is constituted of cases from two tertiary hospitals, equipped with reflectance confocal microscopy (RCM), which enables the visualization of the lesion with cellular resolution and allows the selection of the biopsy site more precisely.

Moreover, the early detection of LM – which can be considered slow growing tumors – may raise the question whether we are over-diagnosing and over-treating melanomas that wouldn't change patient's life expectancy(16). The “melanoma epidemic” may be a result of advanced imaging technologies in tumor detection, like dermoscopy and confocal microscopy; and the lower threshold of pathologists to perform a melanoma diagnosis(17). Ultimately, we must admit that the current scientific knowledge cannot predict the clinical behavior of a melanoma. Even a small diameter LM, which appears as a harmless light-brown macule featureless of classical malign criteria, may evolve into invasive lesions, as revealed in our cohort (Figure 5). This uncertain evolution compels us to treat all melanomas we diagnose. Certainly, in the future a holistic approach incorporating genetic profile with other advanced imaging technologies will be able to determine accurately melanoma management(18).

A limitation of our study is the absence of RCM correlation with dermoscopic images. Moreover, the absence of a histopathological “exhaustive” analysis raises the question whether the clinical variants of LM described as SL/ SK type and PAK/ LPLK type could be LM/LMMs combined with other benign lesions. As pathologists tend to highlight the “worst” diagnosis, benign lesions that could be presented within the LM could have been ignored on the histopathological report. To answer this question, a detailed histopathological analysis would have been necessary.

CONCLUSION

In conclusion, our cohort of 153 LM/LMM cases revealed that the most frequently dermoscopy features were pseudonetwork and dots, which are not specific malignant criteria. We also demonstrated that LM/LMM may clinically and dermoscopically mimic benign lesions. Being aware of this challenge is crucial to avoid mistreatment and late diagnosis that can lead to patient morbidity and radical surgical treatments.

BIBLIOGRAPHY

1. Hutchinson J. Seniles Freckles, Archives of Surgery. Vol. 3. 1891. 319–322 p.
2. Dubreuilh W. Lentigo malin des vieillards. Ann Dermatol Syph. 1912;3:129–54.
3. Ackerman AB. Macular and patch lesions of malignant melanoma: malignant melanoma in situ. J Dermatol Surg Oncol. 1983 Aug;9(8):615–8.
4. Diagnosis and treatment of early melanoma. NIH Consensus Development Conference. January 27-29, 1992. Consensus Statement. 10(1):1–25.
5. Pehamberger H, Steiner A, Wolff K. In vivo epiluminescence microscopy of pigmented skin lesions. I. Pattern analysis of pigmented skin lesions. J Am Acad Dermatol. 1987 Oct;17(4):571–83.
6. Nachbar F, Stolz W, Merkle T, Cagnetta AB, Vogt T, Landthaler M, et al. The ABCD rule of dermatoscopy. High prospective value in the diagnosis of doubtful melanocytic skin lesions. J Am Acad Dermatol. 1994 Apr;30(4):551–9.
7. Menzies SW, Ingvar C, McCarthy WH. A sensitivity and specificity analysis of the surface microscopy features of invasive melanoma. Melanoma Res. 1996 Feb;6(1):55–62.
8. Argenziano G, Fabbrocini G, Carli P, De Giorgi V, Sammarco E, Delfino M. Epiluminescence microscopy for the diagnosis of doubtful melanocytic skin lesions. Comparison of the ABCD rule of dermatoscopy and a new 7-point checklist based on pattern analysis. Arch Dermatol. 1998 Dec;134(12):1563–70.
9. Schiffner R, Schiffner-Rohe J, Vogt T, Landthaler M, Wlotzke U, Cagnetta AB, et al. Improvement of early recognition of lentigo maligna using dermatoscopy. J Am Acad Dermatol. 2000;42(1 I):25–32.
10. Steiner A, Pehamberger H, Wolff K. In vivo epiluminescence microscopy of pigmented skin lesions. II. Diagnosis of small pigmented skin lesions and early detection of malignant melanoma. J Am Acad Dermatol. 1987 Oct;17(4):584–91.
11. Pralong P, Bathelier E, Dalle S, Poulalhon N, Debarbieux S, Thomas L. Dermoscopy of lentigo maligna melanoma: Report of 125 cases. British Journal of Dermatology. 2012 Aug;167(2):280–7.
12. Guitera P, Pellacani G, Crotty KA, Scolyer RA, Li LXL, Bassoli S, et al. The impact of in vivo reflectance confocal microscopy on the diagnostic accuracy of lentigo maligna and equivocal pigmented and nonpigmented macules of the face. Journal of Investigative Dermatology. 2010 Aug;130(8):2080–91.

13. De Carvalho N, Farnetani F, Ciardo S, Ruini C, Witkowski AM, Longo C, et al. Reflectance confocal microscopy correlates of dermoscopic patterns of facial lesions help to discriminate lentigo maligna from pigmented nonmelanocytic macules. *British Journal of Dermatology*. 2015 Jul 1;173(1):128–33.
14. Gamo Villegas R, Floristán Muruzábal MU, Pampín Franco A. Imágenes perifoliculares radiales y en cabeza de medusa como signo de sospecha de lentigo maligno. *Actas Dermosifiliogr*. 2022 Oct;
15. Lallas A, Lallas K, Tschandl P, Kittler H, Apalla Z, Longo C, et al. The dermoscopic inverse approach significantly improves the accuracy of human readers for lentigo maligna diagnosis. *J Am Acad Dermatol*. 2021 Feb;84(2):381–9.
16. Welch HG, Mazer BL, Adamson AS. The Rapid Rise in Cutaneous Melanoma Diagnoses. *New England Journal of Medicine*. 2021 Jan 7;384(1):72–9.
17. Kittler H. Evolution of the Clinical, Dermoscopic and Pathologic Diagnosis of Melanoma. *Dermatol Pract Concept*. 2021 Jul 28;2021163S.
18. Nufer BB, BiomedSci KL, Raphael AP, Soyer HP. Dermoscopy and overdiagnosis of melanoma in situ. Vol. 154, *JAMA Dermatology*. American Medical Association; 2018. p. 398–9.

FIGURES AND CHARTS

Figure 1 – Textbook of dermatology published in 1917, describing a “pigmented senile patch, non-malignant”. This lesion clinically is clearly a lentigo maligna. (Pusey WA. The Principles and Practice of Dermatology: Designed for Students and Practitioners. New York, NY: Appleton; 1917).



PIGMENTED SENILE PATCH

“Developed to its present size in the course of a few years. Non-malignant. (Author's collection.)”

Figure 2 – Flowchart presenting included and excluded cases of Barcelona cohort from the last 10 years.

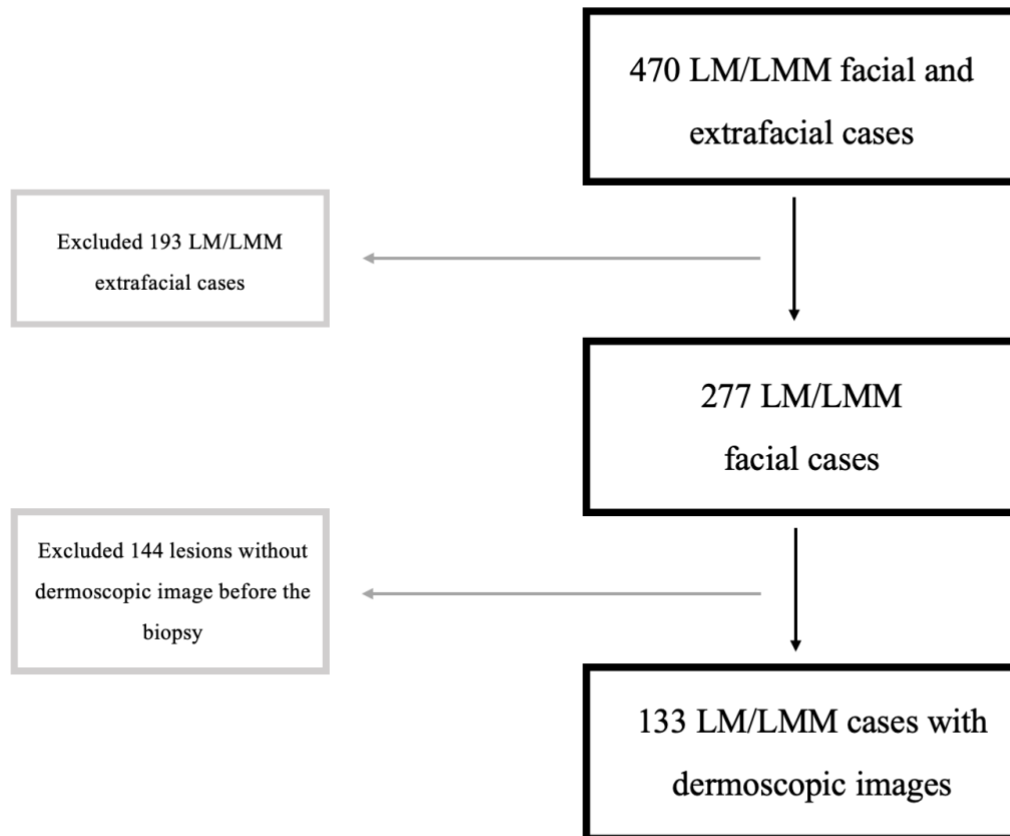


Figure 3 – Normal distribution versus logarithmical distribution of Breslow thickness (mm).

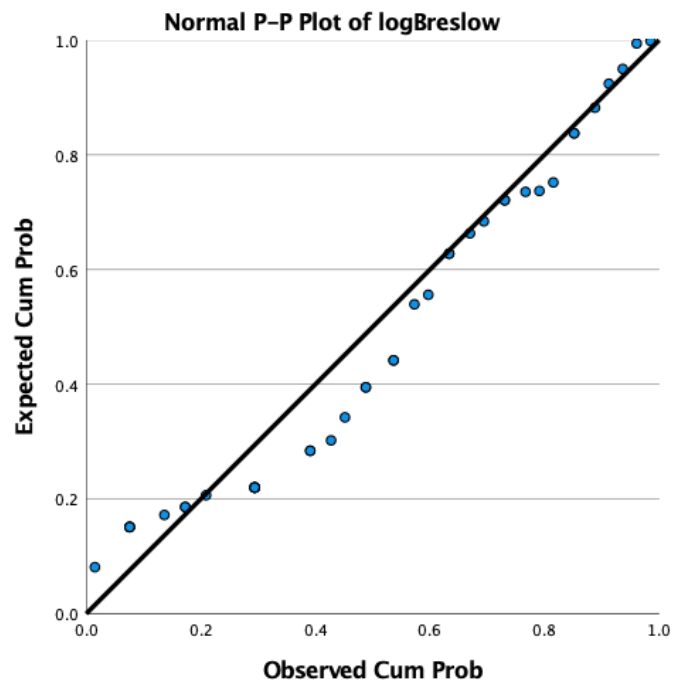
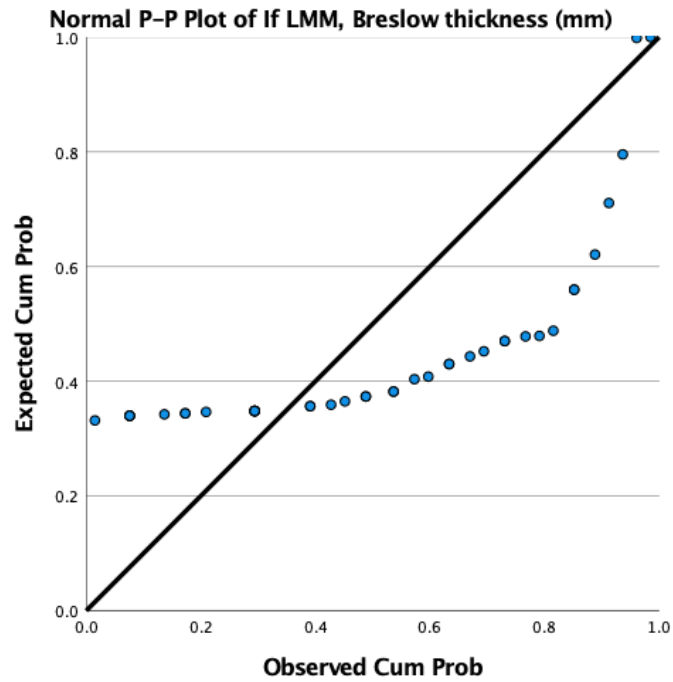
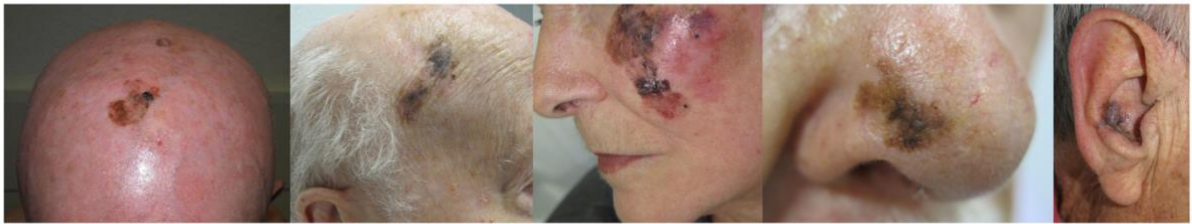
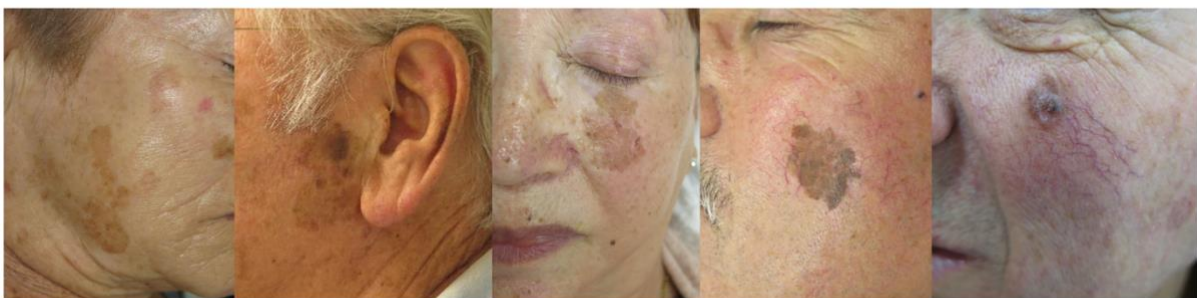
Figure 4 – Clinical types of LM patterns

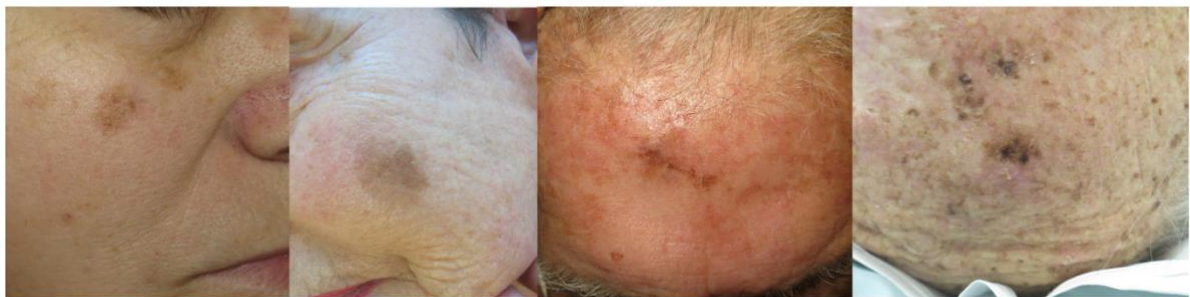Classic LM



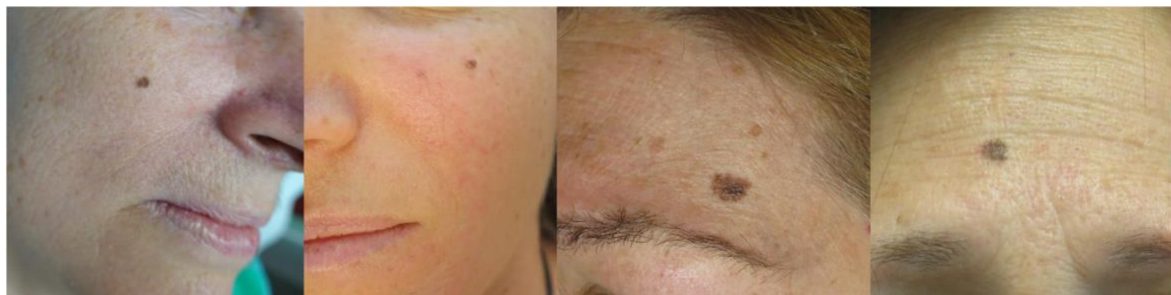Solar lentigo/ Seborrheic keratosis type



Pigmented actinic keratosis/ LPLK type



Nevus-like



Hypomelanotic / Amelanotic type

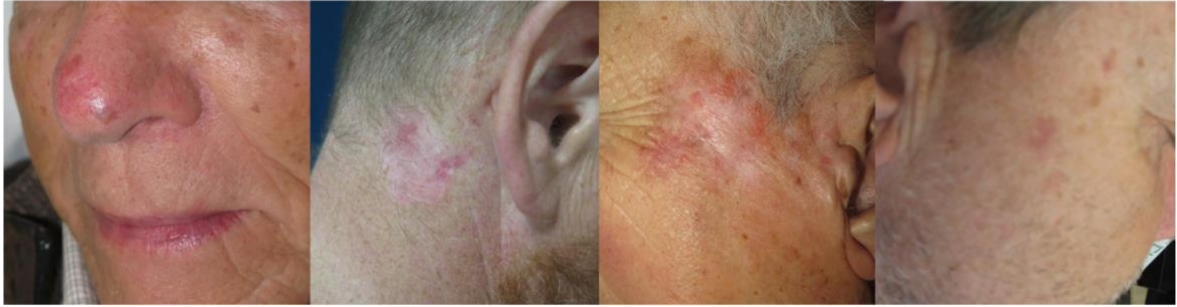
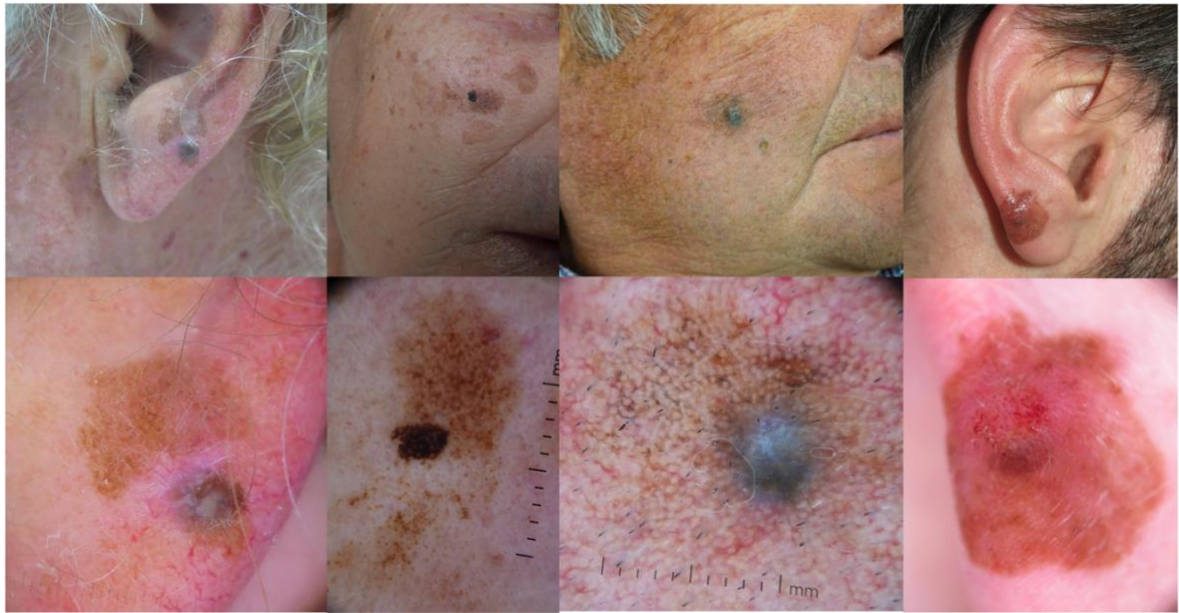
Figure 5 – Invasive tumors. Note that the periphery of the nodule presents a brown macule featureless of classical malign criteria.



TABLES

Table 1 – Dermoscopic criteria studied.

Table 1: Dermoscopic criteria
Classical Stolz criteria
Hyperpigmented follicular opening
Circle
Double circle
Regular distribution
Irregular distribution
Annular-granular pattern
Short streaks
Pigmented rhomboidal structures
Obliterated hair follicles
Luc Thomas criteria
Darkening at dermoscopic examination
Increased density of vascular network
Red rhomboidal structures
Gamo Villegas criteria
Perifollicular radial lines
Classical dermoscopic features
Pseudonetwork
Regular or irregular
Colors: brown, black, blue, grey, red
Globules
Colors: brown, black, blue, grey, red
Distribution: no pattern, perifollicular, in line, in the center
Dots
Colors: brown, black, blue, grey
Distribution: no pattern, perifollicular, in line, in the center
Blotches
Colors: brown, black, blue, grey, red, white
Homogeneous pigmentation
Colors: brown, black, blue, grey, red, white
Regression features
Peppering
Hypopigmented areas
White scar-like areas
Cystalids/ White shine lines
Vertical growth-phase
Ulceration
Blue-white veil/ Blue papular areas
Polymorphic vessels

Solar lentigo/ Flat seborrheic keratosis
True pigmented network
Parallel lines/ Fingerprinting
Milia like-cysts
Sharply demarcated border
Actinic keratosis
Strawberry pattern
Rosettes
Superficial scales

Table 2. Type of tumor

Table 2: Type of tumor						
	Total	%	Female	%	Male	%
LM	112	73,2	51	76.1	61	70.9
LMM	41	26,8	16	23.9	25	29.1

Table 3. Anatomic site

Table 3: Anatomic site								
n=153	Total	%	Female	%	Male	%	P-value	
Fronto-temporal	25	16.3	9	13.4	16	18.6	0.391	
Nose	20	13.1	8	11.9	12	14.0	0.714	
Periocular and eyebrows	4	2.6	2	3.0	2	2.3	0.800	
Cheeks and preauricular	67	43.8	40	59.7	27	31.4	0.000	
Lower face	6	3.9	5	7.5	1	1.2	0.046	
Ears	14	9.2	1	1.5	13	15.1	0.004	
Scalp	17	11.1	2	3.0	15	17.4	0.005	

Table 4 – Dermoscopic findings Part 1.

Table 4: Dermoscopic findings – part 1		
Classical Stolz criteria	n	%
Hyperpigmented follicular opening	103	67.3
Circle	103	67.3
Double circle	7	4.6
Regular distribution	0	
Irregular distribution	103	67.3
Annular-granular pattern	54	35.3
Short streaks	91	59.5
Pigmented rhomboidal structures	72	47.1
Obliterated hair follicles	43	28.1
Luc Thomas criteria		
Darkening at dermoscopic examination	6	3.9
Increased density of vascular network	80	52.3
Red rhomboidal structures	14	9.2
Gamo Villegas criteria		
Perifollicular radial lines	51	33.3
Regression features		
Peppering	26	17.0
Hypopigmented areas	66	43.1
White scar-like areas	49	32.0
Crysalids/ White shine lines	18	11.8
Vertical growth-phase		
Ulceration	3	2.0
Blue-white veil/ Blue papular areas	10	6.5
Polymorphic vessels	7	4.6
Solar lentigo/ Flat seborrheic keratosis		
True pigmented network	21	13.7
Parallel lines/ Fingerprinting	6	3.9
Milia like-cysts	3	2.0
Sharply demarcated border	2	1.3
Actinic keratosis		
Strawberry pattern	6	3.9
Rosettes	7	4.6
Superficial scales	14	9.2

Table 5 – Dermoscopic findings Part 2.

Table 5: Dermoscopic findings – part 2		
Classical dermoscopic features	n	%
Pseudonetwork	129	84.3
Regular distribution	4	2.6
Irregular distribution	125	81.7
Brown color	118	77.1
Black color	14	9.2
Blue color	2	1.3
Grey color	74	48.4
Red color	39	25.5
Numbers of colors: 1	39	25.5
Numbers of colors: 2	59	38.6
Numbers of colors: 3	28	18.3
Numbers of colors: 4	2	1.3
Globules	57	37.3
Brown color	49	32.0
Black color	15	9.8
Blue color	0	
Grey color	15	9.8
Red color	3	2.0
Numbers of colors: 1	31	20.3
Numbers of colors: 2	26	37.3
Numbers of colors: 3	0	
No pattern distribution	47	30.7
Perifollicular distribution	9	5.9
Dots	119	77.8
Brown color	77	50.3
Black color	9	5.9
Blue color	2	1.3
Grey color	89	58.2
Numbers of colors: 1	65	42.5
Numbers of colors: 2	50	32.7
Numbers of colors: 3	4	2.6
Numbers of colors: 4	0	
No pattern distribution	72	47.1
Perifollicular distribution	46	30.1
Blotches	36	23.5
Brown color	22	14.4
Black color	13	8.5
Blue color	7	4.6
Grey color	12	7.8
Red color	3	2.0

Numbers of colors: 1	17	11.1
Numbers of colors: 2	16	10.5
Numbers of colors: 3	3	2.0
Numbers of colors: 4	0	
Homogeneous pigmentation	44	28.8
Brown color	43	28.1
Black color	2	1.3
Grey color	3	2.0
Red color	4	2.6
Numbers of colors: 1	35	22.9
Numbers of colors: 2	7	4.6
Numbers of colors: 3	1	0.7
Numbers of colors: 4	0	

Table 6 – Dermoscopic findings correlated to LMM.

Table 6: Dermoscopic findings correlated to LMM						
n=153	LM (n=112)	%	LMM (n=41)	%	P-value	
Increased vascular network	49	43.8	31	75.6	<0.001	
Blotches	21	18.8	15	36.6	0.021	
Crysalids	6	5.4	12	29.3	<0.001	
Ulceration	0		3	7.3	0.004	
Blue white-veil	2	1.8	8	19.5	<0.001	
Polymorphic vessels	0		7	17.1	<0.001	
Superficial scales	5	4.5	9	22	0.001	

APPENDIX

Appendix 1 – Study approval by local ethic committee.

DICTAMEN DEL COMITÉ DE ÉTICA DE LA INVESTIGACIÓN CON MEDICAMENTOS

ANA LUCIA ARELLANO ANDRINO, Secretario del **Comité de Ética de la Investigación con medicamentos del Hospital Clínic de Barcelona**

Certifica:

Que este Comité ha evaluado la propuesta del promotor, para que se realice el estudio:

CÓDIGO:

DOCUMENTOS CON VERSIONES:

Tipo	Subtipo	Versión
Protocolo	Revisió històries clíniques	Versión 2, 6 de mayo 2022

TÍTULO: Análisis retrospectivo de los casos de léntigo maligno y léntigo maligno melanoma tratados en el Hospital Clínic de Barcelona en los últimos 20 años

PROMOTOR:

INVESTIGADOR PRINCIPAL: KATHERINE DROPELMANN ; SUSANA PUIG SARDÁ

y considera que, teniendo en cuenta la respuesta a las aclaraciones solicitadas (si las hubiera), y que:

- Se cumplen los requisitos necesarios de idoneidad del protocolo en relación con los objetivos del estudio y están justificados los riesgos y molestias previsibles.
- La capacidad del investigador y los medios disponibles son apropiados para llevar a cabo el estudio.
- Que se han evaluado la compensaciones económicas previstas (cuando las haya) y su posible interferencia con el respeto a los postulados éticos y se consideran adecuadas.
- Que dicho estudio se ajusta a las normas éticas esenciales y criterios deontológicos que rigen en este centro.
- Que dicho estudio cumple con las obligaciones establecidas por la normativa de investigación y confidencialidad que le son aplicables.
- Que dicho estudio se incluye en una de las líneas de investigación biomédica acreditadas en este centro, cumpliendo los requisitos necesarios, y que es viable en todos sus términos.

Este CEIm acepta que dicho estudio sea realizado, debiendo ser comunicado a dicho Comité Ético todo cambio en el protocolo o acontecimiento adverso grave.

y hace constar que:

1º En la reunión celebrada el día 07/04/2022, acta 7/2022 se decidió emitir el informe correspondiente al estudio de referencia.

Mod_04 (V4 de 18/06/2018)

Reg. HCB/2022/0353

PR

Página 1/3

2º El CEIm del Hospital Clínic i Provincial, tanto en su composición como en sus PNTs, cumple con las normas de EMA/CHMP/ICH/135/1995

3º Listado de miembros:

Presidente:

- JOSEP MARÍA MIRÓ MEDA (Médico Enfermedades Infecciosas, HCB)

Vicepresidente:

- JULIO DELGADO GONZÁLEZ (Médico Hematólogo, HCB)

Secretario:

- ANA LUCIA ARELLANO ANDRINO (Médico Farmacólogo Clínico, HCB)

Vocales:

- JOSE RIOS GUILLERMO (Estadístico. Plataforma de Estadística Médica. IDIBAPS)
- OCTAVI SANCHEZ LOPEZ (Representante de los pacientes)
- MARIA JESÚS BERTRAN LUENGO (Médico Epidemiólogo, HCB)
- JOAQUÍN SÁEZ PEÑATARO (Médico Farmacólogo Clínico, HCB)
- SERGI AMARO DELGADO (Médico Neurólogo, HCB)
- EDUARD GUASCH CASANY (Médico Cardiólogo, HCB)
- MARINA ROVIRA ILLAMOLA (Farmacéutico Atención Primaria, CAP Eixample)
- PAU ALCUBILLA PRATS (Médico Farmacólogo Clínico, HCB)
- JOSE TOMAS ORTIZ PEREZ (Médico Cardiólogo, HCB)
- ELENA CALVO CIDONCHA (Farmacéutica Hospitalaria, HCB)
- CECILIA CUZCO CABELLOS (Enfermera, HCB)
- PAULA MARTÍN FARGAS (Abogada, HCB)
- SALVATORE BRUGALETTA (Médico Cardiólogo, HCB. Miembro del CEA, HCB)
- XAVIER CANALS-RIERA (Ingeniero Telecomunicaciones)
- FRANCESC XAVIER CORBELLE (Informático, HCB)
- JOSEP DÍAZ CORT (Licenciado en Ciencias Físicas. Catedrático en Informática)
- GASPAR MESTRES ALOMAR (Médico, Angiología, Cirugía Vasculat, HCB)
- MARTA FRANCH SAGUER (Abogada)
- PATRICIA AMOROS REBOREDO (Farmacéutica Hospitalaria, HCB)
- ANNA MARÍA GUIJARRO PÉREZ (Servicio de Atención a la Ciudadanía, HCB)

En el caso de que se evalúe algún proyecto del que un miembro sea investigador/colaborador, este se ausentará de la reunión durante la discusión del proyecto.

Para que conste donde proceda, y a petición del promotor,

Motivo: Certifica la precisión e
integridad de este documento
Fecha: 2022.06.02 14:38:38 +02'00'

Mod_04 (V4 de 18/06/2018)

Reg. HCB/2022/0353

PR

Página 2/3

DICTAMEN DEL COMITÉ ÉTICO DE INVESTIGACIÓN CLÍNICA

NEUS RIBA GARCIA, Secretaria del **Comité Ético de Investigación Clínica del Hospital Clínic de Barcelona**

Certifica:

Que este Comité ha evaluado la propuesta del promotor, para que se realice el estudio:

DOCUMENTOS CON VERSIONES:

Tipo	Subtipo	Versión
Hoja Información de Paciente	V 1.0 6 Febrer 2015	v1_6_feb_15
Protocolo	V 1.0 6 Febrer 2015	v1_6_Feb_15

TÍTULO: "XARXA DE CENTRES DE MELANOMA" DATA SHEARING PLATFORM

INVESTIGADOR PRINCIPAL: SUSANA PUIG SARDÁ

y considera que, teniendo en cuenta la respuesta a las aclaraciones solicitadas (si las hubiera), y que:

- Se cumplen los requisitos necesarios de idoneidad del protocolo en relación con los objetivos del estudio y están justificados los riesgos y molestias previsibles.
- La capacidad del investigador y los medios disponibles son apropiados para llevar a cabo el estudio.
- Que se han evaluado la compensaciones económicas previstas (cuando las haya) y su posible interferencia con el respeto a los postulados éticos y se consideran adecuadas.
- Que dicho estudio se ajusta a las normas éticas esenciales y criterios deontológicos que rigen en este centro.
- Que dicho estudio se incluye en una de las líneas de investigación biomédica acreditadas en este centro, cumpliendo los requisitos necesarios, y que es viable en todos sus términos.

Este CEIC acepta que dicho estudio sea realizado, debiendo ser comunicado a dicho Comité Ético todo cambio en el protocolo o acontecimiento adverso grave.

y hace constar que:

1º En la reunión celebrada el día 09 de abril de 2015, acta 7/2015 se decidió emitir el informe correspondiente al estudio de referencia.

2º El CEIC del Hospital Clínic i Provincial, tanto en su composición como en sus PNTs, cumple con las normas de BPC (CPMP/ICH/135/95)

3º Listado de miembros:

Presidente:

- FRANCISCO JAVIER CARNE CLADELLAS (Médico Farmacólogo Clínico, HCB)

Vicepresidente:

- BEGOÑA GÓMEZ PÉREZ (Farmacéutica Hospitalaria, HCB)

HOSPITAL CLÍNIC DE BARCELONA
Villarroel, 170 - 08036 Barcelona (España)
Tel. 93 227 54 00 Fax 93 227 54 54
www.hospitalclinic.org

Secretario:

- NEUS RIBA GARCIA (Médico Farmacólogo Clínico, HCB)

Vocales:

- ITZIAR DE LECUONA (Jurista, Observatorio de Bioética y Derecho, UB)
- MONTSERRAT GONZALEZ CREUS (Trabajadora Social, Servicio de Atención al Usuario, HCB)
- MIRIAM MENDEZ GARCÍA (Abogada, HCB)
- MONTSERRAT NUÑEZ JUÁREZ (Enfermera, HCB)
- JOSE RIOS GUILLERMO (Estadístico, Farmacología Clínica, USEM, UASP, HCB)
- JOSE MIGUEL SOTOCA (Farmacéutico Atención Primaria, CAP Les Corts)
- ANTONI TRILLA GARCIA (Médico Epidemiólogo, HCB - Director UAPS)
- OCTAVI SANCHEZ LOPEZ (Representante de los pacientes)
- MARIA JESÚS BERTRAN LUENGO (Médico Epidemiólogo, HCB)
- MARTA AYMERICH GREGORIO (Médico Hematólogo, HCB)

En el caso de que se evalúe algún proyecto del que un miembro sea investigador/colaborador, este se ausentará de la reunión durante la discusión del proyecto.

Para que conste donde proceda, y a petición del promotor,

Barcelona, a 14 de abril de 2015



CLÍNIC
BARCELONA
Hospital Universitari
COMITÈ ÈTIC
INVESTIGACIÓ CLÍNICA

Reg. HCB/2015/0298

Mod_04 (V1 de 28/11/13)

PR