

Diploma Thesis

**Advanced isolated free light chain cardiomyopathy with
negative immunofixation and normal free light chain
ratio**

submitted by

David Kajetan Zach

in fulfilment of the requirements for the academic degree of

Doktor der gesamten Heilkunde

(Dr. med. univ.)

at the

Medical University of Graz

conducted at the

Department of Internal Medicine

Division of Cardiology

under the supervision of

Priv.-Doz. Dr. med. univ. et scient. med. Nicolas Verheyen

Graz, August 26th 2021

Affidavit

I hereby declare that this thesis is my own original work and that I have mentioned by name all persons and organisations that contributed to the research for this thesis; I have not used any sources other than those specified in the thesis itself and clearly attributed any used concepts or quotations applicable to these sources.

Graz, August 26th 2021

David Kajetan Zach eh.

Acknowledgements

I would like to acknowledge everyone who supported me throughout my time at the Medical University of Graz and played a part in completing this academic accomplishment.

First of all, my family, who supported me with love and understanding. Without you, I could never have progressed up to this point.

Secondly, Priv.-Doz. DDr. Nicolas Verheyen, who has opened the world of research to me and patiently guided my first steps.

Furthermore, all physicians involved in the management of the patient concerned, in particular (in alphabetical order) Dr. Klemens Ablasser, Prof. Dr. Christine Beham-Schmid, Prof. Dr. Friedrich Fruhwald, Dr. Viktoria Höller, DDr. Ewald Kolesnik, Prof. Dr. Rainer Lipp, Priv.-Doz. Dr. Florian Prüller, Priv.-Doz. DDr. Peter Rainer, Dr. Clemens Reiter, Prof. Dr. Albert Wölfler, and Prof. Dr. Andreas Zirlik; each had a crucial role in the care of the patient and provided vital information to the case report. Thank you all for your support and excellent collaboration.

Additionally, I thank the Institut Kardiale Diagnostik und Therapie Berlin and Dr. Clemens Reiter for providing their micrographs of biopsy specimen and cardiac magnetic resonance images, respectively.

Finally, I thank the patient for providing her informed consent for publication of this case report.

Table of Contents

Acknowledgements	1
Table of Contents	2
List of Abbreviations	3
List of Figures.....	4
Zusammenfassung	5
Abstract.....	6
Information on publications already made	7
Introduction	8
Case Report	9
Discussion.....	13
Conclusion.....	16
List of References.....	17

List of Abbreviations

^{99m} Tc	Technetium-99m
AL	amyloid light chain
DPD	3,3-diphosphono-1,2-propanodicarboxylic acid
eGFR	estimated glomerular filtration rate
EMB	endomyocardial biopsy
FLC	free light chain
HCM	Hypertrophic Cardiomyopathy
LV	left ventricular
NT-proBNP	N-terminal pro brain natriuretic peptide
NYHA	New York Heart Association
TTR	transthyretin

List of Figures

FIGURE 1

Transthoracic echocardiography showed a left ventricular ejection fraction of 47% and (A) pronounced concentric bi-ventricular hypertrophy; (B) left ventricular global longitudinal strain of 9.1% with significant relative apical sparing; and (C) a restrictive transmitral filling pattern with an E/A ratio of 2.18 (as published in (1)). 9

FIGURE 2

Cardiac magnetic resonance imaging. (A,B) Native myocardial T1 and extracellular volume mapping revealed increased values for both parameters (1411 ± 83 ms, z-score = 7; and $69 \pm 7\%$, z-score = 15, respectively); (C,D) left ventricular (LV) mid and apical segments portrayed subendocardial late gadolinium enhancement, while the basal segments showed a transmural pattern. In the right ventricle, global late gadolinium enhancement was present; (E,F) Post-contrast T1 maps confirmed transmural accumulation of the contrast agent at basal LV and right ventricular myocardial segments, as well as global subendocardial accumulation of the contrast agent at mid-ventricular to apical LV and right ventricular myocardial segments; (G-I) global LV myocardial T2 times were within the normal range excluding myocardial oedema (as published in (1)). 10

FIGURE 3

Histopathological analysis of Congo-red stained endomyocardial biopsy specimen demonstrating perivascular (*) and interstitial (→) myocardial amyloid depositions (Congo-red stain, $\times 200$) (as published in (1)). 11

Zusammenfassung

Die im Zuge einer Leichtketten-Amyloidose entstehende Kardiomyopathie ist die mit dem schwerwiegendsten Verlauf. Nach internationalen Empfehlungen sollte sie nicht-invasiv anhand der freien Leichtketten-Ratio im Serum sowie der Immunfixationselektrophorese im Serum und Urin ausgeschlossen werden. Dieser Fallbericht handelt von einer 69-jährigen Patientin mit neu aufgetretener Herzinsuffizienz mit mittlerer Ejektionsfraktion. Die kardiale Bildgebung lieferte Hinweise für eine zugrundeliegende kardiale Amyloidose. In der Amyloid-Szintigraphie zeigte sich eine myokardiale Anreicherung des verabreichten Radiopharmakons gemäß eines Perugini Scores von 1. In der Immunfixationselektrophorese konnte keine monoklonale Gammopathie objektiviert werden und die freie Leichtketten-Ratio befand sich trotz Auslenkung der freien Lambda-Immunglobulin-Leichtketten im Normbereich. Die Endomyokardbiopsie offenbarte eine fortgeschrittene Infiltration mit Lambda-Immunglobulin-Leichtketten. Eine klinisch relevante extrakardiale Amyloid-Organinfiltration konnte nicht nachgewiesen werden. Daraus folgt, dass in seltenen Fällen nicht-invasive Untersuchungen eine isolierte Kardiomyopathie im Rahmen einer Leichtketten-Amyloidose nicht ausschließen können und bei bestehendem Verdacht auf eine kardiale Amyloidose sowie diskrepanten Ergebnissen in nicht-invasiven Untersuchungen selbst diskrete Erhöhungen der freien Lambda- oder Kappa-Immunglobulin-Leichtketten im Serum als abnormal angesehen werden sollten.

Abstract

Amyloid light chain (AL) cardiomyopathy is the most malignant specific cardiomyopathy. According to international recommendations, it should be ruled out non-invasively using the serum free light chain (FLC) ratio and immunofixation electrophoresis in both serum and urine. This case report covers a 69-year-old female patient with new-onset heart failure with mid-range ejection fraction. Cardiac imaging was highly suggestive of cardiac amyloidosis. Amyloid scintigraphy showed faint myocardial tracer uptake according to Perugini Score 1, but immunofixation was negative and the FLC ratio was normal, despite a slight increase in lambda FLCs. Endomyocardial biopsy revealed advanced myocardial lambda immunoglobulin light chain deposition. Clinically relevant extracardiac amyloid organ infiltration could not be detected. Conclusively, non-invasive testing can fail to exclude isolated AL cardiomyopathy in rare cases. Therefore, even slight increases in serum lambda or kappa FLCs should be considered abnormal in suspected cardiac amyloidosis if non-invasive testing delivers discrepant results.

Information on publications already made

With the consent of the patient concerned as well as physicians involved in the diagnosis and treatment, this work was successfully submitted to ESC Heart failure, a peer-reviewed open access journal of the European Society of Cardiology, where it was accepted for publication on April 12th 2021, first published online on May 7th 2021 and finally published in Volume 8 Issue 4 in August 2021, with me listed as lead author (1).

Since the patient was eventually diagnosed with AL Amyloidosis and as cardiac amyloidoses are Hypertrophic Cardiomyopathy (HCM) phenocopies (2), I encountered her while working as a research assistant at the Division of Cardiology, Department of Internal Medicine, Medical University of Graz, where I was involved in developing standard operating procedures, analysing echocardiographies and enrolling patients in the HCM Registry. In this context, I had already familiarised myself with literature on diagnostics and differential diagnoses of HCM and its phenocopies. Due to observations described in the case report, I was struck by this patient's particular route to diagnosis. After receiving the patient's informed consent, I obtained her complete clinical records from physicians and organisations involved in the interdisciplinary diagnostic work-up and treatment. I then assembled all the pieces of information and wrote the following case report.

Introduction

AL cardiomyopathy affects more than 50% of patients with systemic AL amyloidosis and carries a dismal prognosis if untreated (3,4). Isolated cardiac manifestation is present if no other target organ shows clinically relevant involvement. With the advent of effective treatment options for both AL and transthyretin (TTR) amyloidosis, awareness regarding the entity of cardiac amyloidoses rises (5,6). As a consequence, cardiologists are increasingly confronted with patients with suspected cardiac amyloidosis and should be aware of potential pitfalls in the diagnostic work-up. Rule out of AL amyloidosis is of high importance, because only early treatment improves outcomes. While its diagnosis requires histopathological confirmation, current recommendations suggest excluding AL amyloidosis using serum FLC ratio assessment and immunofixation electrophoresis of both serum and urine to detect monoclonal proteins (7,8). However, the present case demonstrates that isolated AL cardiomyopathy can occur without significant increase in circulating amyloidogenic FLCs and can therefore be missed by non-invasive testing.

Case Report

A 69-year-old female patient was referred for congestive heart failure with progressive exertional dyspnoea according to New York Heart Association (NYHA) Class III and angina pectoris according to Canadian Cardiac Society Class I during the last months. She presented with congested jugular veins, a third heart sound, and mild leg oedema. Cardiovascular risk factors comprised smoking (50 pack years) and arterial hypertension with an office blood pressure of 135/86 mmHg. Levels of both N-terminal pro brain natriuretic peptide (NT-proBNP) and high-sensitivity cardiac troponin T were elevated (1199 and 26 pg/mL, respectively), while serum creatinine was normal (0.78 mg/dL) and estimated glomerular filtration rate (eGFR) was only slightly impaired with 78 mL/min/1.73 m² (normal >90 mL/min/1.73 m²). Transthoracic echocardiography showed a left ventricular mid-range ejection fraction of 47% and typical features of infiltrative cardiomyopathy (*Figure 1*), and cardiac magnetic resonance imaging was strongly suggestive of cardiac amyloidosis (*Figure 2*).

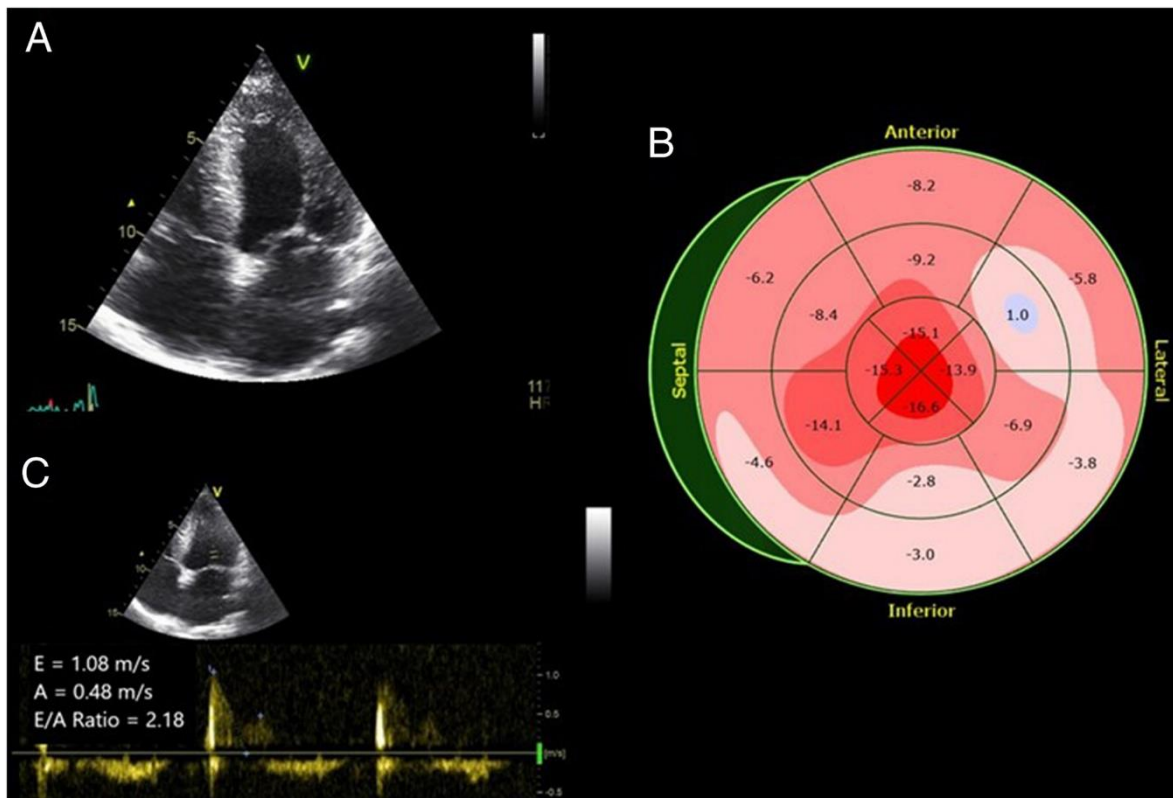


Figure 1

Transthoracic echocardiography showed a left ventricular ejection fraction of 47% and (A) pronounced concentric biventricular hypertrophy; (B) left ventricular global longitudinal strain of 9.1% with significant relative apical sparing; and (C) a restrictive transmitral filling pattern with an E/A ratio of 2.18 (as published in (1)).

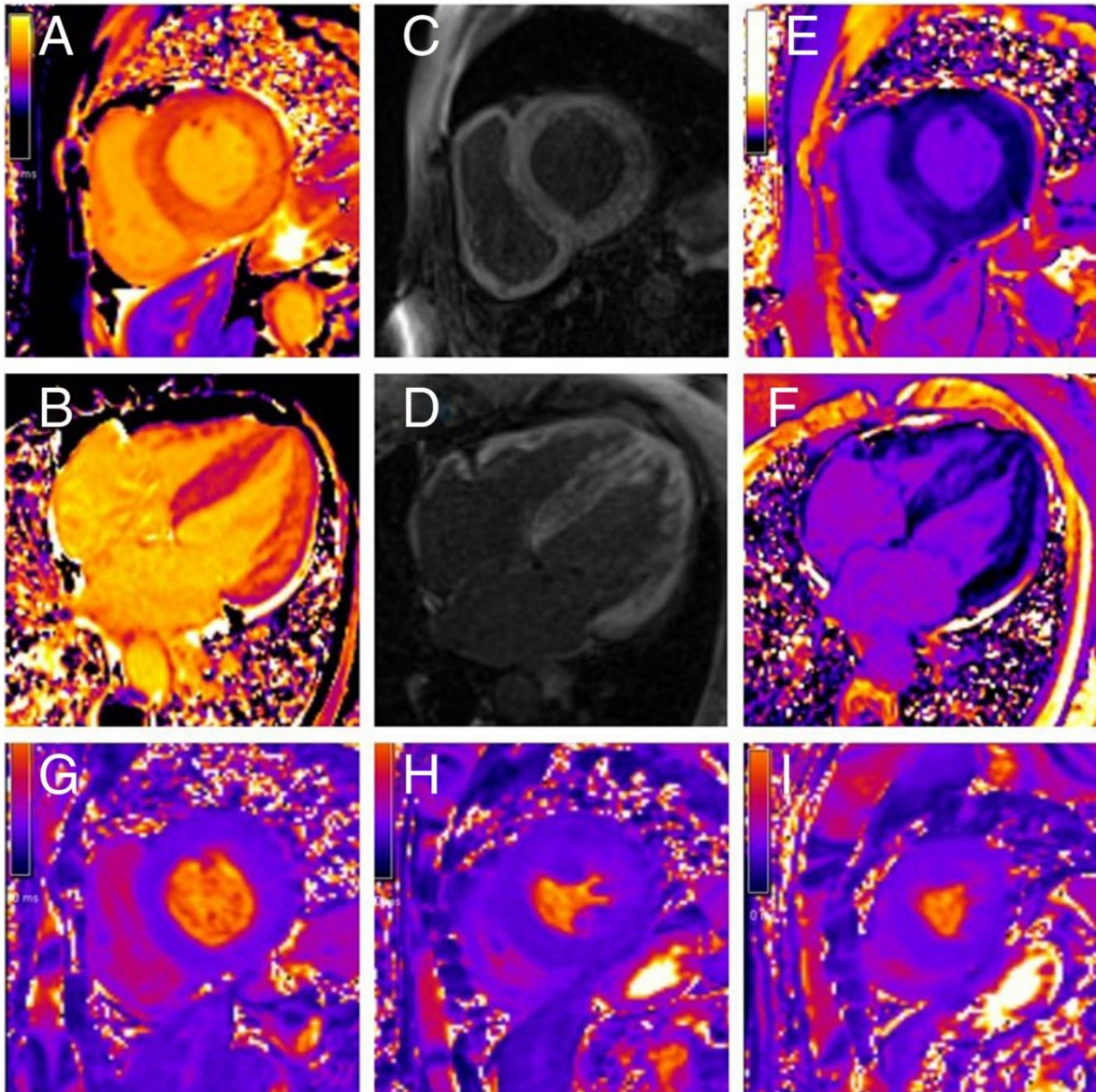


Figure 2

Cardiac magnetic resonance imaging. (A,B) Native myocardial T1 and extracellular volume mapping revealed increased values for both parameters (1411 ± 83 ms, z-score = 7; and $69 \pm 7\%$, z-score = 15, respectively); (C,D) left ventricular (LV) mid and apical segments portrayed subendocardial late gadolinium enhancement, while the basal segments showed a transmural pattern. In the right ventricle, global late gadolinium enhancement was present; (E,F) Post-contrast T1 maps confirmed transmural accumulation of the contrast agent at basal LV and right ventricular myocardial segments, as well as global subendocardial accumulation of the contrast agent at mid-ventricular to apical LV and right ventricular myocardial segments; (G-I) global LV myocardial T2 times were within the normal range excluding myocardial oedema (as published in (1)).

Following the non-invasive diagnostic algorithm suggested by Gillmore et al. (9), amyloid scintigraphy was performed and monoclonal paraproteins were searched for. ^{99m}Tc -DPD bone scintigraphy revealed a faint myocardial radiotracer uptake according to Perugini Score 1. Despite slightly increased levels of serum lambda FLCs (30.20 mg/L, upper normal range 26.3 mg/L) in concomitance with normal kappa FLCs (16.5 mg/L, upper

normal range 19.4 mg/L), the serum FLC kappa to lambda ratio was not altered (0.55, normal range 0.26-1.65). Neither serum nor urine immunofixation electrophoresis was positive for monoclonal paraproteins. These results were confirmed in a repeated assessment.

Given the inconclusive constellation after non-invasive diagnostic work-up, an endomyocardial biopsy (EMB) was performed. Histopathological analysis of Congo-red stained biopsy specimens revealed myocardial amyloid infiltration on 40% of the cutting surface (*Figure 3*). Unexpectedly, immunohistochemical characterization of amyloid depositions identified lambda immunoglobulin light chains. Bone marrow aspiration unveiled a normocellular bone marrow without evidence of an underlying multiple myeloma. Furthermore, diagnostic work-up included karyotyping as well as fluorescent *in situ* hybridization analysis of the bone marrow aspirate. Cytogenetics displayed a normal karyotype, and despite magnetic-activated cell sorting-based enrichment for plasma cells, fluorescent *in situ* hybridization analysis did not reveal chromosomal changes recurrently found in multiple myeloma. Minimal residual disease measurements were not performed. Subsequent assessment revealed the presence of clinically non-relevant perivascular amyloid depositions in the bone marrow. Amyloid was not detectable in abdominal fat pad aspiration.

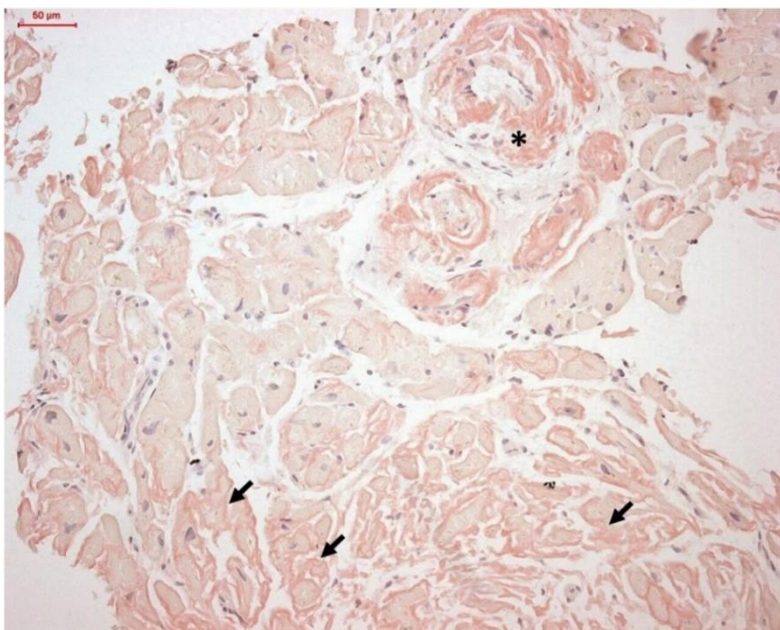


Figure 3
Histopathological analysis of Congo-red stained endomyocardial biopsy specimen demonstrating perivascular () and interstitial (→) myocardial amyloid depositions (Congo-red stain, ×200) (as published in (1)).*

Systemic AL amyloidosis with isolated amyloid cardiomyopathy Stage II was confirmed. Interdisciplinary disease management included symptomatic heart failure treatment and chemotherapy with eight cycles of bortezomib/dexamethasone followed by 4 cycles of melphalan/dexamethasone. Heart transplant followed by autologous stem cell therapy was considered a possible treatment option, but was declined by the patient. Two years after the initial diagnosis, she has remained in a clinically stable condition, with exertional dyspnoea according to NYHA Class II, NT-proBNP levels of 1408 pg/mL, and normalized levels of serum lambda FLCs of 11.4 mg/L.

Discussion

The present case illustrates that immunofixation electrophoresis and FLC ratio assessment according to international recommendations can fail to detect AL amyloidosis complicated by isolated AL cardiomyopathy. Normal or borderline concentrations of FLCs resulting in a normal FLC ratio have also been reported by others, suggesting that this phenomenon may affect a relevant proportion of patients with isolated AL cardiomyopathy (10).

Together, these cases cast doubt on whether the current definition of normal FLCs yields sufficient sensitivity to detect isolated AL cardiomyopathy (8). Moreover, it emphasizes that EMB should be performed in any patient with a high likelihood of cardiac amyloidosis in whom a plasma cell clone cannot be definitely excluded.

AL cardiomyopathy carries the worst prognosis within the spectrum of specific cardiomyopathies (3). In the vast majority of amyloid cardiomyopathies, the underlying cause is either TTR or AL amyloid fibril deposition (11). Both AL and TTR amyloid infiltration can be associated with scintigraphic myocardial tracer uptake. In fact, 20% of patients with AL cardiomyopathy had a Perugini Score ≥ 2 in the landmark study by Gillmore et al. (9). Vice versa, 6% of patients with TTR amyloid cardiomyopathy presented with Perugini Score < 2 (9). International recommendations therefore suggest that EMB can be avoided if non-invasive amyloid subtyping is specific of TTR amyloidosis. Amyloid scintigraphy with Perugini score ≥ 2 is considered diagnostic of TTR amyloidosis if AL can be excluded (7,8). Determination of serum FLC ratio in addition to immunofixation electrophoresis of both serum and urine is considered to have at least 99% sensitivity for monoclonal gammopathy and is therefore recommended as the gold-standard method to exclude AL amyloidosis (12,13). Consequently, international recommendations rate the presence of AL amyloidosis as very unlikely if the FLC ratio is normal and amyloid scintigraphy results are either normal or indeterminate (8). However, this case demonstrates that isolated AL cardiomyopathy can be present even if the assessment of the FLC ratio is unremarkable and serum as well as urine immunofixation are negative.

It is important to note that this patient presented with slightly increased free lambda immunoglobulin light chains in the presence of mild chronic kidney disease (eGFR of 78 mL/min/1.73 m²), although this did not lead to a significant alteration of the FLC ratio.

Increases in both kappa and lambda FLC concentrations can occur in the presence of impaired kidney function. However, significant increases in FLC concentrations, particularly affecting kappa FLCs, and alterations of the FLC ratio are almost exclusively evident in patients with an eGFR <55 mL/min/1.73 m², for whom adjustments to the normal reference ranges for FLCs and the FLC ratio have been suggested (14). Apart from minimal perivascular amyloid infiltration in bone marrow specimen, there was no evidence of clinically relevant extra-cardiac infiltration, allowing for the diagnosis of isolated AL cardiomyopathy. This imbalance between undetectable systemic monoclonal light chain burden and severe myocardial infiltration could potentially be explained by selective cardiac tropism of monoclonal lambda light chains expressed in this patient. Cardiac tropism is considered as the crucial mechanism leading to selective myocardial infiltration in AL amyloidosis. It is well accepted that certain monoclonal amyloidogenic light chains are more cardio-selective and cardio-toxic than others (15). However, underlying mechanisms remain elusive in large parts. Other factors that both increased the likelihood of AL amyloidosis and made ATTR amyloidosis unlikely were the rapid progression of heart failure symptoms within months and the female gender.

The present case report underlines that non-invasive methods of amyloid subtyping, i.e. amyloid scintigraphy and FLC assessment, should be interpreted in the context of an individual patient's likelihood to have cardiac amyloidosis. Additionally, the clinical course and the patient's gender should be taken into account. In fact, the diagnostic accuracy of these methods has been validated in a cohort of patients with suspected cardiac amyloidosis (9). In experienced hands, echocardiographic assessment of myocardial thickening, diastolic function and filling pressures, and global longitudinal strain pattern remains at the forefront to raise suspicion of cardiac storage disease (16). In addition, cardiac magnetic resonance imaging provides excellent diagnostic accuracy for the diagnosis of cardiac amyloidosis, particularly if T1 mapping and quantification of myocardial extracellular volume are applied (17). This case reaffirms, as suggested by Gillmore et al. (9), that patients with suspected cardiac amyloidosis and Perugini Score of 1 should undergo EMB irrespective of results of the FLC assessment. In experienced hands, EMB is a relatively safe procedure leading to life-threatening complications in less than 1% of performed procedures (18). Given the substantial consequences of misdiagnosed AL cardiomyopathy for individual patients, actions to increase the sensitivity of FLC assessment are warranted. Therefore, the definition of abnormal FLCs in

patients with suspected cardiac amyloidosis and discrepant non-invasive testing should be extended by evidence of unexplainable elevation of either lambda or kappa FLCs, even if the FLC ratio is normal and a monoclonal band cannot be detected using immunofixation electrophoresis.

Conclusion

In rare cases, patients with isolated AL cardiomyopathy can present with false negative FLC assessment if its current definition is applied. Cardiologists should be aware that isolated AL cardiomyopathy cannot be excluded with absolute certainty using non-invasive testing. In patients with suspected cardiac amyloidosis and discrepant results following non-invasive testing, the definition of abnormal FLC assessment should be extended so that an unexplained increase in serum FLCs should be considered abnormal, even if the FLC ratio is normal and a monoclonal band cannot be objectified using immunofixation electrophoresis. Patients with a high likelihood of cardiac amyloidosis should undergo EMB if non-invasive amyloid subtyping is not specific of TTR amyloidosis.

List of References

- 1) Zach D, Ablasser K, Kolesnik E, Hoeller V, Fruhwald F, Prüller F, et al. Advanced isolated light chain amyloid cardiomyopathy with negative immunofixation and normal free light chain ratio. *ESC Heart Fail.* 2021 Aug;8(4):3397-402
- 2) Ommen SR, Mital S, Burke MA, Day SM, Deswal A, Elliott P, et al. 2020 AHA/ACC Guideline for the Diagnosis and Treatment of Patients With Hypertrophic Cardiomyopathy: Executive Summary: A Report of the American College of Cardiology/American Heart Association Joint Committee on Clinical Practice Guidelines. *Circulation.* 2020 Dec 22;142(25):e533-e557.
- 3) Kocher F, Kaser A, Escher F, Doerler J, Zaruba MM, Messner M, et al. Heart failure from ATTRwt amyloid cardiomyopathy is associated with poor prognosis. *ESC Heart Fail.* 2020 Oct 1;7(6):3919-28.
- 4) Falk RH. Cardiac amyloidosis: a treatable disease, often overlooked. *Circulation.* 2011 Aug 30;124(9):1079-85.
- 5) Maurer MS, Schwartz JH, Gundapaneni B, Elliott PM, Merlini G, Waddington-Cruz M, et al. Tafamidis Treatment for Patients with Transthyretin Amyloid Cardiomyopathy. *N Engl J Med.* 2018 Sep 13;379(11):1007-16.
- 6) Roussel M, Merlini G, Chevret S, Arnulf B, Stoppa AM, Perrot A, et al. A prospective phase 2 trial of daratumumab in patients with previously treated systemic light-chain amyloidosis. *Blood.* 2020 Apr 30;135(18):1531-40.
- 7) Gertz MA. Immunoglobulin light chain amyloidosis: 2020 update on diagnosis, prognosis, and treatment. *Am J Hematol.* 2020 Jul;95(7):848-60.
- 8) Maurer MS, Bokhari S, Damy T, Dorbala S, Drachman BM, Fontana M, et al. Expert Consensus Recommendations for the Suspicion and Diagnosis of Transthyretin Cardiac Amyloidosis. *Circ Heart Fail.* 2019 Sep;12(9):e006075.
- 9) Gillmore JD, Maurer MS, Falk RH, Merlini G, Damy T, Dispenzieri A, et al. Nonbiopsy Diagnosis of Cardiac Transthyretin Amyloidosis. *Circulation.* 2016 Jun 14;133(24):2404-12.
- 10) Milani P, Valentini V, Ferraro G, Basset M, Russo F, Foli A, et al. A patient with AL amyloidosis with negative free light chain results. *Clin Chem Lab Med.* 2016 Jun 1;54(6):1035-7.

- 11) Ablasser K, Verheyen N, Glantschnig T, Agnetti G, Rainer PP. Unfolding Cardiac Amyloidosis -From Pathophysiology to Cure. *Curr Med Chem*. 2019;26(16):2865-78.
- 12) Palladini G, Russo P, Bosoni T, Verga L, Sarais G, Lavatelli F, et al. Identification of amyloidogenic light chains requires the combination of serum-free light chain assay with immunofixation of serum and urine. *Clin Chem*. 2009 Mar;55(3):499-504.
- 13) Hanna M, Ruberg FL, Maurer MS, Dispenzieri A, Dorbala S, Falk RH, et al. Cardiac Scintigraphy With Technetium-99m-Labeled Bone-Seeking Tracers for Suspected Amyloidosis: JACC Review Topic of the Week. *J Am Coll Cardiol*. 2020 Jun 9;75(22):2851-62.
- 14) Molina-Andújar A, Robles P, Cibeira MT, Montagud-Marrahi E, Guillen E, Xipell M, et al. The renal range of the κ/λ sFLC ratio: best strategy to evaluate multiple myeloma in patients with chronic kidney disease. *BMC Nephrol*. 2020 Mar 31;21(1):111.
- 15) Merlini G, Palladini G. Light chain amyloidosis: the heart of the problem. *Haematologica*. 2013 Oct;98(10):1492-5.
- 16) Pagourelas ED, Mirea O, Duchenne J, Van Cleemput J, Delforge M, Bogaert J, et al. Echo Parameters for Differential Diagnosis in Cardiac Amyloidosis: A Head-to-Head Comparison of Deformation and Nondeformation Parameters. *Circ Cardiovasc Imaging*. 2017 Mar;10(3):e005588.
- 17) Zhao L, Tian Z, Fang Q. Diagnostic accuracy of cardiovascular magnetic resonance for patients with suspected cardiac amyloidosis: a systematic review and meta-analysis. *BMC Cardiovasc Disord*. 2016 Jun 7;16:129.
- 18) From AM, Maleszewski JJ, Rihal CS. Current status of endomyocardial biopsy. *Mayo Clin Proc*. 2011 Nov;86(11):1095-102.