

Thesis

Flow asymmetry

A quantitative and objective measure of unilateral facial palsy

Eingereicht von

Keyue Sun

zur Erlangung des akademischen Grades

Doktorin der gesamten Heilkunde

(Dr. med. univ.)

an der

Medizinischen Universität Graz

ausgeführt an der

Abteilung für Plastische, Ästhetische und Rekonstruktive Chirurgie/ LKH Graz

unter der Anleitung von

Univ.Prof.Dr. Stephan Spendel, Univ.Prof.Dr.Dr. Kurt Schicho

Graz, Februar 2018

Eidesstattliche Erklärung

Ich erkläre ehrenwörtlich, dass ich die vorliegende Arbeit selbstständig und ohne fremde Hilfe verfasst habe, andere als die angegebenen Quellen nicht verwendet habe und die den benutzten Quellen wörtlich oder inhaltlich entnommenen Stellen als solche kenntlich gemacht habe.

Graz, am 02. Februar 2018

Keyue Sun eh.

Danksagung

An dieser Stelle möchte ich mich bei all denjenigen bedanken, die mich während der Anfertigung dieser Diplomarbeit unterstützt und motiviert haben.

Zuerst gebührt mein Dank Prof. Stefan Spendel und Prof. Kurt Schicho, die meine Diplomarbeit betreut und begutachtet haben. Für die hilfreichen Anregungen und die konstruktive Kritik bei der Erstellung dieser Arbeit möchte ich mich herzlich bedanken.

Ebenfalls möchte ich mich herzlichst bei Prof. Thomas Pock von der TU Graz für die Möglichkeit des interdisziplinären Gedankenaustausches bedanken.

Einen besonderen Dank möchte ich meinem Vater Lidong Sun und Doktorand Gottfried Munda von der TU Graz aussprechen, die mir mit viel Geduld, Interesse und Hilfsbereitschaft zur Seite standen. Bedanken möchte ich mich für die zahlreichen interessanten Debatten und Ideen, die maßgeblich dazu beigetragen haben, dass diese Diplomarbeit in dieser Form vorliegt.

Meinen Freunden danke ich besonders für den starken emotionalen Rückhalt über die Dauer meines gesamten Studiums.

Abschließend möchte ich mich bei meinen Eltern Lidong Sun und Jie Zeng und meiner Schwester Kehui Sun bedanken, die mir mein Studium durch ihre Unterstützung ermöglicht haben und stets ein offenes Ohr für meine Sorgen hatten.

Zusammenfassung

Hintergrund

Der Nervus Fazialis ist der siebte Hirnnerv und ist häufig von Läsionen betroffen. Die daraus resultierende Fazialisparese führt u. a. zu Ausfällen der mimischen Muskeln, was zu verminderter Lebensqualität der betroffenen Patienten und Patientinnen führt. Die Behandlung der Fazialisparese ist nach wie vor eine Herausforderung, die oft einen interdisziplinären Einsatz erfordert (z. B. zwischen HNO und Plastischer Chirurgie). Ein einheitliches, objektives und quantitatives Evaluierungssystem für die Fazialisparese ist derzeit noch nicht etabliert. Die Zielsetzung der vorgelegten Arbeit ist es eine neue innovative Methode, welche die objektive und quantitative Evaluierung ermöglicht, vorzustellen.

Methodik

Die Verlaufskontrolle und die Diagnostik beruhen auf der Asymmetrie des Gesichtes. Um die Asymmetrie in den dynamischen Bewegungen der mimischen Muskulatur zu messen, werden die Veränderungen der Abfolge der Bilder von der Bewegungsaufnahme verfolgt. Jedes Bild besteht aus vielen Punkten und die Verschiebung der Punkte in der Abfolge der Bilder stellt die Bewegungsmuster der Gesichtsmuskulatur dar. Mit der Optischen Fluss-Methode werden diese Verschiebungen der Punkte als Vektoren dargestellt. Somit können das Potential der Gesichtsmuskulatur, die Richtung und die Geschwindigkeit der Bewegung mathematisch abgeleitet und beschrieben werden. In diesem Zusammenhang werden die nötigen Parameter erarbeitet und daraus letztlich ein Maß "flow asymmetry", welches die Asymmetrie der Bewegung beschreibt, zum ersten Mal definiert.

Ergebnisse

Die Eignung der Zielsetzung der neuen Methodik lässt sich von den durchgeführten mathematischen Simulationen bestätigen. Aktionen der Gesichtsmuskeln lassen sich mit dieser Methode gut darstellen und die Asymmetrie der dynamischen Bewegungen kann objektiv und quantitativ durch das Maß "*flow asymmetry*" beschrieben werden.

Zusammenfassung

Das Konzept, das vorgestellt wurde zeigt, dass der optische Fluss für die Messung der Asymmetrie der Bewegungen der Gesichtsmuskeln geeignet ist. Damit kann der Verlauf der Fazialisparese quantitativ dargestellt werden. Die Ergebnisse der Simulationen bestätigten, dass das hier vorgestellte Maß "*flow asymmetry*" ein präzises, objektives und quantitatives Maß für die Evaluierung von Fazialisparese ist.

Abstract

Background

The seventh cranial nerve (CNVII), also known as facial nerve is one of the most commonly paralyzed nerves. Inhibiting facial expression, facial nerve palsy leads to a devastating condition for the patient. Regarding to the challenging management of facial palsy, an interdisciplinary cooperation (e.g. between ENT and plastic surgery) is often necessary.

A valid quantitative and objective grading system, which can provide straightforward communication between and among clinicians, has not been established yet. The aim of this thesis is to introduce a new concept of an objective and quantitative grading method.

Method

The follow-up and diagnose of the facial palsy patients are determined by the asymmetry of the face. To measure the asymmetry of the dynamic movement of the facial expression muscles, the transformation of the motion from one frame in a sequence into the next frame of the recorded movement would be observed. Each frame is made of a given set of points and the transformation of these points describes the facial movement pattern. The transformations can be shown in form of vectors by using the optical flow method. In this way, the direction, the speed of the movement, and the potential of the facial muscles can be described and be derived from the mathematical concept. Subsequently the essential parameter and the measure *flow asymmetry* can be determined. *Flow asymmetry* is here introduced for the first time as a quantitative measure of the facial palsy.

Results

The feasibility of the new evaluation method has been proved by mathematic simulations. The asymmetry of the facial movement is described by *flow asymmetry*, which can be used as a measure for the quantitative evaluation of the facial palsy. The motion and the asymmetry of the facial movement can be illustrated precisely with this proposed concept.

Conclusions

This proposed idea has demonstrated that the optical flow is a powerful method for measuring the dynamics of the facial muscles. Our simulation results confirmed that the newly introduced concept, i.e., *flow asymmetry*, is a precise quantitative measure of unilateral facial palsy.

Contents

Danksagung	iii
Zusammenfassung	iv
Abstract	v
Contents	vi
Index of Figures	ix
Index of Tables	x
1 Introduction	11
1.1 Anatomy	12
1.1.1 The course of the facial nerve	12
1.1.2 Muscles of the facial expressions	13
1.1.3 Functions of the facial nerve	17
1.2 Etiology and pathophysiology	17
1.2.1 Central facial palsy	17
1.2.2 Peripheral facial palsy	19
1.3 Clinic	21
1.3.1 Diagnosis	22
1.3.2 Congenital facial palsy	22
1.3.3 Acquired Facial Nerve Palsy	23
1.3.4 Idiopathic	24
1.3.5 Neoplasm	25
1.4 Management of paralyzed face by zone	26
1.4.1 Non-surgical treatment	26
1.4.2 Surgical treatment	26
1.5 Assessments and Grading instruments for the facial nerve	33
2 Method	35
3 Results	40
3.1 Simulated Performance-Curves	42
3.2 Simulated illustration of Correlation between the mean total flow and the flow asymmetry	43
4 Discussion	44
5 Conclusion	45
6 References	47

Index of Figures

Figure 1: First layer of muscles of facial expression; (47) 14

Figure 2 : Second layer of muscles of facial expression; (47) 14

Figure 3: Third layer of muscle of facial expression; (47)..... 15

Figure 4: Forth layer of muscles of facial expression; (47)..... 15

Figure 5: Peripheral facial palsy vs. central facial palsy;(13)..... 18

Figure 6: The steps of the proposed experiment procedure..... 37

Figure 7: Middleburycolor Code explanation..... 39

Figure 8: Simulated Performance-Curve of a non-facial palsy face..... 42

Figure 9: Simulated Performance-Curve of a facial palsy on the right side of the face..... 42

Figure 11: Simulated bar of the mean total flow with the flow asymmetry (D) of the performance
in Figure 9 43

Figure 10: Simulated bar of the mean total flow with the flow asymmetry (D) of the performance
in Figure 8 43

Index of Tables

Table 1: Sensory and motor function of cranial nerve VII (7) 13

Table 2: Muscles of facial expression with their innervations and functions(8)..... 16

Table 3: Intracranial(8) 19

Table 4: Within the temporal bone (intratemporal) (8)..... 20

Table 5: Distal to the temporal bone (extratemporal) (8)..... 20

Table 6: Possible borders of mask of interest 38

Table 7: Overview of correlations 41

1 Introduction

As a cranial nerve with a complex and broad range of functions, the facial nerve (CNVII) is one of the most commonly paralyzed nerves. Paralysis of any structure, which is innervated by the CNVII, can be described as facial palsy. Due to the facial expression inhibition, facial palsy deprives the ability of patients to communicate and express their emotions, which leads to a devastating condition for the patient. Consequently, they lose voluntary action of their muscle for the facial expression and thereby have the facial laxity and mask-like expression, especially in bilateral cases. In addition to the aesthetic deformity and troublesome psychosocial effects on their daily life, there are functional problems. Articulation deficits, paralytic lagophthalmos with subsequent exposure keratopathy, eyelid retraction, ectropion and collapsed nasal valve collapse can be observed at the facial palsy patients. (1,2)

A wide variety of causes and underlying conditions give facial palsy an inherent complexity. (3) Because of these complexities, the management of facial palsy is important. Therefore, a functional grading scale would provide straightforward communication between the clinicians and will help the clinicians to find an adequate management for each patient with facial palsy. There are already internationally accepted facial nerve grading scales include the House-Brackmann scale and the Sunnybrook scale.(4) Without going into details, there are also few objective computing methods. Related to this thesis, optical-flow-based methods have been already proposed in some papers to grade facial palsy. (5,6) Albeit, a universally accepted, widely used, objective and quantitative facial function assessment has not been developed yet.(3)

This thesis proposes the ability of optical flow providing a reliable and objective measurement of facial function and of the facial expression asymmetry. The method can also be used as a follow-up evaluation of facial palsy patients after treatments and can help to create a standard guideline for the future in treatment of facial palsy.

The introduction in this paper will provide information about the anatomy of the facial nerve. Further, it will give an overview of the wide variety of the etiology and pathophysiology of facial palsy. These are fundamental for the understanding of this complex condition. Different options of treatment and clinical assessments will also be discussed. The aim of this thesis is to demonstrate the new concept of the variable *flow asymmetry*, but also the correlation between the mean total flow and the potential of the

facial muscle. This proposal could be important and powerful for development of an objective and quantitative facial nerve assessment.

1.1 Anatomy

1.1.1 The course of the cranial nerve VII (7–10)

The facial nerve or the cranial nerve VII has two divisions. Motor division (Table 1) is one of the divisions and innervates facial muscles, which are responsible for the mimic. The nucleus of the facial nerve is the origin of the motor fibers and define an arc about the nuclei of abducent nerve (genu internal n. facialis) and exit at the pontomedullary junction. The course of motor fibers and the sensory fibers goes separately until they enter the internal acoustic canal as the facial nerve.

The other one is sensory division (Table 1), also referred as the nervus intermedius. The gustatory fibers emerge from the geniculate ganglion at the meeting point of the labyrinthine and tympanic segments of the facial canal.

Parasympathetic secretomotor fibers on the other hand arise within the pons, but they originate from the superior salivatory nucleus.

Gustatory fibers and parasympathetic secretomotor fibers of CNVII do not arc around the nuclei of abducent nerve but join the ascending limb of the nerve and arises as nervus intermedius. It exits at the cerebellopontine between the vestibulocochlear and nerve the CNVII.

The intratemporal course of CNVII can be divided into three parts: labyrinthine (proximal), tympanic and mastoid (distal). Motor and sensory divisions pass the inner auditory canal, the meatus auditorium and enter the facial canal in form of a common trunk. This trunk gives off some branches off into the facial canal before it goes through the stylomastoideus foramen and exits the skull. This facial canal is also the longest bony course for any cranial nerve and continues above the tympanic cavity and turns caudally where it exists the skull. Aforementioned branches are the greater petrosal nerve, the stapedius nerve, and the chorda tympani.

The geniculate ganglion lies at the genu of the facial nerve in the petrous bone.

In the extratemporal course, CNVII gives off the posterior auricular nerve, the stylohyoid branch, and the digastrics branch before entering the parotid gland. It ramifies into parotid plexus and lies between the superficial parotid gland lobe and deep lobes. Parotid plexus separates into the temporal branches, the zygomatic branches, the

marginal mandibular branch, and the cervical branch. They provide innervation to all muscles of the facial expressions (Table 2).

There are three commonly used anatomic landmarks to find the main trunk of the facial nerve after it exits the skull. The tragal pointer is located 1cm inferior and 1cm deep to the tragal cartilage. The other landmark is located 6 to 8mm medial to the end of the tympano-mastoid suture. The facial nerve runs in the same depth like the posterior belly of the digastrics muscle and is found halfway between this muscle and the styloid process. In children, these landmarks can be disordered. They are important for surgical treatments and interventions of facial palsy and will be referred to another chapter of this thesis.

Table 1: Sensory and motor function of cranial nerve VII (7)

Sensory	Motor
External ear (via nervus intermedius)	Muscles of facial expression
Taste fibers on anterior two-thirds of tongue (via chorda tympani)	Posterior belly of digastricus muscle
Oropharynx (below palatine tonsil)	Stylohyoid muscle Stapedius muscle (middle ear) Lacrimal secretion (via pterygopalatine ganglion) Salivary secretion (via chorda tympani)

1.1.2 Muscles of the facial expressions

They are divided into four layers and their movements are determining on examination. Patients usually are asked to raise their eyebrows (frontalis), close eyelids (orbicularis oculi), smile (zygomaticus major and minor) and purse lips (orbicularis oris).(8) Following *Figures 1-4* are showing the four layers of the muscles for the facial expressions and *Table 2* provides an overview of the innervations and function of the muscles.

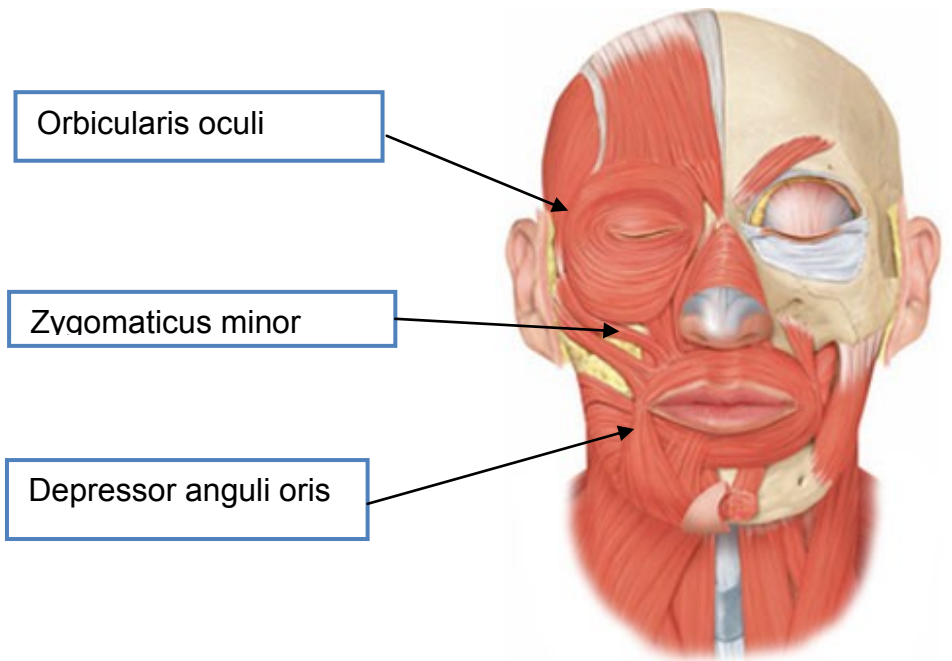


Figure 1: First layer of muscles of facial expression; (47)

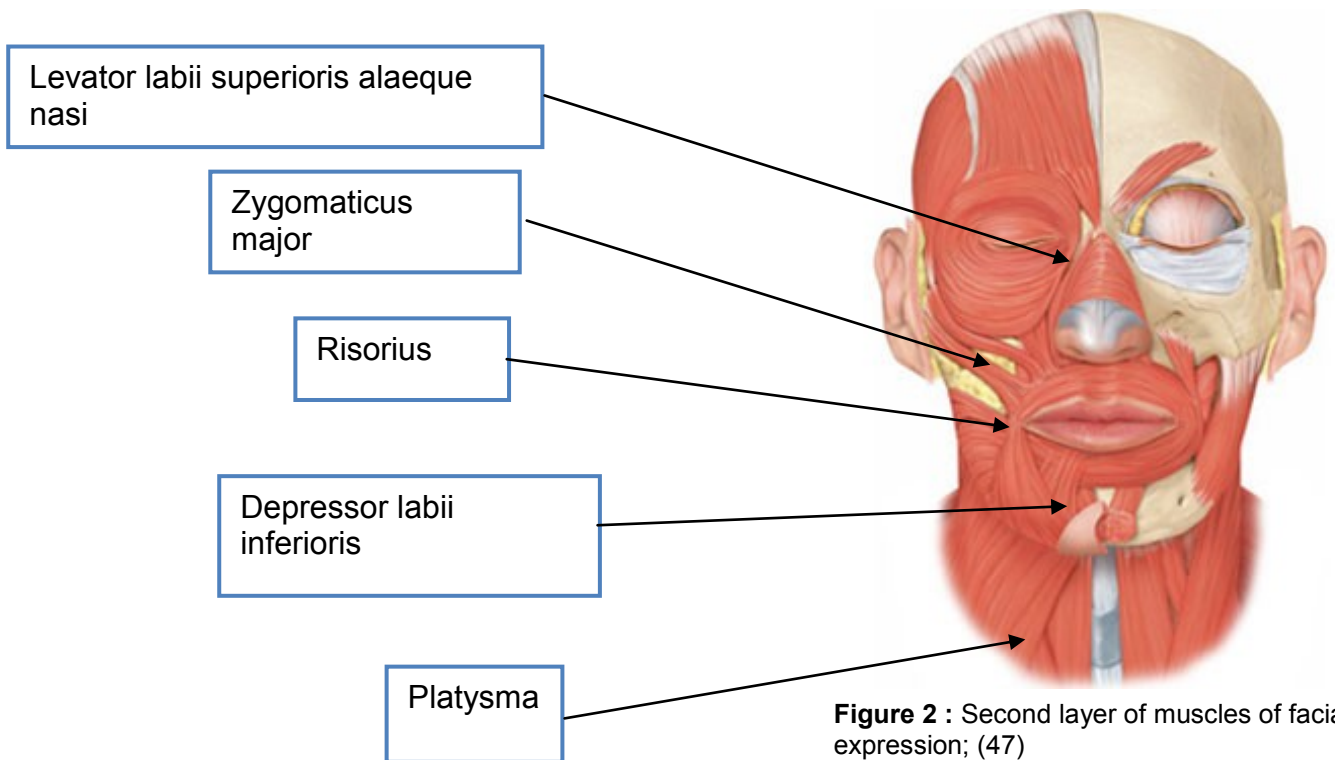


Figure 2 : Second layer of muscles of facial expression; (47)

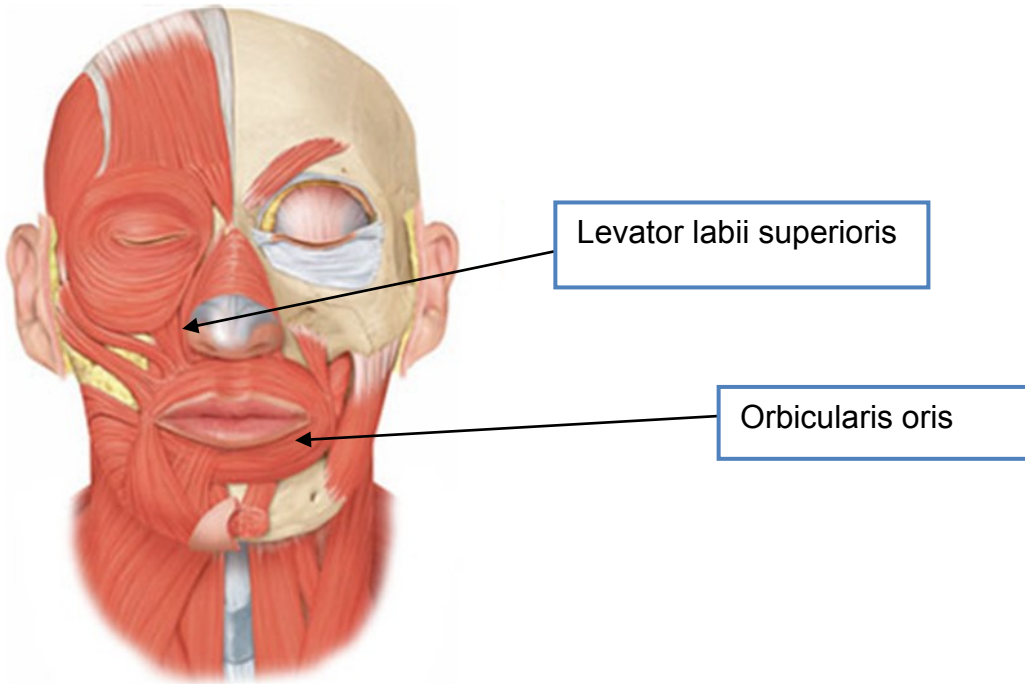


Figure 3: Third layer of muscle of facial expression; (47)

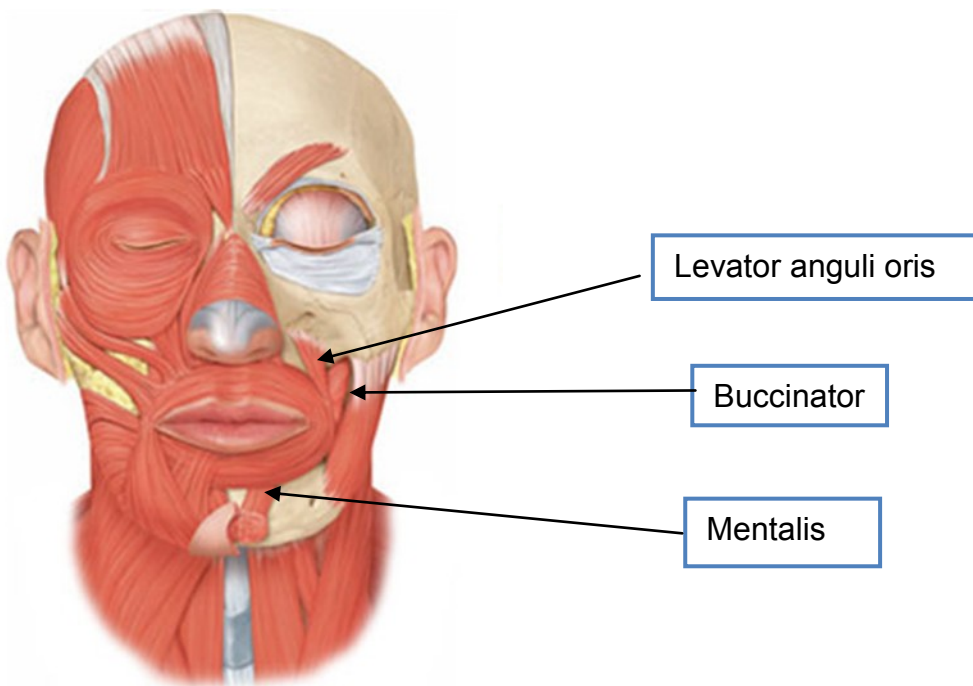


Figure 4: Forth layer of muscles of facial expression; (47)

Table 2: Muscles of facial expression with their innervations and functions(8)		
Branch	Muscle	Function
Temporal	<ul style="list-style-type: none"> • Corrugators supercilii • Frontalis • Procerus 	<p>Brow depression and medialization</p> <p>Brow elevation</p> <p>Brow depression</p>
Temporal/ zygomatic	<ul style="list-style-type: none"> • Orbicularis oculi 	Eyelid closure
Zygomatic/ buccal	<ul style="list-style-type: none"> • Zygomaticus major 	Oral commissure elevation and lateralization (primary smile actuator)
Buccal	<ul style="list-style-type: none"> • Buccinator • Depressor septi nasi • Levator labii superioris • Levator labii superioris aleque nasi • Levator anguli oris nasalis • Orbicularis oris risorius • Zygomaticus minor 	<p>Cheek compression</p> <p>Nasal tip depression</p> <p>Upper lip elevation</p> <p>Upper lip elevation and nostril dilation</p> <p>Oral commissure elevation Transverse head: Nostril dilation Alar head: Nostril compression</p> <p>Mouth closure and lip pursing Oral commissure lateralization (sec. smile actuator)</p> <p>Upper lip elevation</p>
Buccal/marginal mandibular	<ul style="list-style-type: none"> • Depressor anguli oris 	Oral commissure depression
Marginal mandibular	<ul style="list-style-type: none"> • Depressor labii inferioris • Mentalis 	<p>Lower lip depression</p> <p>Chin elevation (soft tissue)</p>
Cervical	<ul style="list-style-type: none"> • Platysma 	Oral commissure depression

1.1.3 Functions of the facial nerve

CNVII contain approximately ten thousand nerve fibers and there are five types. (8,11)
Below is an overview of the five types of nerve fibers, which could be helpful to understand the complexity of facial nerve function: (8, 9)

1. **General visceral efferents** are part of the autonomic nervous system and provide preganglionic parasympathetic secretomotor function.
 - **Chorda tympani nerve** innervates sublingual and submandibular glands.
 - **Greater superficial petrosal nerves** are responsible for the innervation of lacrimal, nasal and palatine glands.
2. **Special Visceral efferents** control voluntary movements of muscles derived from the second branchial (hyoid) arch.
 - Nerve fibers of stapedius muscle
 - **Posterior auricular nerve** innervates intrinsic ear muscles, posterior auricular muscle, and occipital muscle.
 - **Terminal branches** are responsible for the innervation of stylohyoid muscle, posterior belly of the digastric muscle and the muscle for the facial expression (Table 2).
3. **General somatic afferents** transmit feelings of pain, light, touch, and temperature.
 - **Posterior auricular nerve** innervates external auditory canal.
4. **General visceral afferents** in **greater superficial petrosal nerve** transmit feelings of pain from the visceral structures as part of the autonomic nervous system in the soft palate.
5. **Special visceral afferents** in **chorda tympani** transmit the special sense of taste or gestation in anterior two-thirds of the tongue and **greater superficial petrosal nerve** in the soft palate.

1.2 Etiology and pathophysiology

Facial nerve lesion can be found in the **supranuclear** and **infranuclear system**, which lead to a **central** or a **peripheral** facial palsy. (12)

1.2.1 Central facial palsy

The facial motor nucleus in the brain stem contains motor neurons, which can be separated in a posterior part and an anterior part. Their axons reach their target muscles of the facial expressions through the facial nerve. The posterior part supplies

the muscles of the forehead and eyes (temporal branches), and these motor neurons are innervated by motor neurons in the primary somatomotor cortex (precentral gyrus) also so-called upper motor neurons. Upper motor neurons reach motor neurons of the posterior part with corticonuclear fibers. The posterior part receives bilateral innervation. Therefore, a lesion in the unilateral primary somatomotor cortex will only cause contralateral lower face palsy/weakness (the central facial palsy). The motor neurons of the anterior part receive the innervations from the contralateral cortical motor neurons. The anterior part is responsible for muscles of the lower face. *Newadkar et al.* say that's lesion in the upper neurons can maybe also result in selective facial palsy for either volitional or emotional facial movements. To sum up, the clinical symptoms of the central facial palsy present on the contralateral lower face. The symptoms are sagging of the angulus of the mouth on the contralateral side and the affected speech articulation, but wrinkling at the forehead and closure of the eyes on both sides are still possible. Isolated low face palsy can also appear because of brainstem lesion. In this case, the patient has additionally brainstem signs such as horizontal gaze palsy from sixth nerve involvement. (12)

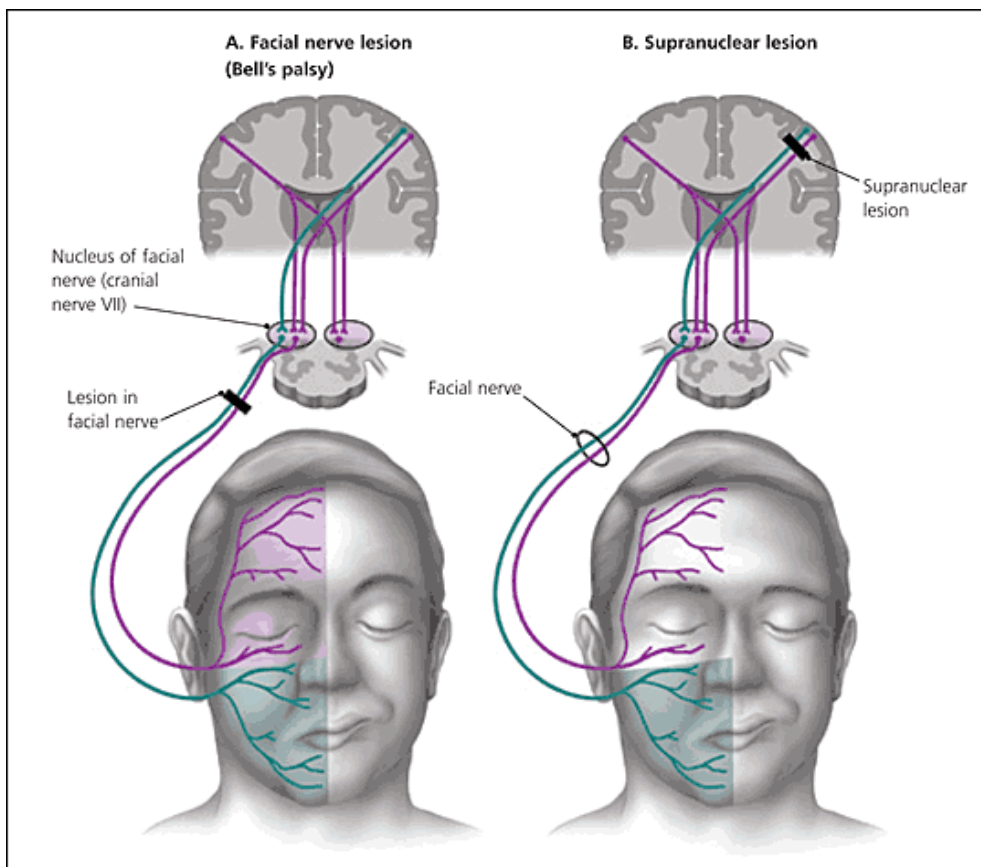


Figure 5: Peripheral facial palsy vs. central facial palsy;(13)

1.2.2 Peripheral facial nerve palsy

As a result of the infranuclear lesions, the main characteristic of the peripheral palsy is the complete paralysis of the ipsilateral muscles of facial expressions. Smooth forehead without wrinkles, sagging of the corner of the mouth, impaired articulation, and the bell phenomenon due to the infranuclear lesions, the main characteristic of the peripheral palsy is the complete paralysis of the ipsilateral muscles of facial expressions. Smooth forehead without wrinkles, sagging of the corner of the mouth, impaired articulation and the bell phenomenon are representative signs. The eyelid closure reflex is often abolished too. There may be more additional deficits like decreased lacrimation and salivation or loss of taste sensation in the anterior 2/3 of the tongue.(8,11,12)

An anatomic lesion anywhere along the length of the facial nerve leads to peripheral facial nerve palsy. Thus, it can also be divided into three major categories based on different locations of the lesions.(8) Table 3-5 should give an overview of the etiology of the facial palsy based on their locations. The most common cause is idiopathic, followed by neoplasm.(1)

The bilateral facial palsy will be left out because it is rarer and would be beyond the scope of this thesis.

Table 3: Intracranial(8)	
Neoplastic	Meningioma Cerebellopontine tumors Bilateral acoustic neuromas in the setting of neurofibromatosis type 2.
Traumatic	Penetrating Shear injury
Infectious	Encephalitis Meningitis Intracerebral abscess
Neurodegenerative	Amyotrophic lateral sclerosis Multiple sclerosis
Vascular	Aneurysm cerebrovascular accident vasculitis intracerebral hemorrhage
Iatrogenic	Tumor extirpation
Congenital	Möbius syndrome Goldenhar syndrome

Table 4: Within the temporal bone (intratemporal) (8)

Neoplastic	Cholesteatoma
Traumatic	Penetrating trauma Temporal bone fracture Longitudinal (80%) Transverse (20%) Because of swelling and compression of the nerve in the facial canal, after a transverse fracture, it is the most common traumatic cause of the facial palsy.
Infectious:	Acute otitis media/ external Mastoiditis Ramsay-Hunt syndrome
Iatrogenic	Tumorextirpation
Systemic	Pregnancy Diabetes mellitus Neurosarcoidosis Hyperthyroidism Amyloidosis Melkersson-Rosenthal syndrome
Toxins	Lead poisoning Carbon monoxide
Idiopathic	Bell's palsy

Table 5: Distal to the temporal bone (extratemporal) (8)

Neoplastic	Parotid tumors
Traumatic	Penetrating trauma
Infectious	Parotitis
Iatrogenic	Tumor extirpation
Obstetrical	Forceps delivery
Congenital	Congenital unilateral lower lip paralysis

1.3 Clinic

Facial palsy describes a condition, which includes non-flaccid facial palsy, flaccid facial palsy, and facial paralysis. Absence or weakness of mimic and facial muscle tone, without synkinesis or hyperactivity can be called as flaccid facial palsy. For instance, losses of static and dynamic symmetry occur to flaccid facial palsy (FFP). The presentation in FFP of paralytic lagophthalmos leads to keratitis. Difficulties in breathing, due to the external nasal valve collapsing, the oral incompetence and articulation impairment are also symptoms of FFP and cause problems in social interactions.(16,17)

The development from partial to complete paralysis of the facial muscle without losing facial sensation is common and fast. Some cases are associated of a sensation of “numbness”. 29 % of the idiopathic facial palsy patients present clinically systemic symptoms (e.g. fever, headache, sore throat, or neck stiffness). Unilateral facial palsy is the most common form. Seldom, there is a presentation on bilateral sides, which are frequently associated with Lyme disease. Additional symptoms including hyperacusis decreased lacrimation or decreased taste due to a lesion of the efferent parasympathetic branches.(18)

Zonal synkinesis and hyperactivity of the facial muscle post paretic can cause by irregular nerve regeneration. This are the main characteristic of non-flaccid facial palsy (NFFP). Depending on the region of dysfunction, neck discomfort, facial fatigue, excessive tearing, and a narrowed palpebral fissure width are the common symptoms. Most devastating condition due to severe NFFP must be the loss of meaningful smile. Facial synkinesis occurs to the regeneration of the special visceral efferents fibers to different mimetic muscles than which they were intended. It leads to involuntary and abnormal facial muscle activation accompanying volitional or spontaneous expression.(8,16,17)

Besides showing emotions and involving in social interactions, there are other essential functions of facial muscles. An obstructed gaze and smooth forehead with the absence of wrinkles occur to the paralyzed frontalis muscle. The orbicularis oculi muscle paralysis leads to ectropion with increased sclera show, which can cause dry eyes and loss of the protect function towards the foreign materials.(2,8)

1.3.1 Diagnosis

Facial palsy is a clinical diagnosis. First, all of the patient's complaints should be documented. Then the static face of the patient should be observed for the symmetry and the presence of the synkinesis. There can be signs of flaccid facial palsy or nonflaccid palsy. There is the directed neurological examination, which evaluates movements of the muscle of the facial expressions. Voluntary movements of muscles for the mimics are supplied by the five main peripheral branches of the CNVII. For checking of the temporal branch, patients have to raise their eyebrows and wrinkle their brow. The zygomatic branch should be checked with the ability to close the eye gently, and also the ability to close them with the maximal effort. The patient should smile, show teeth and puff out of the cheeks. This is the best way to evaluate the innervations of the buccal branch.(15)

Due to the wide spectrum of the etiology of the facial palsy, there are also many differential causes of CNVII palsy. The frequently cause can be identified based on their anamnesis. Two main divisions are congenital and acquired facial palsy. (19,18)

1.3.2 Congenital facial nerve palsy

Melkersson-Rosenthal Syndrome

The clinical triade often includes facial swelling, fissured tongue and recurrent attacks of intermittent facial nerve palsy. The pathology of this disorder based on inheritance. 30% to 50% of the case presents facial palsy and it can become permanent.(18)

Birth trauma

Incidence of facial palsy in association with birth trauma is 0,21%. The predispositions are prolonged labor, a birth weight greater than 3,5kg, and forceps delivery.(18)

Albers-Schönberg Disease

An inherited disease, which leads to gradually increasing bone density, also called as osteopetrosis. Raising of bone density leads to narrowing the foramina of the cranial nerve and impinge the facial nerve. The result is the facial nerve paralysis, and it often can be bilateral form.(18)

Möbius Syndrome

Möbius syndrome is an extreme and also most common example of the bilateral facial nerve paralysis with symmetrically flat facial expressions(2,19). It is also associated with other cranial nerve palsies(18), but the etiology and pathogenesis are still unclear.

Goldenhar Syndrome

Hemifacial macrosomia, facial palsy, malar hypoplasia, and maxillary hypoplasia are the typical presentation of patients with Goldenhar syndrome.

1.3.3 Acquired Facial Nerve Palsy

Infections

Lyme disease

Lyme disease is a common cause in endemic areas of the spirochete *Borrelia burgdorferi* for facial palsy. The palsy often is associated with tick exposure and has clinical presentation of the classic erythema chronicum migrans rash. Systemic symptoms including fatigue, nausea, abdominal pain, arthralgia, and headache can be observed too.(18,20)

Herpes simplex Virus (HSV)

In 79% of the case, endoneurial fluid and saliva of pediatric patients with idiopathic facial nerve palsy with negative Lyme titers are HSV positive. The virus may cause inflammation and demyelization and create facial palsy.(18)

Varicella Zoster Virus (VZV)

Ramsay Hunt postulate in 1970, the auricle and the external auditory canal as location of the facial nerve dermatome, therefore an outbreak of VZV can lead to herpes zoster oticus, also known as Ramsay Hunt syndrome. (12) (21) Reactivation of dormant VZV and the spread of the VZV into the facial nerve, occur commonly facial palsy, extreme ear pain, vesicles around the ear, mouth, face, neck, and scalp. Hearing loss, vertigo,

and tinnitus result from the involvement of vestibulocochlear nerve. Some patients also present taste impairment, xerostomia, and dry eyes.(19)

Guillain-Barre

Bilateral facial palsy is likely a clinical presentation of this acute inflammatory demyelinating polyneuropathy. Since Guillain-Barre affects the peripheral nerves, weakness of breathing muscle, face and the upper and down limbs are the characteristic symptoms. It may occur to campylobacter jejuni infection. Guillain-Barre also causes more likely bilateral facial palsy.(19,21)

Otitis media (OM)

The association of facial palsy with otitis media has not been fully understood, but there are few hypotheses. Usually it starts gradually and is accompanied with clinical symptoms like ear pain and fever. At early stage of OM, a retrograde infection within the facial nerve canal or tympanic cavity ascending the chorda tympani can be present and causes reactivation of latent viral infection. Other theory says, due to the presence of inflammatory bacterial toxins peripheral demyelination of the facial nerve occurs. If in the later stage of OM, the inflammatory process expands into the facial nerve canal (fallopian canal), then it can result in inflammation or compression of the facial nerve. Erosion into the fallopian canal with direct extension of infection because of polyp or a cholesteatoma, is common in chronic OM.(18,20)

1.3.3.1 Traumatic

Injuries to the facial nerve (CNVII) commonly occur to trauma, for instance temporal fractures. It can present in blunt, penetrating, and iatrogenic forms. Contusion and nerve edema, but seldom nerve transections are characteristic injuries of blunt trauma. The main cause of direct nerve transaction is gunshots wounds of the temporal bone. Also during mastoid and middle ear surgeries, the CNVII can be injured in the tympanic segment, where the common site for fallopian canal dehiscence is. Besides otological procedures and tumor extirpation, some literature also reports facial nerve injures due to dental treatments.(11,12)

1.3.4 Idiopathic

A unilateral lower motor neuron weakness of the facial nerve with sudden onset, describe perfectly the clinical presentation of idiopathic facial palsy, also known as

Bell's palsy. It is the most common form of peripheral facial palsy. *Tiemstra JD et al.* believe the occurrence of idiopathic facial palsy has a close correlation with diabetes and pregnancy. Another theory first outlined by McCormick says there is a possible association with a reactivated herpes simplex virus infection centered on the geniculate ganglion.

No specific correlation between the genders has been observed in idiopathic unilateral facial palsy, but there is a lifetime risk of 1 in 60. The population incidence rates range from 11.5 to 40.2/ 100 000. Even though, predilection for a specific age and for either side of the face is unknown, a rise of incidence in the 40s has been shown.

Clinical presentations of Bell's palsy are a unilateral facial muscle flaccidity, ipsilateral platysma weakness, vanishing of the nasolabial fold, drooping of the brow and sagging of the angle of the mouth. $\frac{3}{4}$ of case of Bell palsy presents on the affected side during the eye closure a visible upward rotation of the globe. It is the well-known Bell's phenomenon. Hyperacusis, dysgeusia, ear pain, mastoid pain and symptoms of neck accompany often the aforementioned clinics. Usually the onset of symptoms to the highest peak of weakness is within three days to one week. Often Bell's palsy resolves spontaneously and in 71% the case resolves completely. The outcome depends on the severity of weakness at the presentation. Should there be a gradually onset or no amendment could be observed after two weeks, another diagnosis must be considered rapidly.(22–24)

1.3.5 Neoplasm

Neoplasm is followed Bell's palsy the second most common in facial palsy(1). Typical onset of their symptoms is insidious and very slow. The clinical presentations are progressive over weeks or months, recurrent ipsilateral palsy and progression or no resolving after 6 months. Acoustic neuroma and vestibular schwannoma affect the facial nerve the most, with regard to their origin region (cerebellopontine angle or internal auditory canal the clinical symptoms are tinnitus and hearing loss. In case of the tumor arises from the middle ear, a gradually facial palsy development accompanying with conductive hearing loss can often be seen. It comes rarely to facial dysfunction when the tumor is extratemporal.

The most common tumor of the facial nerve itself is the facial schwannoma. Clinical presentation of facial schwannomas can be like the more common vestibular schwannoma, which often starts with facial spasm before it results in the paralysis.

Patients with neurofibromatosis type 2 often have a bilateral involvement of vestibular schwannoma, which has a negative impact on brain-stem function and results in severe hearing loss, vestibular problems, facial nerve paresis or paralysis. There are various specific treatments for each type of tumor. Therefore, the diagnosis should not be an assumption. Beside last reviewed tumors there is another fairly common cause, which is the malignant parotid neoplasm.(11)

1.4 Management of paralyzed face by zone

To start a treatment, as long as the eye is protected, the mechanism and whether or not the paralysis is reversible or irreversible have to be determined and assessed firstly (see section: *1.5 Assessments and Grading instruments for the facial nerve*). Facial muscles with viable muscle fiber and intact motor units will be determined as reversible facial muscles. Therefore, performing nerve grafts is feasible and can be effective in restoring tone and movement of the facial muscles. The functionality of motor end units can be determined with electroneurography. Nerve grafting cannot be achieved with atrophic and fibrotic musculature at permanent or irreversible paralysis. In this case, static procedures are the best option for restoring resting tone. To restore facial reanimation muscle transposition or free muscle transfer is required in irreversible paralysis. Establishment of the cause of the paralysis eases the determination of the timing of intervention. The possibility of spontaneous recovery will delay reanimation procedures, but if the intervention is the consideration to make the paralysis reversible, procedures are generally performed within a few weeks to months. (25)

1.4.1 Non-surgical treatment

Using chemodenervation with Botulinum A toxin on the healthy side of the face to improve symmetry at rest and on the paralyzed side to reduce synkinesis following recovery from Bell's palsy.(26)

1.4.2 Surgical treatment

Grobbelaar AO et al. (26) prefer to perform the surgical procedure from the age of 4 years, because the child is becoming aware of their disability at that age and neurovascular anastomoses performance becomes more feasible. Balanced resting tone and a dynamic symmetrical smile are the main goals, which should be achieved. There are many static and dynamic procedures or combination of both procedures, which can realize these goals.(26)

1.4.2.1 Brow

Facial palsy causes a range of deficits in facial functions. Diminished brow function and tone can be devastating and make the face of the patients appear unfamiliar, because brow position and symmetry appear to be important components of facial recognition. The condition brow ptosis is defined when the brow rests below the supraorbital rim. The presence of dermatochalasis often leads to superior visual field impairment(27,28). The most common surgical approach is brow lift. There are the direct brow lift, the endoscopic brow lift, coronal brow lift, pretrichial brow lift and indirect brow lift. There is no difference in the longevity of the correction with open or endoscopic techniques neither different approach noted. The decision mainly depends on patient-specific anatomy(27,29). A coronal or a petrichial brow lift is an optimal option for a female with unbalanced facial proportions and a high hairline. Because coronal incision raises the hairline and a petrighial incision excises forehead skin and lowers the hairline. Indirect brow lifting is more suitable for old male patients with progressive balding. Surgeons often prefer direct brow lift because of the optimum control of brow high and it minimizes the complications like a prominent scar and brow alopecia. Endoscopic brow lift causes less alopecia, smaller incisions, and faster recovery. In return, it takes longer, and special training are needed(27). Besides the surgical treatments for a more symmetric look, some patients can be treated by injecting the contralateral frontalis muscle with botulinum toxin. For this treatment, repeated visits every 4 to 6 months are required(28). To plan an adequate treatment, the age and the anatomy of the patient is very important. Young patients should be observed first. They often present a hyperfunction on the contralateral side of the paralyzed side. In this case, the best treatment for this group is a combination of temporary chemo denervation and ipsilateral brow elevation. But not all patients with facial palsy presentations do need a brow lift, mostly the young patients just need be followed(27).

1.4.2.2 Periocular

Upper Eyelid

Denervation of the orbicularis oculi muscle leads to lagophthalmos and causes keratopathy or even blindness. At acute settings the primary **non-surgical treatments** are using eyedrops, lubricating ointment and moisture chambers to minimize exposure and desiccation of the cornea. Additionally using botulinum toxin injections to correct

upper eyelid retraction and generate ptosis provides temporary corneal protection. The purpose of the botulinum toxin is the chemodenervation of the Muller's muscle and the levator palpebrae, which is very useful at reversible facial paralysis(28–30).

Another good temporary solution for patients, who are waiting for the regeneration of the facial functions and are a poor surgical candidate, is applying hyaluronic acid as a weight on the upper eyelid. The procedure is easy and safe in-office administration, and reversible. It has also a low resorption rate due to the diminished motility of the eyelid(29,30).

Lid loading is an effective surgical management, which uses rigid weight to provide gravity-assisted closure.(29) This procedure should be considered as the first-line management and the indications are poor prognosis for rapid recovery, inadequate Bell phenomenon, and absent recovery at 3 months.(31) Gold weights were widely used, but recent studies have shown that the use of thin-profile platinum eyelid weights reduces bulk, decreases the risk of allergic reaction and it has a lower risk of extrusion. Besides reducing the side effects, platinum weights have a better biocompatibility(28,29).

Lower Eyelid

Ectropion and corneal desiccation through loss of lacrimal system function also occur to paralysis of the lower eyelid. The usual treatment is a combination of elevation of the lower eyelid and weighting the upper eyelid to achieve the full eye closure.(28) Management of lateral eyelid ectropion mainly is tightening of the lower eyelid and also known as the lateral tarsal strip procedure. For this procedure, firstly an incision along a horizontal crow's foot line need performed. It goes through the dermis and orbicularis muscle. Secondly canthotomy, cantholysis, and deepithelization of the gray line follows. This procedure allows to tight the lower lid in a desired leng along the gray line. In the end of the performance the lower tarsal plate will be fixed at the lateral orbital rim using a non-absorbable suture. The complications are hemorrhage, lateralization of the lacrimal punctum and recurrent laxity, which can be overcame by placing an autologous fascia lata sling for the lower lid. With the help of a needle, the fascia lata strip is tunneled through the lower lid. It is secured at the nasal bone medially and laterally at the superolateral orbital rim, so that the fascia strip is tensioned. The anchor-positions should be chosen in such a way that the lower lid margin can move up to the position of the lower limbus.(31)

Not only appearing as complication, the laxity of the lower lid is also commonly observed for patients of old age. In this context, methods such as lid shortening and spacer graft can be performed. Medial ectropion correction can be achieved with canthal tendon tightening, the medial spindle procedure, and medial canthal tendon resuspension. Management of medial ectropion can be performed in single procedure or in the case of generalized ectropion together with lateral lid procedures.(32)

1.4.2.3 Midface

Facial paralysis stretches the canthal ligaments and leads to midfacial ptosis, exacerbation of lower eyelid ectropion and nasal stenosis. In this area, static surgical procedures are primarily preferred and often in combination with dynamic procedures to get better result in the facial symmetry. Candidates for static sling procedures are commonly not available for muscle transfer procedures or nerve reconstruction.(29,32) Minimal access cranial suspension(MACS) has been shown as a simple and quick midface elevation procedure, which provides a reduction of the vertical lid height and stable support of the lower eyelid. Another Midfacial elevation technique avoids lower eyelid ectropion by elevating the fat pad of the suborbicularis oculi muscle and periosteum. However, Midface-lift often still needs to be performed to support lower eyelid.(29)

The nasolabial fold effacement and the external nasal valve collapsing occur to flaccid facial palsy can be treated with suspension using 3 strips of fascia lata. A neonasolabial fold can be made first by harvesting 3x3mm squares of temporalis by exposing the temporalis fascia in the anterior temporal area. Then two small incisions, medial to the desired position of the nasolabial fold, follow. One of the segments of the fascia will be threaded onto a 4-0 Prolene suture, which is threaded onto a eleven centimeter Keith needle. This needle will pass through the nasolabial fold incision and come out at the incision at the temporalis. The desired nasolabial fold can be reached by the manipulation of the Prolene with tethering of the subdermis by pulling the pledget, resulting in a pucker. The placement of several Prolene/ fascia units allows linear puckering, or “neonasolabial fold”. After the closure of the temporal incision, the midface incision can just covered with steri stripping.(33) In elderly patients, under local anesthesia nasolabial fold suspension can be achieved by applying multiple 2-0 polypropylene sutures through the dermis and by using a Keith needle (level IV) to pass superficial musculoaponeurotic system (SMAS) subcutaneously to the temporal region. But in static facial suspension this procedure has been suggested to avoid, because of

the higher risk for infection and loss of correction with the time. To avoid those complications, like recurrent laxity, it is may better to perform the suspension with dynamic smile reanimation. (17)

An over-prominent Nasolabial fold from aberrant regeneration (Non-flaccid facial palsy) will be treated by a similar procedure. The difference in this procedure is the incisions are made 1cm laterally to the nasolabial fold instead medially.(33)

Traditionally, the modiolus is suspended from the zygomatic arch or the temporalis fascia using the fascia lata or palmaris tendon. The operation may apply a tension force down to upper and lower lips. A new method in which the palmaris tendon is splitted into three sections has been introduced. The so called “multivectorial approach” provides an improved result regarding the cheek tone and nasolabial fold. The resulted improvement achieved with the aforementioned static methods is still rather limited in comparison with the dynamic reconstruction methods. Furthermore, various allografts can also be the method of the choice in case the autograft is not available.(32)

1.4.2.4 Lower face

The main implication of paralysis in the lower face is the inability to smile. This inability occurs to paralysis in the zygomaticus major muscles and levator labii superioris. Depressor labii is also affected so that the inability to show the lower teeth is also present. Other implications are incompetence of speech, drinking and clear the food bolus in the mouth.(26)

For the patients suffering a long-standing paralysis and with even multiple comorbidities, static reanimation of the lower face is considered as the preferred option. In order to reform the nasolabial fold and to lift the oral commissure and upper lip, a static sling from the deep temporal fascia or zygomatic arch is suspended to the upper lip and oral commissure. In this context, the tensor fascia lata and various allografts for instance Gore-Tex and AlloDerm are frequently used as sling materials. With MACS procedure mentioned above in the management of the midface, can reach the aim too. Beside static procedures, there are various dynamic methods to reanimate the lower part of the face. Primarily the time from paralysis is the determination of the procedure in dynamic reanimation in the lower face. The duration has a huge impact on the treatment considerations and the outcomes. In general, it has been demonstrated that applying primary repair at early stage of the ipsilateral facial nerve leads to the best outcome. Since there are various dynamic reanimation procedures, the following will

give an overview on them. It is generally accepted that in case of facial nerve transaction, direct repair can be performed. In this context, nerve repair is considered to be the best as long as a tension-free coaptation is feasible. The same effect can be achieved by cable graft nerve repair involving the sural nerve or great auricular nerve. However, coaptation on two sides can result in an insufficient functional recovery. Due to the increasing of the complexity of topography as well as higher risk for synkinesis and dyskinesis, manipulation of the facial nerve close to the stylomastoid foramen should be kept from.(29)

If primary or interpositional nerve grafting cannot be performed, nerve transfers should be considered if the duration of paralysis is less than two years and before the occurring of muscle atrophy and fibrosis at the motor end plates. For instance, Cross-Facial Nerve Grafting (CFNG) can return the ability of facial expression by innervating of the paralysed muscles and the corresponding facial nerve using the main peripheral branch of CNVII (cranial nerve VII) of the functioning contralateral side. Due to the unpredictable results of CFNG occur to the risk of axons regeneration due to the long distance and meanwhile continued muscle atrophy with ensued denervation. There is also suggestion to combine CFNG with a “babysitter” procedure after six months denervation. This performance overcomes the disadvantage by using the hypoglossal nerve to avoid muscle atrophy and damage of motor endplates during the growth of the axons by using CFNG.

In case the contralateral facial nerve cannot be used, performance using ipsilateral nerve transfer is common. Most commonly described procedures are using hypoglossal nerves, followed by the masseteric nerve. The hypoglossal-facial nerve coaptation normally means a transection of the hypoglossal nerve. This procedure often causes tongue weakness and problems in speaking and swallowing. There is a modification of this technique, fifty percentage of the fibers of the hypoglossal nerve can be transected, followed by an end to end anastomosis with CNVII. It leads to the similar outcome like the technique above but without the morbidity. Nonspontaneous movements of the face with the most rest symmetry can be best achieved by hypoglossal nerve transfer. But an end-to-end anastomosis using the masseteric nerve and CNVII gain more popularity recently. This nerve is also often used in free muscle transfer. Easy dissection, preservation of mastication function, good donor-recipient nerve size match, and good donor length speak for masseteric nerve transfer. Due to the dissection, the main disadvantage of this procedure is a higher risk to damage the zygomatic and frontal

branch of CNVII. Another reason to consider nerve transfers are extensive cranial nerve deficits.(29)

Dynamic muscle transposition includes regional and free muscle transfers. These performances are chosen when the facial nerve reinnervation is unfeasible. Concerning which of the two transposition techniques will be selected, it depends mainly on the detailed situation of patients.(29)

As a classic performance of regional muscle transfer, the lower face facial reanimation involves transferring the temporalis muscle across the zygomatic arch to the oral commissure. The most concerned drawbacks of this approach include resulted facial asymmetry, depression around temple, chronic temporomandibular joint dysfunction as well as a shortage of orthodromic muscle contraction. These disadvantages are related to the bulkiness induced over the zygomatic arch. To overcome these shortcomings, the temporalis tendon transposition has been developed. In this approach, the detached temporalis tendon from the coronoid process will be subsequently reattached to the oral commissure. It is a relatively easy performance to provide oral commissure elevation. Most importantly, this procedure averts the protuberance of tissue across the zygomatic arch and any degree of depression over the temple. Consequently, it has obtained a very high satisfaction from patients. The incision can be made transbuccal or nasolabial. As far as the incision is concerned, a so called minimally invasive temporalis tendon transfer or MIT3 has been developed. The method is a minimally invasive version of the orthodromic temporalis tendon transfer involving only a single incision (transbuccal or nasolabial). The advantage of this approach is that neither incision nor dissection is necessary at the temple region. In fact, MIT3 has been described as a performance with continuous success and its conjunction with facial rejuvenation procedures has led to an improving patient satisfaction. Masseter transposition is another option used only when the temporalis is unfeasible because of the limited muscle excursion involved and difficulties of masticatory experienced after performance.(29) Additionally, to restore the function of the paralyzed depressor labii inferioris and depressor anguli oris, another regional muscle transposition, which involves digastrics muscle transfers can be proceeded.(29)

An alternative to the aforementioned approaches is the free tissue muscle transfer. However, the free muscle transfer can only be proceeded after CFNG or a performance of ipsilateral nerve transfer. For instance, the free tissue muscle transfer can only be performed when the Tinel's sign is positive in the paralyzed nasolabial fold is positive

first, after the CFNG. For the two stage procedure, pectoralis minor, latissimus dorsi, and the gracilis are used as common flaps. Besides the two-stage, there is also single-stage reconstruction. A direct coaptation between the thoracodorsal nerve of a latissimus dorsal flap and the contralateral face nerve, can be considered as an example of single stage reconstruction.(29)

1.5 Assessments and Grading instruments for the facial nerve

Anatomy or the individual topography of the facial nerve, etiology, age and previous intervention are important factors and have a huge influence on planning the reanimation surgery. A universally accepted grading system to measure the outcome of the surgery or treatments and a suitable system to monitor clinical improvement over time have been emphasized in many papers as a necessity, in order to provide a tailored approach to each individual.(34) Many facial nerve grading systems have been developed and proposed. All of those grading systems and approaches have the same intention to document the CNVII function objectively, to track the process of recovery, and to support the interdisciplinary cooperation and communication. However, one of the limitations at moment is the subjectivity and despite the current technology a perfect scale has not been developed yet. Therefore, the development of an objective facial nerve grading instrument, which is sensitive enough to reflect signs of recovery or changes in function after therapeutic intervention is a goal of research in this field. The following ideal characteristics of a facial nerve grading instrument have been suggested by *AY Fattah et al.*(35)

- Provides regional scoring of facial function.
- Performs static and dynamic measures.
- Examines secondary sequelae of facial palsy (e.g., synkinesis).
- Yields reproducible results with low interobserver and intraobserver variability.
- Sensitive to track changes over time and following interventions.
- Convenient for clinical use.

Since talking about all grading scales or assessments for facial nerve would go beyond the scope of this thesis, only the widely used and accepted one will be introduced. Historically, House introduced the early grading system in 1983. Further, this scale is developed to the widely used House-Brackmann scale (HBS). The Facial Nerve

Disorders Committee of the American Academy of Otolaryngology-Head and Neck Surgery uses HBS as the standard grading assessment for facial nerve recovery. Generally agreed criticisms about this scoring system are subjective nature, high inter-observer variability and it is not sensitive enough to detect clinically significant changes in patient's symptoms after therapeutic interventions.(34,35) Due to the criticisms above, there has been an updated scale, termed the Facial Nerve Grading Scale 2.0 (FNGS II/HBII). Compare to HBS, this FNG II assesses four regions and provide more detailed information. Although the advantages of FNGII, it has the potential for increased subjectivity.(35,36) Another regional weighted system, the Sunnybrook Facial Grading Scale based on the evaluation of facial symmetry at rest, voluntary facial movements, and synkinesis. Compared to HBS the Sunnybrook Facial Grading Scale has been shown to be sensitive to changes following therapeutic intervention. *AY Fattah et al.* says in several studies based high intraobserver and interobserver reliability, the Sunnybrook Facial Grading Scales have demonstrated as a reliable and suitable assessment.(35)

A group at the Massachusetts Eye and Ear Infirmary developed recently a new facial nerve assessment tool, also known as the electronic, clinician graded facial function scale (eFACE) is available across all digital platforms. It is a visual analogue scales with graphic-outputs for each of the 16 features, including five static, seven dynamic, and four synkinesis. Subscores for these three categories and a total score, based on a hundred-point scale will be calculated. *C.A. Banks et al.* demonstrate that eFACE has a high agreement among clinicians, and good intraobserver and interobserver reliability. But they also showed that there are still some disagreements. It is still a subjective scale system and depends on the experience of the clinicians. The lowest reliability has the parameter for the nasolabial fold orientation and platysmal synkinesis. (4)

Besides all subjective scale systems above, there are also many computer graphical analyses. *Frey et al.* proposed 3-D video analysis systems, using optically precise mirrors. This analysis based on tracking facial markers and quantifies their displacement. This system has been shown to be suitable for children and adults(34,37).

1998 Yaoyao Cui et al. stated, that with optical flow method facial expression motion and paralysis can be quantitatively, and reliably assessed. This method based on the estimation of flow velocity at high-intensity gradient points using a genetic algorithm (GAOF). Facial motions from the dynamic image sequences will be detected by using

the method above. In their sample, they used 25 image sequences of 5 subjects and recorded the movement at a speed of 30 frames per second at maximal. The result of their experiment demonstrates an objective and quantitative assessment of progression and recovery of patients are feasible by using the optical flow method combined with other diagnostic methods.(38) *H. Minamitani et al.* demonstrated in their study, using optical flow method to provide the degree of precise movement on the whole facial area. They adapted the assessment to Yanagihara's forty-point grading scale. Besides the advantages, they stated that the inability to analyze the degree of symmetry of the face in rest and calculation requires more time than other computerized methods needed to be solved.(39) *Matthew Shreve et al.* used optical flow method and explored several tracking methods. They have concluded the Black flow leads to the most consistent and reliable results. With these optical flow fields, they quantized the non-rigid deformation on the face into strain maps, and the strain maps can be used to highlight the asymmetries between each side of the face. (40)

Since optical flow method has been showing to be a very promising to assess quantitatively and objectively the facial motions. This thesis proposes the idea to proof the ability and the limitation of the optical flow method and the hypothesis about the correlation between the mathematical analysis and the function of the facial muscles, with implementation to the most used and conventional scoring system in the clinics.

2 Method

Optical flow is the pattern of apparent motion of objects in a visual scene caused by the relative motion between an observer and a scene.(41) In this case, to compute the optical flow the method of Werlberger et al. would be applicable.(42) The principles of this algorithm were discussed extensively with Gottfried Munda (PhD student of Prof. Pock at University of Technology Graz) during the course of this thesis.

The flow is a vector field and stands in this case for a given set of points in an image. The motion can be described by a vector field that transforms from one frame in a sequence into the next frame.(43,44) Therefore length of the flow vector gives information about the speed of the movement. The direction of the flow vector is equivalent to the direction of the movement. The flow magnitude is defined as the sum of the length of all vectors in a selected area in a frame and is associated with the total motion. The mean of the flow magnitude is the flow magnitude of the selected area

divided by the corresponding number of pixels and thus describes the total motion in the specific area of a certain frame (=at specific moment in time). This variable is defined as the instantaneous total flow in this thesis. Calculating of the mean should avoid having a disproportion of the amount of vectors in comparing areas.

The instantaneous total flow over all frames reflects the way covered by the facial muscle at the performance and can thus be interpreted as the potential of the facial muscles in the corresponding area. In this thesis it is defined as the mean total flow (I).

The asymmetry of the facial expressions of the symmetric areas on the left and right side of the face can be described quantitatively by following *Formula 1*. For facial palsy patient, the right and left side would be replaced by the healthy and symmetrical paralyzed side of the face. In following, the outcome will be termed as the *flow asymmetry (D)* in this thesis.

$$D = 2 \times \frac{I_r - I_l}{I_r + I_l}$$

D... *The flow asymmetry*

I_r... *The mean total flow on the right side/ healthy side*

I_l... *The mean total flow on the left side/paralyzed side*

Formula 1: Calculation for the Flow Asymmetry

For the visualization of the movements, Middlebury color code can be used. (44) The saturation can be associated with variations in the magnitude and the direction of the movement is mapped by different color code (see *Figure 7*). (45)

In order to verify the proposed method, the experiment would be carried out in following steps presented in *Figure 6*. This suggested process could non-invasively provide precise information of the muscle activity. The participants would simply have to perform the facial movements under consideration include raising the eyebrows, wrinkling the eyebrows, closing the eyes gently, closing the eyes with a maximal effort, wrinkling the nose, smiling, showing teeth, whistling and puff out of the cheeks. These are all the facial expressions, which are controlled by facial nerve and also have been applied to other grading systems as orientation. After recording, the videos would be converted into separate frames. The intervals with the motions are then selected by identifying the start and the end frame of the movement (CAVE: The end of the performance does not

mean back to the original position). By using open source image manipulation program GIMP 2.8.22, a binary mask would be created individually for the part of interest of the face. Mostly the first or the last frame of the movement should be used to create the mask of interest. The following *Table 6* shows the possible borders of different masks of interest. The masks would be divided symmetrically into a left and right side. The flow of all successive frames would be computed and followed by calculating the sum of the length of the flow vectors, also known as the flow magnitude of the both side of masks. The mean of the flow magnitude describes the total motion in the left/ right side of the mask of interest at specific moment in time, which is also defined as the instantaneous total flow. Subsequently the mean total flow will be computed. With *Formula 1* the asymmetric of the motions of the face can be quantitatively measured using the *flow asymmetry*.

Finally, not only the correlations between the mean total flow and the potential of the facial muscle, but also the correlation between the instantaneous total flow and the frames (=time) could be illustrated with mathematical analysis and curves.

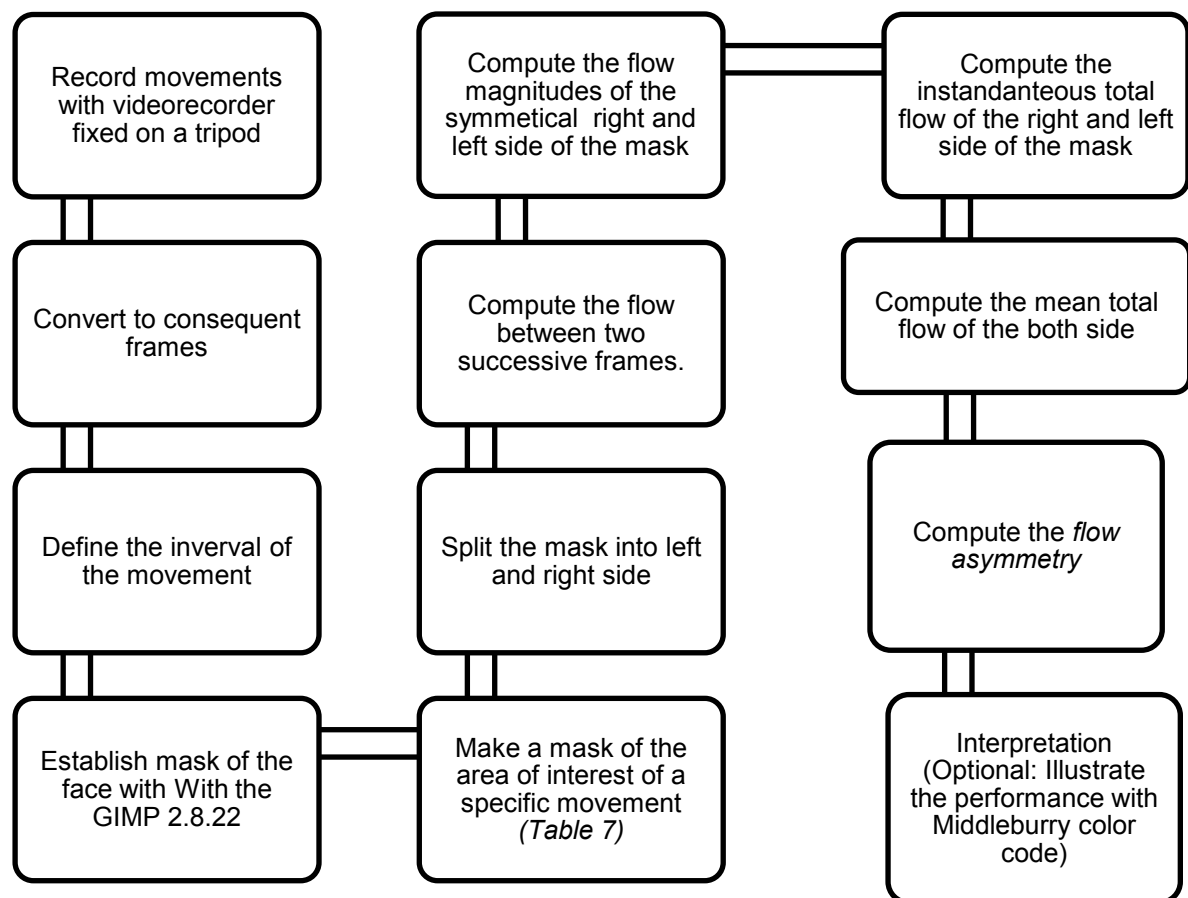


Figure 6: The steps of the proposed experiment procedure

Table 6: Possible borders of mask of interest

Mask of interest	Borders
Forehead-raising eyebrow	<ul style="list-style-type: none"> • Cranial border: deepest point of the hairline of the frontal face • Caudal border: the cranial border of both eyebrows. • Lateral border: a vertical line parallel to the contour of the forehead.
Wrinkling the eyebrows	<ul style="list-style-type: none"> • Cranial border: glabella • Caudal border: nasal root • Lateral border: the medial ends of both eyebrows.
Closing eyes gently	<ul style="list-style-type: none"> • Orbital cavity
Closing eyes with maximum effort	<ul style="list-style-type: none"> • Orbital cavity
Wrinkling the nose	<ul style="list-style-type: none"> • Cranial border: a horizontal line through the lowest point of both orbital cavities. • Caudal border: a horizontal line through the highest point of the upper lip. • Lateral border: a vertical line parallel to the contour of the midface.
Smiling	<ul style="list-style-type: none"> • Lateral border: a vertical line through right and left angulus oris-position at the end of smiling. • Cranial border: a horizontal line through the highest point of the upper lip during smiling. • Caudal border: a horizontal line through the lowest point of the lower lip during smiling.
Showing the teeth	<ul style="list-style-type: none"> • Lateral border: a vertical line through right and left angulus oris-position at the end of showing the teeth. • Cranial border: a horizontal line through the

	<p>highest point of the upper lip during showing the teeth.</p> <ul style="list-style-type: none"> • Caudal border: a horizontal line through the lowest point of the lower lip during showing the teeth.
Kiss/Whistling	<ul style="list-style-type: none"> • Lateral borders: a vertical line through the right and the left angulus oris at rest. • Cranial border: a horizontal line through the highest point of the upper lip during the whistling. • Caudal border: a horizontal line through the lowest point of the lowest point during the whistle.
Puff out of the cheeks	<ul style="list-style-type: none"> • Cranial border: a horizontal line through the lowest point of the lower lid • Border: the contour of the midface and the lower face.

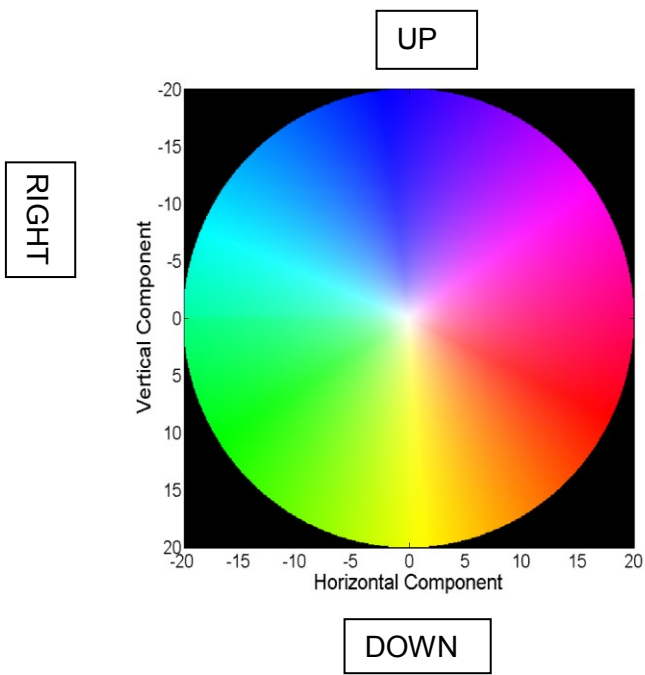


Figure 7: Middleburycolor Code explanation

The legend for optical visualization shows how direction is mapped to color and magnitude is mapped to saturation.

(45)

3 Results

The Function of the optical flow is to identify and recognize movements. Using the optical flow method to describe the course of movements would be feasible. As can be seen from *Table 7*, there are correlations between mathematical analysis and the function of the facial muscles. With calculating the flow magnitude, the velocity of the movement in the selected area at a certain frame can be ascertained. The flow magnitude is dimensionless, so it cannot be equated with the velocity of the physical unit, but the assertion. The time can also be calculated when the frame frequency of the recording is known.

The course of the curve, which describes the correlation between the instantaneous Total Flow and the frames, would show the performance from the start until the end of the movement (CAVE: The end of the performance does not mean back to the original position). The expected course of the curve, which describes the movement on the healthy side, would start with steep gradient until the maximum velocity of the movement has been reached. After the peak, a continually reducing of the gradient would be expected. There may be some lone lower peaks of the velocity during the performance. Those lone lower peaks can be seen as all the attempts, of the specific muscles, of reaching the maximum velocity and staying at the end position of the performance. The course of the curve would show significant rises in velocity at the beginning of the movement until they reached the maximum velocity peak, which can be associated with the maximum strength of the muscles. Decreasing of the gradient after the peak can be associated with slow limitation of the muscle strength. So that the tendency to zero at the flow magnitude means they reached the end of the movement or the state of the maximal contractility of the responsible muscles. The curve of a paralyzed side of the face would be flatter and the highest velocity peak is expected to be much lower than the one of the healthy side. The steepness of the gradient at the beginning of the performance depends on the potential of the specific muscle. Therefore, there could be a correlation between the flatness or the steepness of the curve and the degree of the facial muscle weakness due to the palsy. As already mentioned, the area under the curve represents the strength and the potential of the specific muscle for the movement. The mean total flow can be deduced by calculating the area under the curve mathematically. The difference between the mean total flow on

the left and right side (or healthy and paralyzed side) of the area of interest is here introduced for the first time as *flow asymmetry*.

It is worth to point out that both the mean total flow and the flow asymmetry are important measures for the quantitative grading of the facial palsy.

The mean total flow represents the potential of the facial muscles and the distance covered by the facial muscles movement.

The flow asymmetry illustrates the degree of the unilateral facial palsy.

Table 7: Overview of correlations

Mathematic	Terms	Interpretation
The length of the flow vector	Speed	Speed of the movement of one specific point
Frames per second (fps)	Frames	Time
Sum of the length of the flow vectors	The Flow Magnitude	Total motion
The mean of the flow magnitude at one frame	The instantaneous total flow	The way covered by the muscles/ Performance of the muscle at one certain frame or at specific moment in time
The mean of the flow magnitude over all frames	The mean total flow	The way covered by the muscles during the whole performance. The potential of the muscles
Difference between the mean of flow magnitude over all frames	The flow asymmetry	The degree of the facial expression asymmetry

3.1 Simulated Performance-Curves

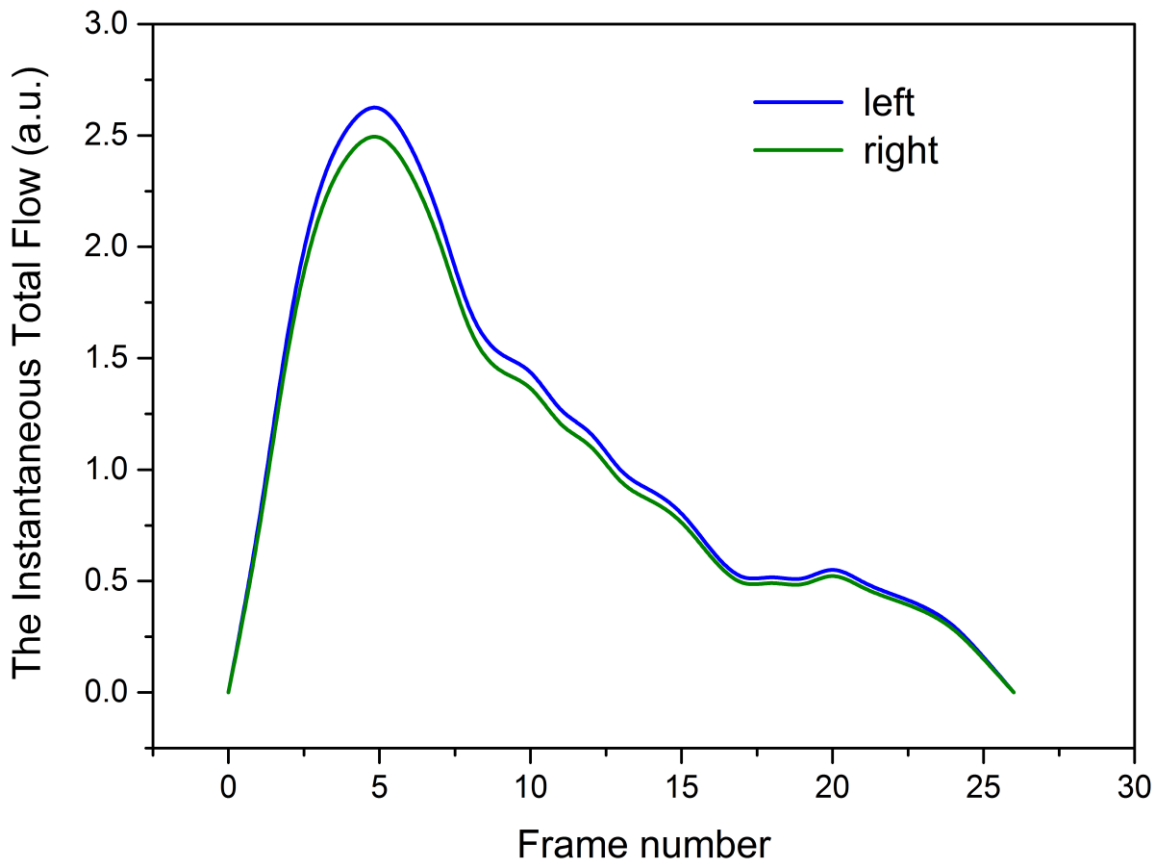
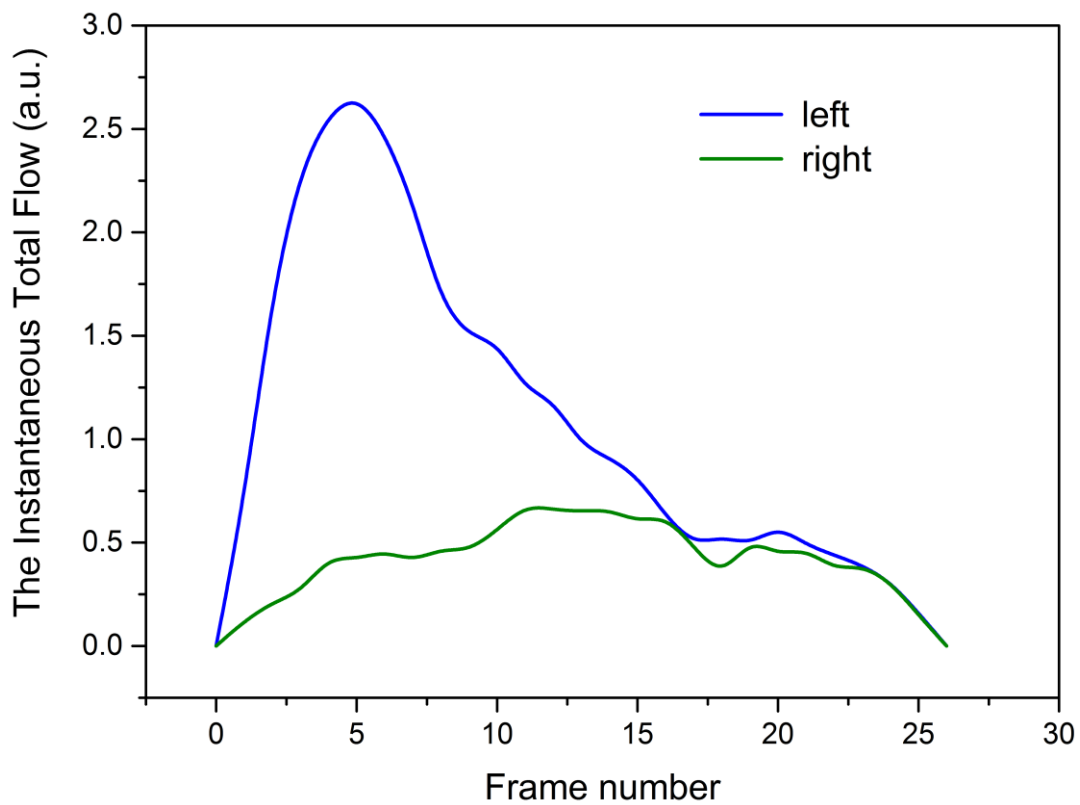


Figure 8: Simulated Performance-Curve of a non-facial palsy face



42 Figure 9: Simulated Performance-Curve of a facial palsy on the right side of the face

3.2 Simulated illustration of Correlation between the mean total flow and the flow asymmetry (D)

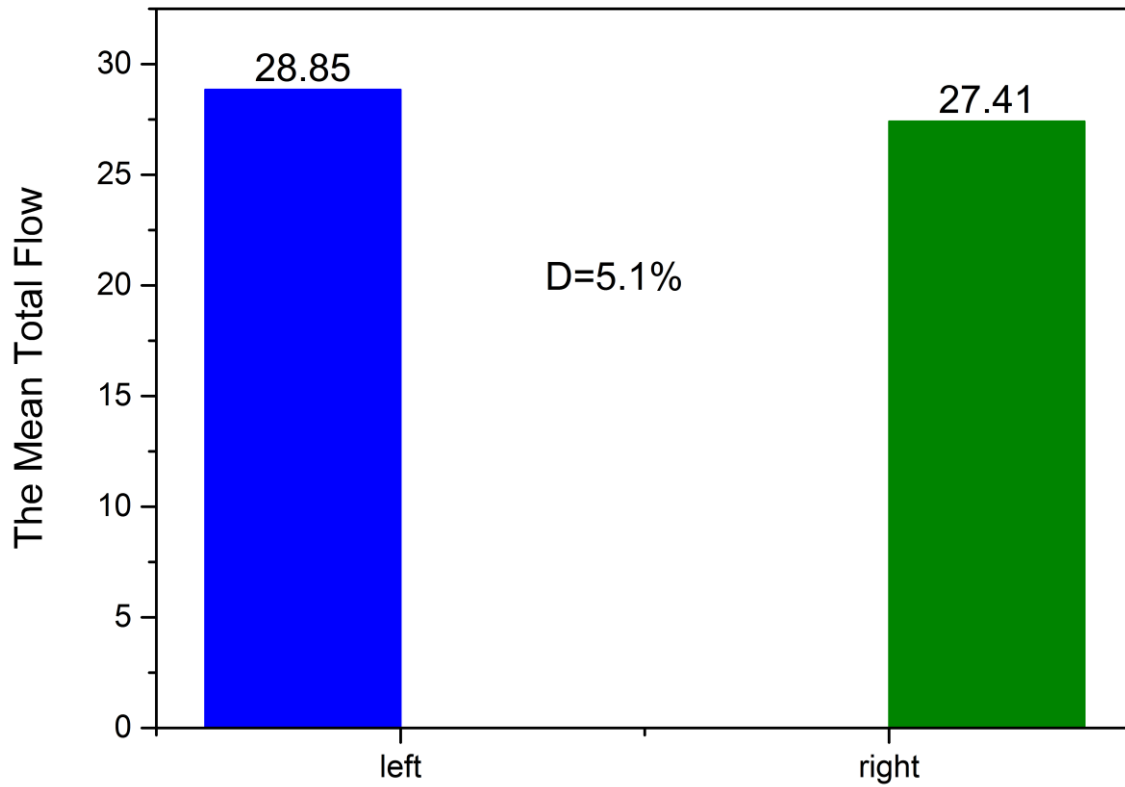


Figure 10: Simulated bar of the mean total flow with the flow asymmetry (D) of the performance in Figure 8

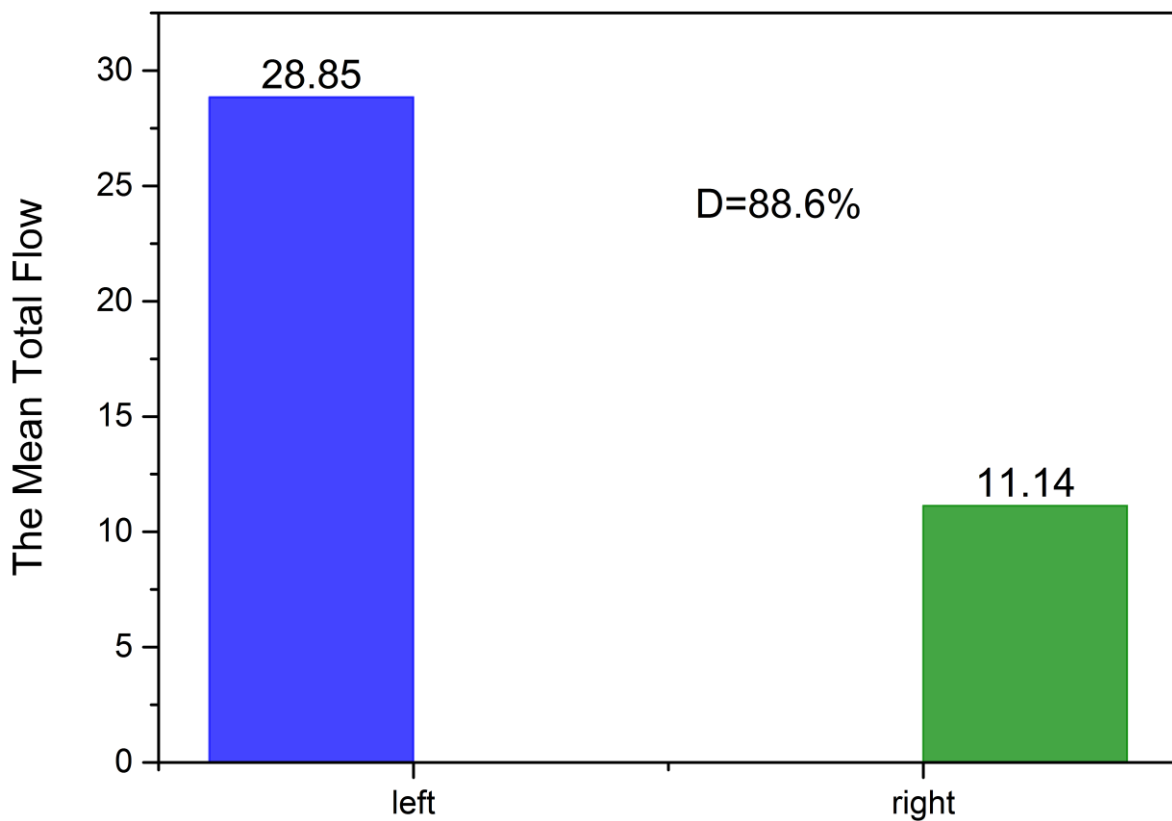


Figure 11: Simulated bar of the mean total flow with the flow asymmetry (D) of the performance in Figure 9

The instantaneous total flows of left and right eyebrows of a healthy face during the rising have been simulated and the results are plotted in *Figure 8* as a function of frame number. For a healthy face, the movement is rather symmetric and only a small discrepancy between the right and left eyebrows can be realized. The corresponding mean total flows for left and right eyebrows calculated from *Figure 8* are presented in *Figure 10*. The very similar the mean total flow indicates the potentials of movement of both eyebrows are very close. This fact can be realized quantitatively by calculating the *flow asymmetry D*, which is 5.1% in this case.

In *Figure 9*, the instantaneous total flow obtained from a simulation for a face with facial palsy on the right side is plotted as a function of frame number. The performance of the left eyebrow is same as the healthy face, whereas the right one deviates in the following aspects:

- (1) The maximum of the instantaneous total flow is much smaller in comparison with the left side.
- (2) The maximum appears with a much large delay.
- (3) The slope leading to the maximum is much smaller.
- (4) The area under the curve is much smaller.

All these observations reflect the limited potential for movement. Performing the integration of these two curves, the mean total flows of them are obtained and are plotted in *Figure11*. A dramatically different of the mean total flow has been observed from the right side of the face. Its small value can be directly attributed to the limited capability of the movement. This fact becomes quantified by calculating the *flow asymmetry D*. Taking the left (the healthy) side as the reference, the *flow asymmetry D* of 88.6% indicates a serious facial nerve palsy.

4 Discussion

Many authors have been suggesting for a universal and automated facial nerve grading system and they are convinced that would help to improve the facial palsy management. This main aim of this thesis is to propose the implementation of the optical flow method as an objective and quantitative measurement for the facial palsy. The potential of correlations between the mathematical quantity and the degree of the facial palsy could be perceived and be fully used. In this case, nine facial expressions

have been observed, which also have been assessed in facial nerve grading system HBS, Sunnybrook, and eFACE. Since only dynamic asymmetry can be identified and be measured by using the optical flow method, a method to measure the static asymmetry is necessary. For instance, the orientation and the deepness of the nasolabial folds cannot be defined with the optical flow. However, to overcome the disadvantage of the optical flow method, the measurement could be combined with measurement for static face, like the Facial Assessment by Computer Evaluation (FACE) software. (46)

But as a follow-up tool for a procedure like dynamic facial reanimation, the optical flow could be used as a reliable objective and quantitative assessment tool. The tendency to the natural symmetry/ asymmetry after therapy can be more objectively and precisely followed with the optical flow than with any subjective grading system.

It is well known, that a certain degree of asymmetry of the human face is a natural given and is physiological. With this powerful method, the natural range of asymmetry degree could be investigated. This range can be used as a guideline and orientation for facial palsy treatment. Since asymmetric is a natural given, an achievement of a total 1:1 symmetric should not be expected after treatments. Different advantages of treatments and the recovering process can be evidently described by using this range. This investigated range and the optical flow has the potential to be used as a universal, automated facial palsy grading system.

5 Conclusion

The *flow asymmetry* is the key-variable introduced in the first time in this thesis as a quantitative measure of the degree of the unilateral facial palsy. Its powerful function has been demonstrated successfully in this thesis using simulated results. The *flow asymmetry* presents the asymmetry in an objective and quantitative way. Based on the optical flow measurement and the subsequent computation proposed in this thesis, important parameters including, the speed and the potential of the movement of the specific muscles can be investigated easily and non-invasively. The *flow asymmetry* D calculated from these measured parameters can be presented in percentages, which

describe the discrepancy between the healthy and the paralyzed side of a face precisely. A *flow asymmetry* of 0% is associated with a perfectly symmetrical facial expression, whereas a *flow asymmetry* of 100% means a seriously unilateral paralyzed side with no capability of movement at all. Since certain degree of asymmetry of the human face is a natural given and is physiological, a perfectly symmetric face with $D = 0\%$ should not be expected. Therefore an investigation about a physiological range of *flow asymmetry* can also be very useful.

An implementation of an objective guideline in other facial reconstruction field could use those investigated variables too.

6 References

1. Kim L, Byrne PJ. Controversies in Contemporary Facial Reanimation. 2016; Available from: <http://www.facialplastic.theclinics.com>
2. Garcia RM, Hadlock T a., Klebuc MJ, Simpson RL, Zenn MR, Marcus JR. Garcia, R. M., Hadlock, T. a., Klebuc, M. J., Simpson, R. L., Zenn, M. R., & Marcus, J. R. (2015). Contemporary Solutions for the Treatment of Facial Nerve Paralysis. *Plastic and Reconstructive Surgery*, 135(6), 1025e–1046e. <http://doi.org/10.1097/PRS.0000>. *Plast Reconstr Surg* [Internet]. 2015;135(6):1025e–1046e. Available from: <http://content.wkhealth.com/linkback/openurl?sid=WKPTLP:landingpage&an=00006534-201506000-00033>
3. Hadlock T. Facial Paralysis: Research and Future Directions.
4. Banks CA, Jowett N, Azizzadeh B, Beurskens C, Bhama P, Borschel G, et al. Worldwide Testing of the eFACE Facial Nerve Clinician-Graded Scale. *Plast Reconstr Surg* [Internet]. 2017;139(2):491e–498e. Available from: <http://www.ncbi.nlm.nih.gov/pubmed/28121888>
5. Piotraschke M, Blanz V. Automated 3D Face Reconstruction from Multiple Images Using Quality Measures. 2016 IEEE Conf Comput Vis Pattern Recognit [Internet]. 2016;3418–27. Available from: <http://ieeexplore.ieee.org/document/7780741/>
6. Takushima A, Harii K, Okazaki M, Ohura N, Asato H. Availability of Latissimus Dorsi Minigraft in Smile Reconstruction for Incomplete Facial Paralysis: Quantitative Assessment Based on the Optical Flow Method. *Plast Reconstr Surg*. 2009;
7. Kim C, Lelli GJ. Current considerations in the management of facial nerve palsy.
8. Brown DL, Borschel GH, Levi B. Facial Paralysis-Michigan Manual of Plastic Surgery. In: Brown DL, Borschel GH, Levi B, editors. *Michigan Manual of Plastic Surgery*. second. Wolters Kluwer; 2014.
9. Kahle W, Frotscher M. Cranial Nerve (V,VII-XII) Human Anatomy volume 3 : Nervous System and Sensory Organs. In: *Human Anatomy volume 3 : Nervous System and Sensory Organs*. 7th ed. Thieme; 2015.
10. Daroff RB, Jankovic J, Mazziotta JC, Pomeroy SL. Cranial neuropathies. In: Jankovic J, Mazziotta JC, Pomeroy SL, editors. *Bradley's Neurology in Clinical Practice*. 7th ed. Elsevier; 2016. p. 2008.

11. Melvin TAN, Limb CJ. Overview of facial paralysis: Current concepts. *Facial Plastic Surgery*. 2008.
12. Newadkar U, Chaudhari L, Khalekar Y. Facial Palsy, a Disorder Belonging to Influential Neurological Dynasty: Review of Literature. *North Am J Med Sci*. 2016;
13. <http://www.aafp.org/afp/2007/1001/p997.html>. [image] Available at: <http://www.aafp.org/afp/2007/1001/p997.html> [Accessed 21 Sep. 2017].
14. Schuenke M, Schulte E, Schumacher U, MacPherson B, Stefan C. Cranial Nerves: Facial (CN VII), Nuclei and Distribution. In: Schuenke M, Schulte E, Schumacher U, MacPherson B, Stefan C, editors. *Head, Neck, and Neuroanatomy (THIEME Atlas of Anatomy)*. 2nd ed. THIEME; 2016. p. 600.
15. Brackmann DE, Fetterman BL. Cranial Nerve VII: Facial Nerve. In: Goetz CG, editor. *Textbook of clinical neurology*. 3rd ed. Saunders Elsevier; 2007. p. 1392.
16. Jowett N, Hadlock TA. A Contemporary Approach to Facial Reanimation.
17. Jowett N, Hadlock TA. An Evidence-Based Approach to Facial Reanimation. *Facial Plast Surg Clin North Am*. 2015;23(3):313–34.
18. Lorch M, Teach SJ. Facial Nerve Palsy Etiology and Approach to Diagnosis and Treatment.
19. Rosson GD, Redett RJ. Facial palsy: Anatomy, etiology, grading, and surgical treatment. *Journal of Reconstructive Microsurgery*. 2008.
20. Glass GE, Tzafetta K. Bell's palsy: A summary of current evidence and referral algorithm. *Fam Pract*. 2014;
21. Roob G, Fazekas F, Hartung H-P. Peripheral Facial Palsy: Etiology, Diagnosis and Treatment. *Eur Neurol [Internet]*. 1999;41:3–9. Available from: www.karger.com
22. Eviston TJ, Croxson GR, Kennedy PGE, Hadlock T, Krishnan A V, Krishnan A. Bell's palsy: aetiology, clinical features and multidisciplinary care.
23. Tiemstra JD, Khatkhate N. Bell's palsy: Diagnosis and management. *American Family Physician*. 2007.
24. Mccauley JA, Cascarini L, Godden D, Coombes D, Brennan PA, Kerawala CJ. Evidence based management of Bell's palsy. *Br J Oral Maxillofac Surg [Internet]*. 2014;52:387–91. Available from: www.sciencedirect.com
25. Harris BN, Tollefson TT. Facial reanimation. *Curr Opin Otolaryngol Head Neck Surg*. 2015;
26. Ghali S, MacQuillan A, Grobbelaar AO. Reanimation of the middle and lower face

- in facial paralysis: Review of the literature and personal approach. *Journal of Plastic, Reconstructive and Aesthetic Surgery*. 2011.
27. Meltzer NE, Byrne PJ. Management of the Brow in Facial Paralysis.
 28. Bhama PK, Hadlock TA. Contemporary facial reanimation. *Facial Plast Surg*. 2014;
 29. Chan JYK, Byrne PJ. Management of facial paralysis in the 21st century. *Facial Plast Surg*. 2011;
 30. Vásquez LM, Medel R. Lagophthalmos after facial palsy: Current therapeutic options. *Ophthalmic Research*. 2014.
 31. Jowett N, Hadlock TA. A Contemporary Approach to Facial Reanimation.
 32. Guntinas-Lichius O, Genther DJ, Byrne PJ. Facial Reconstruction and Rehabilitation. *Adv Otorhinolaryngol*. 2016;
 33. Hadlock TA, Greenfield LJ, Wernick-Robinson M, Cheney ML. Multimodality approach to management of the paralyzed face. *Laryngoscope*. 2006;116(8):1385–9.
 34. Niziol R, Henry FP, Leckenby JI, Grobbelaar AO. Is there an ideal outcome scoring system for facial reanimation surgery? A review of current methods and suggestions for future publications. *Journal of Plastic, Reconstructive and Aesthetic Surgery*. 2015.
 35. Facial Nerve Grading Instruments: Systematic Review of the Literature and Suggestion for Uniformity.
 36. Lee LN, Susarla SM, Hohman MH, Henstrom DK, Cheney ML, Hadlock TA. A Comparison of Facial Nerve Grading Systems.
 37. Frey M, John Tzou C-H, Michaelidou M, Pona I, Hold A, Placheta E, et al. 3D Video Analysis of Facial Movements. 2011;
 38. Cui Y, Wan M, Li J. A NEW QUANTITATIVE ASSESSMENT METHOD OF FACIAL PARALYSIS BASED ON MOTION ESTIMATION. *Eng Med Biol Soc*. 1998;20(3).
 39. Minamitani ' H, Hoshino ' Y, Hashimoto ' H. Computerized Diagnosis of Facial Nerve Palsy Based on Optical Flow Analysis of Facial Expressions.
 40. Shreve M, Jain N, Goldgof D, Sarkar S, Kropatsch W, John Tzou C-H, et al. Evaluation of Facial Reconstructive Surgery on Patients with Facial Palsy using Optical Strain.
 41. OpenCV: Optical Flow [Internet]. [cited 2017 Sep 26]. Available from:

- http://docs.opencv.org/3.2.0/d7/d8b/tutorial_py_lucas_kanade.html
42. Werlberger M, Trobin W, Pock T, Wedel A, Cremers D, Bischof H. Anisotropic Huber-L Optical Flow. [cited 2017 Nov 9]; Available from: <http://www.bmva.org/bmvc/2009/Papers/Paper260/Paper260.pdf>
 43. Stavens D. The OpenCV Library: Computing Optical Flow. 2004 [cited 2017 Sep 26]; Available from: [http://robots.stanford.edu/cs223b05/notes/CS 223-B T1 stavens_opencv_optical_flow.pdf](http://robots.stanford.edu/cs223b05/notes/CS_223-B_T1_stavens_opencv_optical_flow.pdf)
 44. Baker S, Scharstein D, Lewis J, Roth S, Black M, Szeliski R. Optical Flow. Middlebury [Internet]. 2011; Available from: <http://vision.middlebury.edu/flow/>
 45. A Toolbox to Visualize Dense Image Correspondences | Heidelberg Collaboratory for Image Processing (HCI) [Internet]. [cited 2017 Oct 1]. Available from: https://hci.iwr.uni-heidelberg.de/Correspondence_Visualization
 46. Hadlock TA, Urban LS. ONLINE FIRST Toward a Universal, Automated Facial Measurement Tool in Facial Reanimation. Arch Facial Plast Surg. 2012;14(410).
 47. Muscles of Facial Expression [Internet]. [cited 2017 Sep 28]. Available from: <http://www.musclesused.com/muscles-facial-expression/>